


DATE PRESENTING CLINICAL SIGNS

4/21/26 **Patient History:** Owner wants to have dental done, elevated ALT 180. History of feline herpes virus.

PATIENT

Scully Evans

Current Medications: ENISYL PUMP 100ML BOTTLE 3/24/2026, TOBRAMYCIN OPHTHALMIC SOL 0.3% 5MLS 3/24/2026, Royal Canin Selected Protein PR Dry for Cats 8.8lb bag 1 bag 3/3/2026, Purina Pro Plan Veterinary Supplements FortiFlora Cat Synbiotic Action FortiFlora® Cat Synbiotic Action 30 count box 2/24/2026, GABAPENTIN 50MG FLAVOR TABS 7/11/2025.

Labwork Results: Labwork attached.

SPECIES

Feline

Date of Previous IntraPet Ultrasound: No previous.

Sedation: Torb required to complete full diagnostic ultrasound.

Stat Report: Not requested.

Imaging Performed by: Andi Parkinson RDMS

BREED

DSH

ULTRASONOGRAPHIC EXAMINATION OF THE ABDOMEN
SEX

Spayed Female

Urinary System

Urinary bladder is adequately distended. It has a normal uniform wall thickness. Contents include primarily anechoic fluid with occasional echogenic non-shadowing debris, most consistent with incidental suspended lipid in a cat, possibly combined with exfoliated cells, mucous and/or small blood clots. Both sterile inflammation as well as urinary tract infection can also present with echogenic debris. No masses or definitive cystoliths are observed. The trigone and visible pelvic urethra are normal in thickness with a smooth mucosal surface.

AGE

5/6/18

Kidneys are overall normal in size and shape with smooth peripheral margination. A normal 1:3 cortex to medulla ratio is maintained. The medulla and cortices are uniform in texture with some mild increased cortical echogenicity and mild loss of corticomedullary distinction, expected in this age patient. There is no evidence of pyelectasia, mineral or infarcts observed. Left kidney measures 4.5 cm. Right kidney measures 4.7 cm.

WEIGHT

15.13 lbs

INTERPRETED BY

Beth Johnson, DVM
DACVIM

Adrenal Glands
HOSPITAL NAME

Everhart Veterinary
Hospital Cross Keys

The right adrenal gland is normal in size (0.38 cm), shape and overall architecture, echogenicity and echotexture. Visible surrounding vasculature appears normal.

The left adrenal gland is normal in size (0.50 cm), shape and overall architecture, echogenicity and echotexture. Visible surrounding vasculature appears normal.

REFERRING VET

Dr. Notarangelo

Spleen

The spleen is subjectively normal in size with a normal smooth capsular contour. Parenchyma is appropriately finely textured and homogenous with normal echogenicity relative to surrounding tissue (hyperechoic to liver). No focal nodules or masses are observed. Splenic vasculature appears normal.

INVOICE

74668

Liver

The liver is subjectively normal in size with normal smooth curvilinear peripheral contour. Parenchyma is appropriately hypoechoic to the spleen in echogenicity and appropriately mildly coarse and homogenous in

echotexture. No focal lesions are observed. Visible vasculature and biliary tree appear normal without distension or congestion.

The gallbladder is non-distended in size. The wall is smooth without visible thickening. Luminal contents are primarily anechoic. There is no evidence of cystic or common bile duct dilation.

Gastrointestinal

The visible stomach wall is normal in thickness and layering. The lumen of the stomach is empty with no evidence of obstruction, foreign material or infiltrative disease. Pyloric outflow tract appears patent.

The visible small intestine demonstrates areas of mildly thick muscularis layer relative to mucosa (disruption of the normal 1:3 muscularis:mucosa ratio). Small intestinal submucosa is slightly irregular, thick and hyperechoic, without evident loss of layering appreciated. The lumen of the small intestine is empty with no evidence of obstruction or foreign material.

The visible colon is normal in wall thickness (< 0.2 cm) and layering. Contents are consistent with normal formed feces and gas.

Pancreas

The pancreas that is observed appears appropriately isoechoic to surrounding omental fat. Visible capsule is smooth and normal in contour. Visible pancreatic parenchyma is homogenous and unremarkable. There is no visible pancreatic duct dilation. There is no evidence of active peripancreatic inflammation.

Free Abdomen

There is no visible free peritoneal effusion noted in these images.

There is no apparent pathologic lymphadenopathy noted in these images.

PRIMARY FINDINGS

- Very mild/subtle, possibly emerging inflammatory bowel disease (IBD) pattern – Thick muscularis has been reported with infiltrative bowel disease including both benign inflammatory disease as well as infiltrative neoplasia such as lymphoma. No loss of layering or distinct characteristics of malignancy are present. Therefore, differentials cannot be further ranked without tissue sampling.
**This finding could be in part normal patient variant.*

SECONDARY FINDINGS

- Mild age related kidney changes.
- Mild amount of echogenic urinary bladder debris.

INTERPRETATION OF THE FINDINGS & FURTHER RECOMMENDATIONS

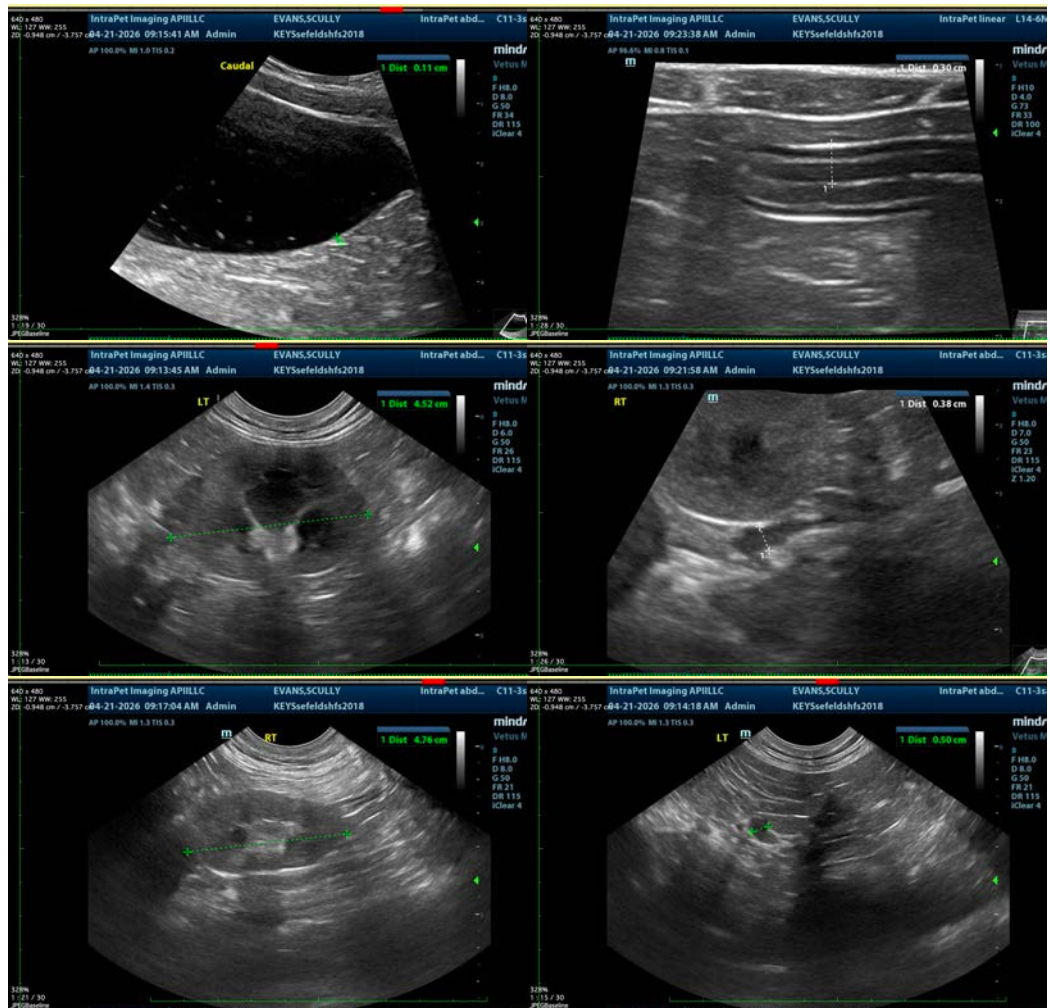
There is not a definitive ultrasonographically visible intraabdominal explanation for patient's reportedly increased ALT. Given the reportedly normal high-normal T4, especially if there are any clinical signs consistent with hyperthyroidism, a free T4 could be considered.

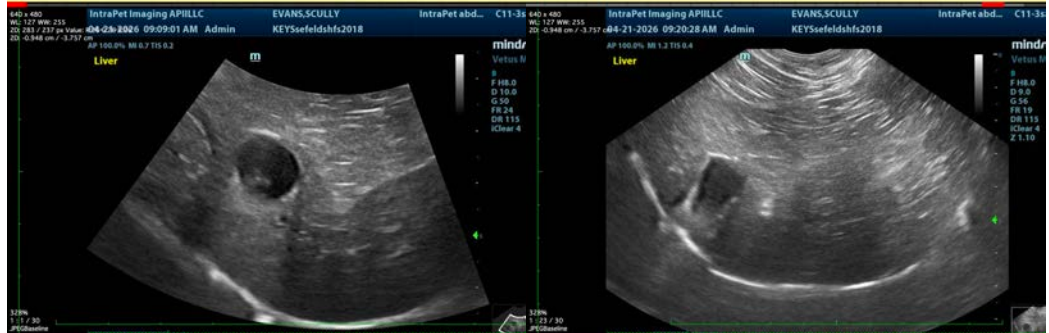
Sampling of the liver, beginning with a fine needle aspirate could be considered if patient's coagulation status is appropriate.

Bile acids are also recommended if patient's total bilirubin is not increased.

In the meantime, given the subtle bowel changes, a gastrointestinal malabsorption panel (including cobalamin, folate, TLI and PLI) to Texas A&M GI Laboratory is recommended for further evaluation of GI and pancreatic function.

Other than supportive/symptomatic medical management of clinical signs, further treatment recommendations are largely dependent on results of the above.





The information and recommendations provided are based on the images presented by the referring veterinarian/sonographer. No evaluation can be communicated regarding pathology that was not visible in the image/video clips provided.

Thank you for this referral. If the clinical or image interpretation does not parallel your findings or if I can be of any further assistance please contact me.

Beth Johnson, DVM, DACVIM
info@sonopath.com