



DATE PRESENTING CLINICAL SIGNS

04/21/26 Patient History: Trouble breathing, loose stool started last night. Painful upon palpation of abdomen along right side with cranial organomegaly; on pocus, large cavitated mass in approximate location of right kidney and unable to visualize normal kidney, trace FF around the mass

PATIENT

Josie Lewis Current Medications: Dasuquin, Butorphanol.
Labwork Results: Labwork not attached.

SPECIES

Canine

Date of Previous IntraPet Ultrasound: No previous.
Sedation: Not required to complete full diagnostic ultrasound.
Stat Report: STAT requested.
Imaging Performed by: Rachel Brillhart, RDMS.

BREED

Dachshund

ULTRASONOGRAPHIC EXAMINATION OF THE ABDOMEN

Urinary System

SEX

Spayed Female

Urinary bladder is adequately distended with anechoic contents. No masses, inflammatory changes, echogenic sediment or cystoliths are observed. The urinary bladder, trigone and visible pelvic urethra are normal in thickness with a smooth mucosal surface.

AGE

02/10/11

The left kidney is overall normal in size and shape with smooth peripheral margination. A normal 1:3 cortex to medulla ratio is maintained. The medulla and cortices are uniform in texture with some mild increased cortical echogenicity and mild loss of corticomedullary distinction, expected in this age patient. There is no evidence of pyelectasia, mineral or infarcts observed. The left kidney measures 5.95 cm. Multiple too numerous to count cortical cysts are noted throughout the left kidney.

WEIGHT

31.6 pounds

The right kidney demonstrates very little normal renal architecture and of the visible renal architecture, marked pyelectasia/hydronephrosis is noted. In the place of most of the expected normal renal architecture is an approximately 8.15 cm in size mixed heterogeneous largely fluid filled density/mass. Adjacent to this density/mass is free fluid and enhanced hyperechoic tissue.

INTERPRETED BY

Beth Johnson, DVM
DACVIM

Adrenal Glands

HOSPITAL NAME

Animal Emergency
Hospital

Left adrenal gland is normal in size (0.59 cm at cranial pole and 0.59 cm at caudal pole), shape and overall architecture, echogenicity and echotexture. Visible surrounding vasculature appears normal.

Right adrenal gland is normal in size (0.81 cm at cranial pole and 0.66 cm at caudal pole), shape and overall architecture, echogenicity and echotexture. Visible surrounding vasculature appears normal.

REFERRING VET

Dr. Reynolds

Spleen

Spleen is subjectively normal in size with a normal smooth capsular contour. Parenchyma is appropriately finely textured and homogenous with normal echogenicity relative to surrounding tissue (hyperechoic to liver). Multifocal well-demarcated hyperechoic homogenous nodules are noted. Splenic vasculature appears normal.

INVOICE

15279

Liver

Liver is subjectively normal in size with normal smooth curvilinear peripheral contour. Parenchyma is appropriately hypoechoic to the spleen in echogenicity and appropriately mildly coarse and homogenous in

echotexture. Visible vasculature and biliary tree appear normal without distension or congestion. In the left liver, there's a large 6.4 cm x 8.0 cm mildly heterogeneous largely hypoechoic mass.

Gallbladder is moderately distended with anechoic bile as well as suspended and gravity dependent echogenic debris. The wall is smooth without visible thickening. There is no evidence of cystic or CBD dilation. There is no evidence of effusion or inflammation.

Gastrointestinal

The visible stomach wall is normal in thickness and layering. The lumen of the stomach is mildly distended with primarily fluid as well as some echogenic non-shadowing luminal contents and gas consistent with normal chyme. There is no evidence of obstruction, foreign material, or infiltrative disease. Pyloric outflow tract appears patent.

The visible small intestines are normal in wall thickness and layering. Small intestinal motility appears adequate (1-3 contractions per min). The lumen of the small intestine is empty with no evidence of obstruction, foreign material or infiltrative disease.

The visible colon is normal in wall thickness (< 0.2 cm) and layering. Contents are consistent with normal formed feces and gas.

Pancreas

The pancreas that is observed appears appropriately isoechoic to surrounding omental fat. Visible capsule is smooth and normal in contour. Visible pancreatic parenchyma is homogenous and unremarkable. There is no visible pancreatic duct dilation. There is no evidence of active peripancreatic inflammation.

Free Abdomen

Transdiaphragmatic views revealed a comet tail lung pattern, echogenic sound wave interfaces as a result of microconsolidations within the lung field. The lung field should not be visualized by sonogram unless pathology is present.

As described above, free fluid and enhanced hyperechoic tissue are noted adjacent to the right kidney density/mass.

There is no apparent pathologic lymphadenopathy noted in these images.

ULTRASONOGRAPHIC FINDINGS

- A mixed partially solid, partially fluid filled right kidney mass could represent a benign process such as a complicated cyst or even abscess versus hematoma versus other. Having said that, infiltrative neoplasia can't be ruled out without tissue sampling. The adjacent free fluid and enhanced tissue are concerning for a focal inflammation which could be contributing to patient's reported discomfort in that area.
- The liver mass could represent a benign process such as a hepatoma/adenoma, chronic inflammatory change, other although infiltrative neoplasia including round cell neoplasia, hepatocellular carcinoma, potentially related to the kidney lesion but not definitively related to the kidney lesion can't be ruled out without tissue sampling.

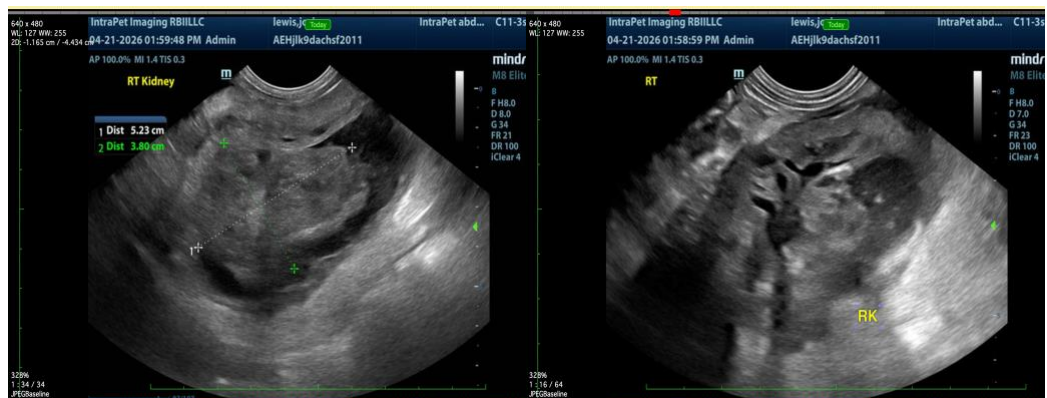
- Ring downs- suggestive of lung pathology such as infiltrative neoplasia, thromboembolic disease, chronic inflammatory disease, etc.
- Age-related kidneys with multiple cortical cysts in the left kidney.
- Hyperechoic splenic nodules- most consistent with benign myelolipomas. Other differentials such as fibrosis or calcification caused by old hematomas or infarcts, chronic inflammation, granulomatous disease or metastatic disease cannot be ruled out, but are considered less likely.
- Mild gallbladder debris- Cholecystic debris is of unknown clinical significance. It can be seen with biliary stasis from fasting or illness. Cholecystic debris is not necessarily related to hepatobiliary disease. Echogenic bile is most commonly an incidental finding in dogs and should be interpreted in combination with clinical signs such as nausea, inappetence, cranial abdominal discomfort and/or laboratory changes such as increased ALP and/or increased Tbili.

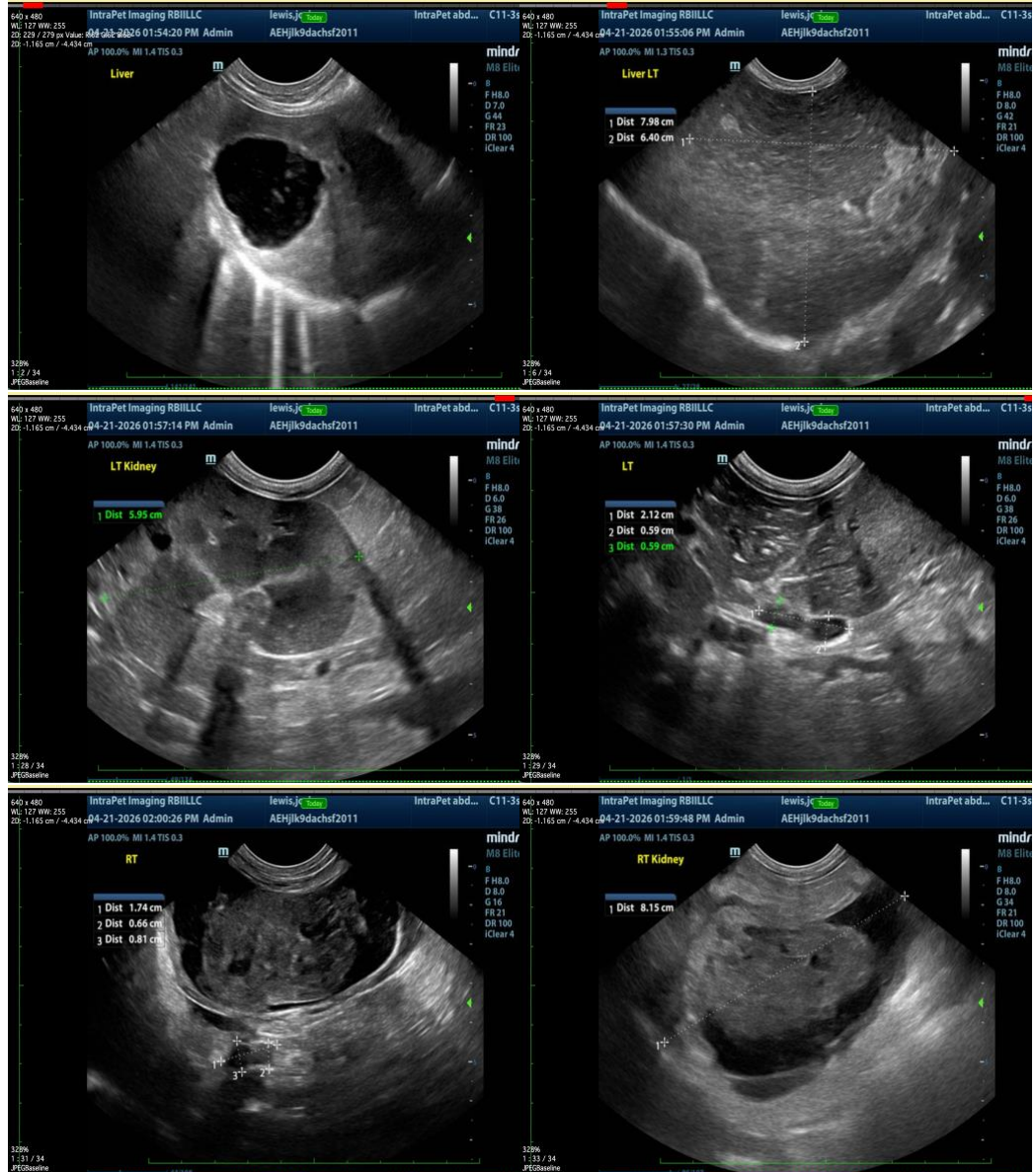
INTERPRETATION OF THE FINDINGS & FURTHER RECOMMENDATIONS

Three view thoracic radiographs are recommended for further assessment of cardio-pulmonary status as well as to further evaluate for any evidence of metastatic disease, if not recently evaluated.

Fine needle aspirates of the liver mass and the right kidney mass are recommended for cytology as well as potentially fluid analysis, culture and sensitivity etc. depending on what is retrieved from the right kidney mass, if patient's coagulation status is appropriate.

Ultimately, pending results, an expiratory laparotomy for possible nephrectomy +/- liver lobectomy/excisional biopsies may be recommended but given the degree of pathology, if pursued, a pre-surgical planning abdominal CT scan +/- concurrent thoracic CT scan could be considered.





The information and recommendations provided are based on the images presented by the referring veterinarian/sonographer. No evaluation can be communicated regarding pathology that was not visible in the image/video clips provided.

Thank you for this referral. If the clinical or image interpretation does not parallel your findings or if I can be of any further assistance, please contact me.

Beth Johnson, DVM DACVIM

info@sonopath.com

