

**DATE PRESENTING CLINICAL SIGNS**

4/21/22

Presented 4/5/2022 for onset of frequent vomiting and episodically runny stools in association with transition in diet from Purina One to Iams food. Vomiting resolved with rice + chicken (or beef) but recurred when Purina was reintroduced. The stools were usually formed but occasionally runny. Unintentional weight loss since 2013 from 70lbs to 57lbs.

**PATIENT**

Jasmine Makres

**SPECIES**

Canine

**BREED**

German Shepherd

**SEX**

Intact Female

**AGE**

2/19/11

**WEIGHT**

57 Pounds

**INTERPRETED BY**Beth Johnson, DVM  
DACVIM**IMAGING PERFORMED BY**Stephanie Pearce  
RDMS, RVT**HOSPITAL NAME**

Essex Middle River VC

**REFERRING VET**

Dr. Smith

**INVOICE**

37077

Current Medications: 4/5/2022 Cerenia 60mg PO q24h x 4d.

Lab Results: Labwork on 4/14/2022 reflects N bG 89, Na/K 32, SDMA 11, CREA 1.1, ALB 2.9, GLOB 3.6, and normal liver values; HIGH LIPASE 465 (0-250); Normal T4 1.9; WBC 6.2 (4.9-17.6), RBC 6.37 (5.39-8.7), HGB 15.6 (13.4-20.7) with HIGH PLATELETS 778 (143-448); 4DX NEGATIVE x4; UA and Fecal O&P are pending sample submission by client.

Date of Previous IntraPet Ultrasound: No previous.

Sedation: Not required to complete full diagnostic ultrasound.

Stat Report: Not requested.

**ULTRASONOGRAPHIC EXAMINATION OF THE ABDOMEN****Urinary System**

The urinary bladder is moderately distended with anechoic contents. No masses, inflammatory changes, echogenic sediment or cystoliths are observed. The urinary bladder, trigone and visible pelvic urethra are normal in thickness with a smooth mucosal surface.

The right kidney is normal in size (6.06 cm), shape and echogenicity. It has smooth peripheral margination. There is a normal 1:3 cortex to medulla ratio with appropriate corticomedullary distinction. There is no evidence of pyelectasia, mineral or infarcts observed.

The left kidney is normal in size (6.11 cm), shape and echogenicity. It has smooth peripheral margination. There is a normal 1:3 cortex to medulla ratio with appropriate corticomedullary distinction. There is no evidence of pyelectasia, mineral or infarcts observed.

**Adrenal Glands**

The right adrenal gland is normal in size (2.16 cm long x 0.82 cm at the cranial pole and 0.75 cm at the caudal pole), shape and contour. Corticomedullary structure is unremarkable. Visible surrounding vasculature appears normal.

The left adrenal gland is normal in size (3.3 cm long x 0.78 cm at the cranial pole and 0.83 cm at the caudal pole), shape and contour. Corticomedullary structure is unremarkable. Visible surrounding vasculature appears normal.

**Spleen**

The spleen is subjectively normal in size with a normal smooth capsular contour. Parenchyma is appropriately finely textured and homogenous with normal echogenicity relative to surrounding tissue (hyperechoic to liver). No focal nodules or masses are observed. Splenic vasculature appears normal.

**Liver**

The liver is subjectively normal in size with normal smooth curvilinear peripheral contour. Parenchyma is appropriately hypoechoic to the spleen in echogenicity and appropriately mildly coarse and homogenous in echotexture. No focal lesions are observed. Visible vasculature and biliary tree appear normal without distension or congestion.

GB is moderately distended with anechoic bile and gravity dependent echogenic sediment. The wall is smooth without visible thickening. There is no evidence of cystic or CBD dilation. There is no evidence of effusion or inflammation.

### ***Gastrointestinal***

The stomach wall is normal in thickness (canine < 0.5 cm and feline < 0.4 cm) and layering. The lumen of the stomach is mildly distended with very echogenic reverberation artifact from intraluminal gas. There is no evidence of obstruction, foreign material or infiltrative disease; however, complete visualization of far wall is partially inhibited by gas. Pyloric outflow tract appears patent.

The visible small intestines are normal in wall thickness and layering (canine duodenum < 0.5 cm and feline duodenum < 0.4 cm; other < 0.3 cm). Small intestinal motility appears adequate (1-3 contractions per min). The lumen of the small intestine is empty with no evidence of obstruction, foreign material or infiltrative disease.

The visible colon is normal in wall thickness (< 0.2 cm) and layering. Contents are consistent with normal formed feces and gas.

### ***Pancreas***

The pancreatic parenchyma is appropriately isoechoic to surrounding tissue. Visible capsule is smooth and normal in contour. There is no visible pancreatic duct dilation. There is no evidence of active peripancreatic inflammation.

### ***Other***

There is no evidence of peritoneal effusion. There is no apparent lymphadenopathy.

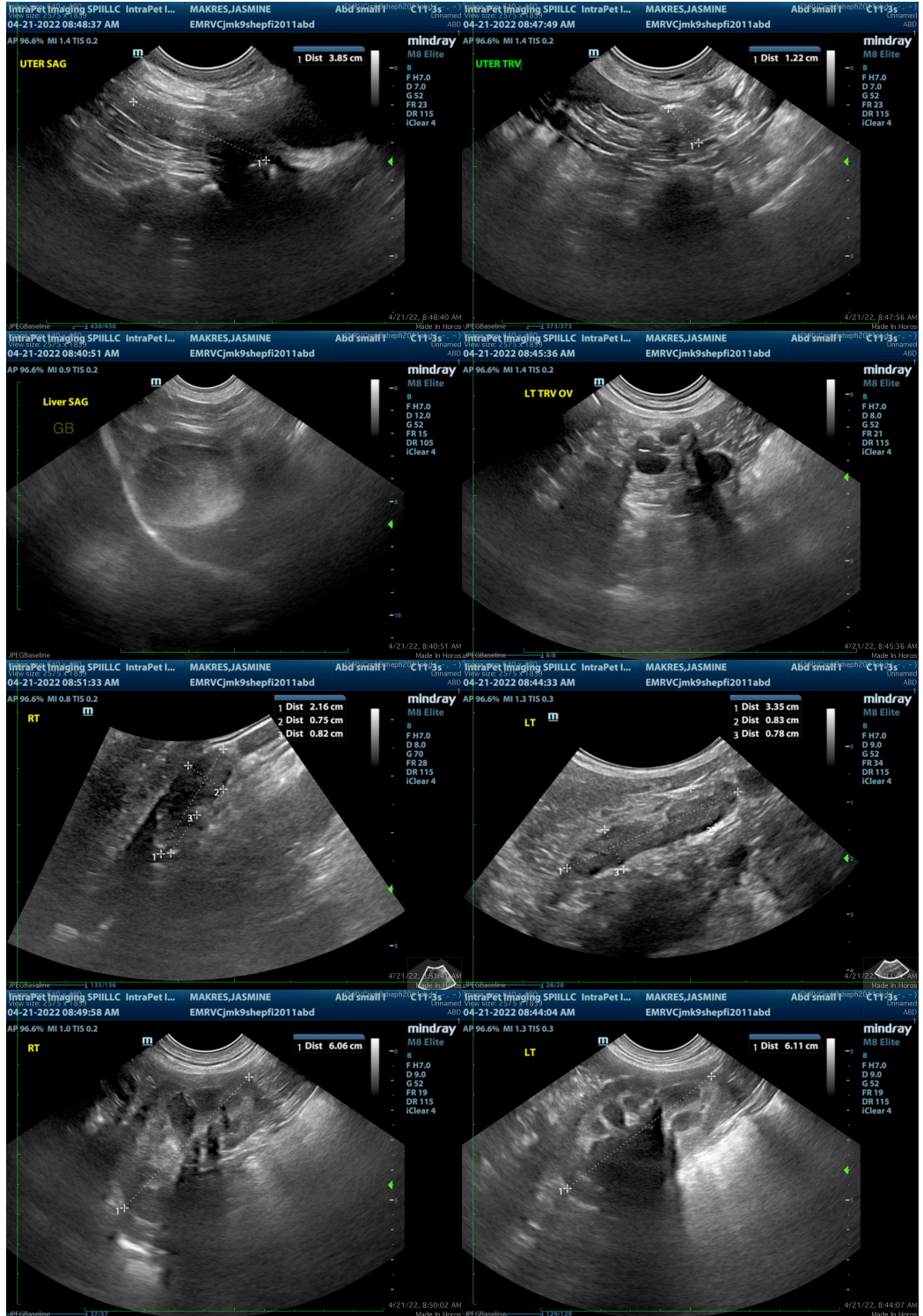
Cystic ovaries are noted. The uterus is visible without evident pathology.

## **ULTRASONOGRAPHIC FINDINGS**

- Gallbladder debris - Cholecystic debris is of unknown clinical significance. It can be seen with biliary stasis from fasting or illness. Cholecystic debris is not necessarily related to hepatobiliary disease. Echogenic bile is most commonly an incidental finding in dogs and should be interpreted in combination with clinical signs such as nausea, inappetence, cranial abdominal discomfort and/or laboratory changes such as increased ALP and/or increased Tbili.
- Cystic ovaries

## **INTERPRETATION OF THE FINDINGS & FURTHER RECOMMENDATIONS**

Given this patient's clinical signs and breed, exocrine pancreatic insufficiency is a top differential, and recommendations include a gastrointestinal malabsorption panel including TLI, PLI, folate and cobalamin to Texas A&M GI laboratory. In the meantime, empirical therapies could include probiotic as well as cobalamin supplementation once a sample has been drawn to test cobalamin levels. Infiltrative small bowel disease can be present without ultrasonographic changes. Therefore, if the TLI is normal, ruling out EPI, especially if there are other indicators of decreased gastrointestinal function, with biopsies of the bowel may be necessary to definitively diagnosis and therefore manage this patient's underlying disease.



**The information and recommendations provided are based on the images presented by the referring veterinarian/sonographer. No evaluation can be communicated regarding pathology that was not visible in the image/video clips provided.**

Thank you for this referral. If the clinical or image interpretation does not parallel your findings or if I can be of any further assistance please contact me.

**Beth Johnson, DVM, DACVIM**  
Beth.Johnson@sonopath.com