

**PATIENT**

Zelda Moran

SPECIES

Canine

BREED

German Shepherd

SEX

Spayed Female

AGE

3 Years 10 Months

WEIGHT

80.8 Pounds

INTERPRETED BYBeth Johnson, DVM
DACVIM**IMAGING PERFORMED BY**

Amy Mayhew, LVT

HOSPITAL NAME

SVS Imaging MI

REFERRING VET

Dr. Totin

INVOICE

46821

DATE

4/20/23

PRESENTING CLINICAL SIGNS

Urinary incontinence.

Abnormal PE/Chem/CBC/UA Results: Hx of allergies. Neutropenia noted with elevated ggt Urine culture no growth.

ULTRASONOGRAPHIC EXAMINATION OF THE ABDOMEN**Urinary System**

The urinary bladder is moderately distended with anechoic contents. No masses, inflammatory changes, echogenic sediment or cystoliths are observed. The urinary bladder, trigone and visible pelvic urethra are normal in thickness with a smooth mucosal surface. On the dorsal wall approaching the apex, there is an approximately 0.60 cm, slightly irregular, echogenic density that may represent an incidental bladder wall fold. However, a benign polyp or exceedingly less likely other infiltrative disease cannot be definitively ruled out.

The right kidney is normal in size (7.05 cm), shape and echogenicity. It has smooth peripheral margination. There is a normal 1:3 cortex to medulla ratio with appropriate corticomedullary distinction. There is no evidence of pyelectasia, mineral or infarcts observed.

The left kidney is normal in size (6.88 cm), shape and echogenicity. It has smooth peripheral margination. There is a normal 1:3 cortex to medulla ratio with appropriate corticomedullary distinction. There is no evidence of pyelectasia, mineral or infarcts observed.

Adrenal Glands

The right adrenal gland is normal in size (0.42 cm at the cranial pole and 0.40 cm at the caudal pole), shape and contour. Corticomedullary structure is unremarkable. Visible surrounding vasculature appears normal.

The left adrenal gland is normal in size (0.40 cm at the cranial pole and 0.38 cm at the caudal pole), shape and contour. Corticomedullary structure is unremarkable. Visible surrounding vasculature appears normal.

Spleen

The spleen is subjectively normal in size with a normal smooth capsular contour. Parenchyma is appropriately finely textured and homogenous with normal echogenicity relative to surrounding tissue (hyperechoic to liver). No focal nodules or masses are observed. Splenic vasculature appears normal.

Liver

The liver is subjectively normal in size with normal smooth curvilinear peripheral contour. Parenchyma is appropriately hypoechoic to the spleen in echogenicity and appropriately mildly coarse and homogenous in echotexture. No focal lesions are observed. Visible vasculature and biliary tree appear normal without distension or congestion.

The gallbladder is non-distended in size. The wall is smooth without visible thickening. Luminal contents are primarily anechoic. There is no evidence of cystic or common bile duct dilation.

Gastrointestinal

The visible stomach wall is normal in thickness and layering. The lumen of the stomach is mildly distended with very echogenic reverberation artifact from intraluminal gas. There is no evidence of obstruction, foreign material or infiltrative disease; however, complete visualization of far wall is partially inhibited by gas. Pyloric outflow tract appears patent.

IMAGING PERFORMED BY

SVS Mobile Imaging MI 734-637-7711
svsimagingmi@gmail.com



PATIENT

Zelda Moran

The visible small intestines are normal in wall thickness and layering (canine duodenum < 0.5 cm and feline duodenum < 0.4 cm; other < 0.3 cm). Small intestinal motility appears adequate (1-3 contractions per min). The lumen of the small intestine is empty with no evidence of obstruction, foreign material or infiltrative disease.

SPECIES

Canine

The visible colon is normal in wall thickness (< 0.2 cm) and layering. Contents are consistent with normal formed feces and gas.

Pancreas

BREED

German Shepherd

The pancreatic parenchyma is appropriately isoechoic to surrounding tissue. Visible capsule is smooth and normal in contour. There is no visible pancreatic duct dilation. There is no evidence of active peripancreatic inflammation.

SEX

Spayed Female

Free Abdomen

There is no evidence of free peritoneal effusion noted in these images.

There is no apparent lymphadenopathy noted in these images.

AGE

3 Years 10 Months

ULTRASONOGRAPHIC FINDINGS

- Small echogenic density along the dorsal wall of the urinary bladder that appears to be an incidental bladder wall fold. However, a benign polyp or less likely other infiltrative disease cannot be definitively ruled out.

WEIGHT

80.8 Pounds

INTERPRETATION OF THE FINDINGS & FURTHER RECOMMENDATIONS

There is no ultrasonographic explanation for this patient's reported incontinence. Having said that, an anatomical abnormality including ectopic ureters (while considered unlikely with no supporting ultrasonographic evidence) cannot be definitively ruled out. An abdominal contrast CT scan could be considered to definitively rule them out.

INTERPRETED BY

Beth Johnson, DVM
DACVIM

In the meantime, however, top differentials for this patient's incontinence include urethral disorder such as urethral sphincter mechanism incompetence (commonly known as "spay incontinence") or an underlying neurologic condition, potentially resulting in bladder/urethral dyssynergy or other urge incontinence scenarios. Therefore, if not already evaluated, full neurologic evaluation is also recommended.

IMAGING PERFORMED BY

Amy Mayhew, LVT

Likely unrelated to the incontinence, this patient's reported neutropenia (if persistent) warrants further evaluation via potentially a comprehensive infectious disease evaluation and/or bone marrow cytology.

HOSPITAL NAME

SVS Imaging MI

In the meantime, empirical deworming with a 5-day course of Panacur is recommended.

REFERRING VET

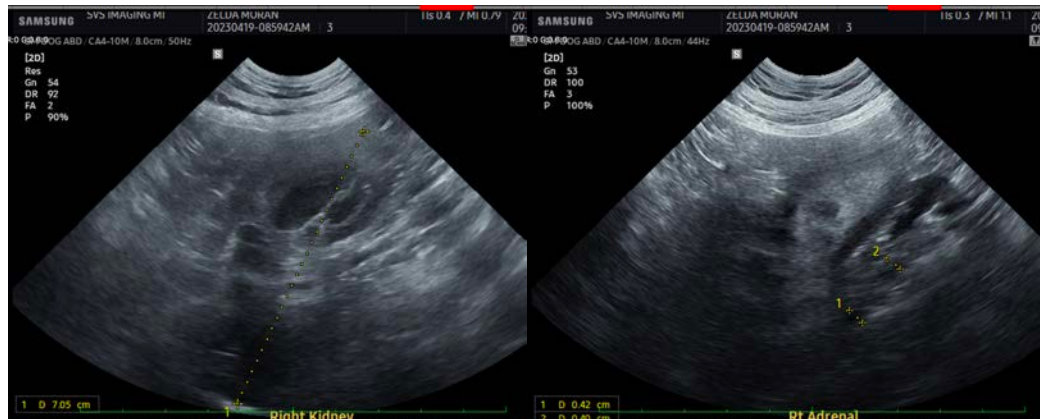
Dr. Totin

INVOICE

46821

DATE

4/20/23



IMAGING PERFORMED BY

SVS Mobile Imaging MI 734-637-7711
svsimagingmi@gmail.com



PATIENT

Zelda Moran

SPECIES

Canine

BREED

German Shepherd

SEX

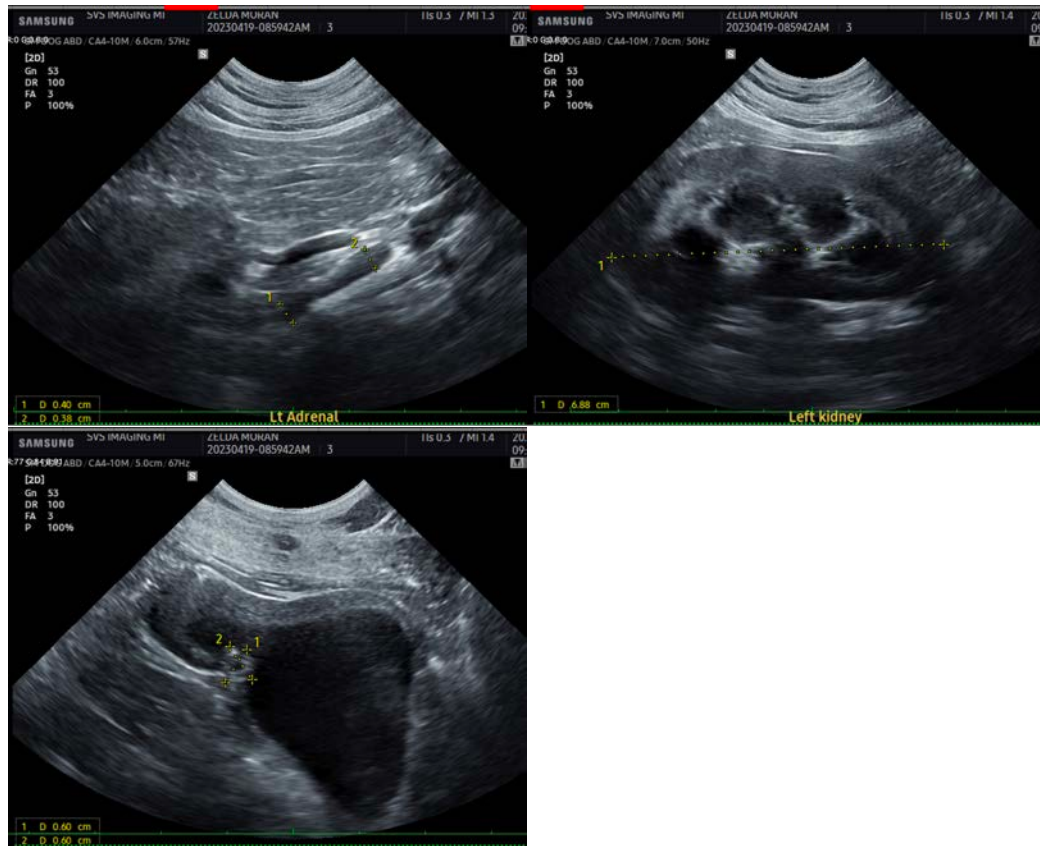
Spayed Female

AGE

3 Years 10 Months

WEIGHT

80.8 Pounds



INTERPRETED BY

Beth Johnson, DVM
DACVIM

IMAGING PERFORMED BY

Amy Mayhew, LVT

HOSPITAL NAME

SVS Imaging MI

REFERRING VET

Dr. Totin

INVOICE

46821

DATE

4/20/23

The information and recommendations provided are based on the images presented by the referring veterinarian/sonographer. No evaluation can be communicated regarding pathology that was not visible in the image/video clips provided.

Thank you for this referral. If the clinical or image interpretation does not parallel your findings or if I can be of any further assistance please contact me.

Beth Johnson, DVM, DACVIM
Beth.Johnson@sonopath.com