

**DATE PRESENTING CLINICAL SIGNS**

4/20/23 Chronic diarrhea, vomiting. Previous diagnosis of IBD with less likely neoplasia *8/15/22).

PATIENT

Pretty Pettijohn

Current Medications: Prednisone 2.5mg SID, Cerenia 4mg SID, Vitamin B12 0.25mL q7d, Mirataz q48hrs.
Lab Results: 2/27/23 CBC/Chem/T4 NSF. 3/14/23 GI panel WNL.

Date of Previous IntraPet Ultrasound: 8/15/22 See attached.

Sedation: Not required to complete full diagnostic ultrasound.

Stat Report: Not requested.

SPECIES

Feline

Imaging Performed By: Stephanie Warga RDCS, RVT.

ULTRASONOGRAPHIC EXAMINATION OF THE ABDOMEN**BREED**

DSH

Urinary System

The urinary bladder is moderately distended with anechoic contents. No masses, inflammatory changes, echogenic sediment or cystoliths are observed. The urinary bladder, trigone and visible pelvic urethra are normal in thickness with a smooth mucosal surface.

SEX

Spayed Female

The right kidney is normal in size (3.24 cm), shape and echogenicity. It has smooth peripheral margination. There is a normal 1:3 cortex to medulla ratio with appropriate corticomedullary distinction. There is no evidence of pyelectasia, mineral or infarcts observed.

AGE

2/6/15

The left kidney is normal in size (3.51 cm), shape and echogenicity. It has smooth peripheral margination. There is a normal 1:3 cortex to medulla ratio with appropriate corticomedullary distinction. There is no evidence of pyelectasia, mineral or infarcts observed.

WEIGHT

7.26 Pounds

Adrenal Glands

The right adrenal gland is normal in size (0.27 cm), shape and contour. Corticomedullary structure is unremarkable. Visible surrounding vasculature appears normal.

INTERPRETED BY

Beth Johnson, DVM
DACVIM

The left adrenal gland is normal in size (0.34 cm), shape and contour. Corticomedullary structure is unremarkable. Visible surrounding vasculature appears normal.

HOSPITAL NAME

Northwind AH

Spleen

The spleen is subjectively normal in size with a normal smooth capsular contour. Parenchyma is appropriately finely textured and homogenous with normal echogenicity relative to surrounding tissue (hyperechoic to liver). No focal nodules or masses are observed. Splenic vasculature appears normal.

REFERRING VET

Dr. Miller

Liver

The liver is subjectively normal in size with normal smooth curvilinear peripheral contour. Parenchyma is appropriately hypoechoic to the spleen in echogenicity and appropriately mildly coarse and homogenous in echotexture. Multifocal nodules/masses of mixed echogenicity, primarily hyperechoic in echogenicity but containing multiple cysts of varying size, are noted, one in the deep right liver measuring approximately 2.7 cm in diameter, and a 2nd in the more caudal right liver measuring approximately 1.0 cm in diameter. Visible vasculature and biliary tree appear normal without distension or congestion.

INVOICE

46831

Gallbladder is moderately distended with anechoic bile as well as suspended and gravity dependent echogenic debris. The wall is smooth without visible thickening. There is no evidence of cystic or CBD dilation. There is no evidence of effusion or inflammation.

Gastrointestinal

The stomach wall is normal in thickness (canine < 0.5 cm and feline < 0.4 cm) and layering. The lumen of the stomach is empty with no evidence of obstruction, foreign material or infiltrative disease. Pyloric outflow tract appears patent.

Diffusely, the visible small intestine demonstrates areas of thick muscularis layer relative to mucosa (disruption of the normal 1:3 muscularis:mucosa ratio). Small intestinal submucosa is slightly irregular, thick and hyperechoic, without evident loss of layering appreciated. The lumen is empty with no evidence of obstruction or foreign material. Focally, in the mid caudal abdomen, there is an approximately 1.1 cm long loop of small bowel with an asymmetrically thick wall measuring 0.40 cm thick and loss of layering emerging.

The colon is diffusely thick, measuring 0.40 cm thick with layering intact. Contents are consistent with normal formed feces and gas.

Pancreas

Pancreas is prominent in size with swollen irregular contour. Parenchyma is heterogenous characterized by hyperechoic tissue remodeling intermixed with ill-defined hypoechoic nodules. There is no visible pancreatic duct dilation. There is no evidence of active peripancreatic inflammation.

Free Abdomen

There is no evidence of free peritoneal effusion noted in these images.

The mesenteric lymph nodes are prominent in size with swollen capsular contour. Normal elongated shape (length to width ratio) is maintained. There is no loss of parenchymal detail.

PRIMARY FINDINGS

- **Gastrointestinal lymphoma (suspect) pattern** – Thick muscularis has been reported with infiltrative bowel disease including both benign inflammatory disease as well as infiltrative neoplasia such as lymphoma. Given the concurrent pathology noted, infiltrative neoplasia is considered more likely, but benign IBD cannot be ruled out without tissue sampling. This differential is ranked higher on this study due to the asymmetrical loss of layering in the small bowel as well as the progressive lymphadenopathy, which may be reactive but could also represent infiltrative neoplasia such as lymphoma, and the new colon changes.
- **Feline biliary cystadenomas** – In a senior cat, these liver lesions are most consistent with multiple benign biliary cystadenomas. Malignancy cannot be ruled out but is considered less likely given lack of clinical signs and/or laboratory changes.
- **Pancreatic nodular hyperplasia** – Infiltrative neoplasia cannot be ruled out but is considered less likely.

SECONDARY FINDINGS

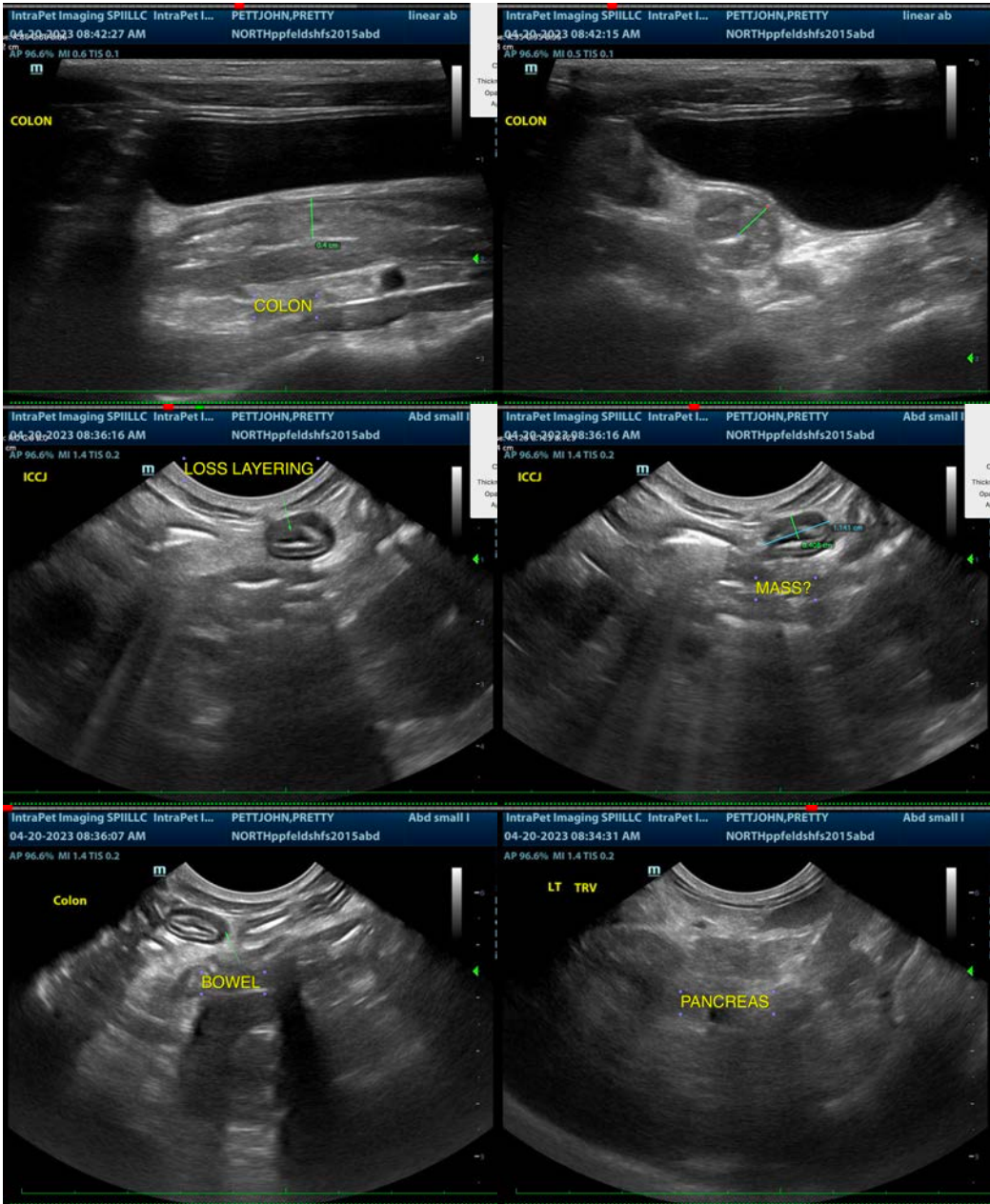
- **Mild gallbladder debris** - Cholecystic debris is of unknown clinical significance. It can be seen with biliary stasis from fasting or illness, however, it can also be associated with hepatobiliary disease in cats and should be interpreted in combination with clinical signs such as nausea, inappetence, cranial abdominal discomfort and/or laboratory changes such as increased ALP and/or increased Tbili.

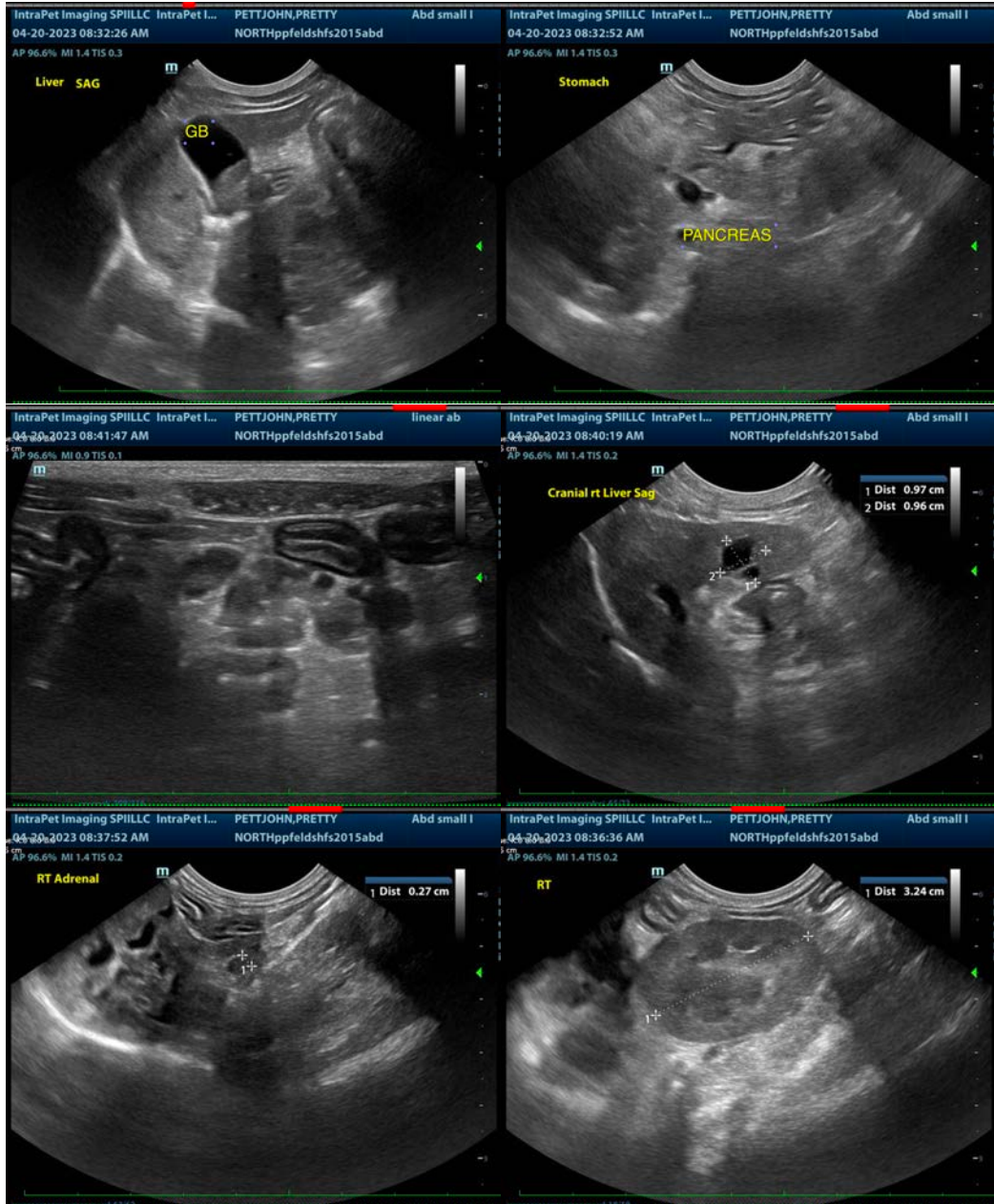
INTERPRETATION OF THE FINDINGS & FURTHER RECOMMENDATIONS

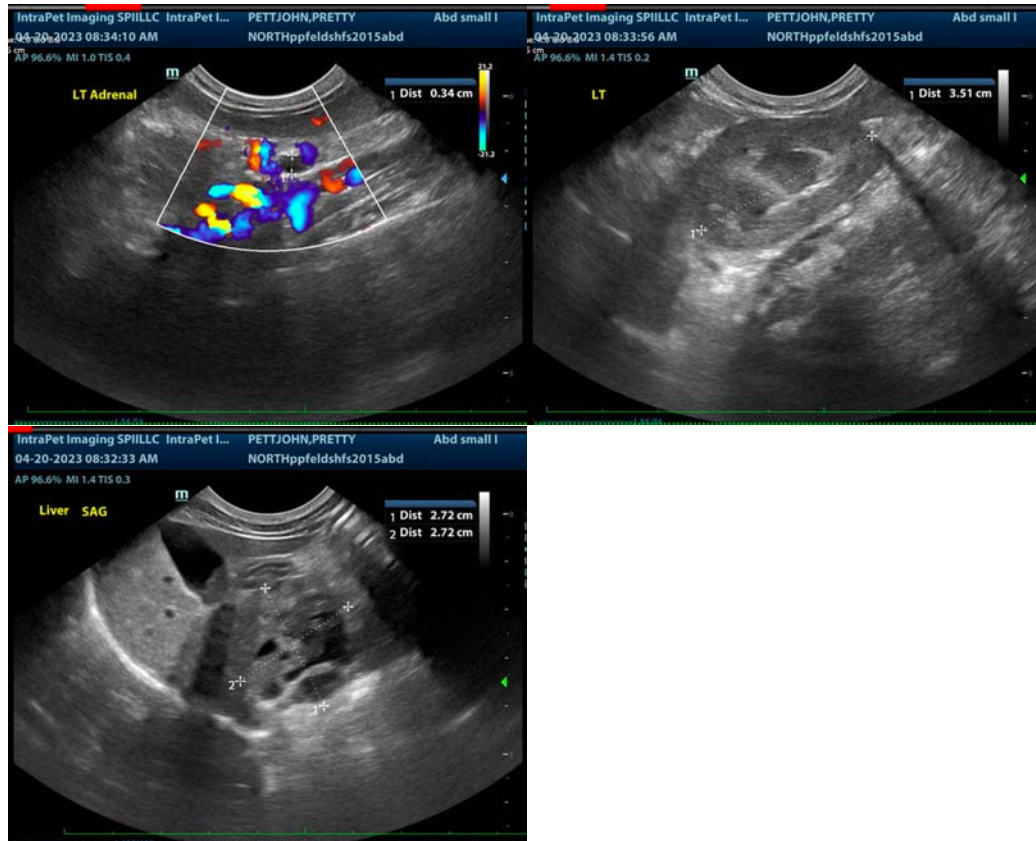
Tissue sampling is necessary in this patient to make a definitive diagnosis, although infiltrative neoplasia/emerging lymphoma is suspected. Fine needle aspirates of the enlarged lymph nodes could be

considered if patient's coagulation status is appropriate, or potentially even the focal small bowel mass. If not, the biopsies of the GI tract via either upper and lower endoscopy/colonoscopy or potentially full thickness surgical biopsies may ultimately be warranted.

In the meantime, additional empirical therapies to the ones reportedly already in place could include a probiotic such as Visbiome or Provable to help with the diarrhea, and potentially a transition in diet, beginning with a hydrolyzed protein diet, and knowing that some patients respond better to one brand or version of hydrolyzed protein diet versus another, so sometimes several trials are necessary.







The information and recommendations provided are based on the images presented by the referring veterinarian/sonographer. No evaluation can be communicated regarding pathology that was not visible in the image/video clips provided.

Thank you for this referral. If the clinical or image interpretation does not parallel your findings or if I can be of any further assistance please contact me.

Beth Johnson, DVM, DACVIM
Beth.Johnson@sonopath.com