



PATIENT	PRESENTING CLINICAL SIGNS
Minka Kovacevich	Lethargic, not eating well, has murmur (grade not given).
SPECIES	ULTRASONOGRAPHIC EXAMINATION OF THE ABDOMEN
Feline	Urinary System
BREED	The urinary bladder is moderately distended with anechoic contents. No masses, inflammatory changes, echogenic sediment or cystoliths are observed. The urinary bladder, trigone and visible pelvic urethra are normal in thickness with a smooth mucosal surface.
DLH	
SEX	Kidneys are bilaterally irregular and diffusely echogenic with decreased corticomedullary distinction and poor visualization of internal architecture. There is no pyelectasia noted and no mineral is observed. The left kidney was normal in size at 3.57 cm. The right kidney was small in size at 2.92 cm.
Spayed Female	
AGE	Adrenal Glands
15 Years	The right adrenal gland is normal in size (0.33 cm), shape and contour. Corticomedullary structure is unremarkable. Visible surrounding vasculature appears normal.
WEIGHT	The left adrenal gland is normal in size (0.38 cm), shape and contour. Corticomedullary structure is unremarkable. Visible surrounding vasculature appears normal.
8.5 Pounds	
INTERPRETED BY	Spleen
Beth Johnson, DVM DACVIM	Spleen is subjectively large in size with subtly scalloped or undulating capsular contour. Parenchyma is normal in echogenicity with a mildly coarse/heterogenous echotexture. No focal nodules or masses are observed. Splenic vasculature appears normal.
IMAGING PERFORMED BY	Liver
Kelly Reschny	Liver is subjectively enlarged (swollen contour) without disruption of architecture. It has a normal homogenous echotexture. Parenchyma is diffusely hyperechoic characterized by less prominent than normal portal vein walls and increased echogenicity relative to the spleen and falciform fat. No focal lesions are observed. Visible vasculature and biliary tree appear normal without distension or congestion.
HOSPITAL NAME	
Halton Peel AH	The gallbladder is non-distended in size. The wall is smooth without visible thickening. Luminal contents are primarily anechoic. There is no evidence of cystic or common bile duct dilation.
REFERRING VET	Gastrointestinal
Dr. Walters	The stomach wall is normal in thickness (canine < 0.5 cm and feline < 0.4 cm) and layering. The lumen of the stomach is mildly distended with fluid and echogenic non-shadowing luminal contents as well as gas. There is no evidence of obstruction, foreign material or infiltrative disease. Pyloric outflow tract appears patent.
INVOICE	
46817	
DATE	The visible small intestines are normal in wall thickness and layering (canine duodenum < 0.5 cm and feline duodenum < 0.4 cm; other < 0.3 cm). Small intestinal motility appears adequate (1-3 contractions per min). The lumen of the small intestine is empty with no evidence of obstruction, foreign material or infiltrative disease.
4/20/23	The visible colon is normal in wall thickness (< 0.2 cm) and layering. Contents are consistent with normal formed feces and gas.



PATIENT *Pancreas*

Minka Kovacevich

The pancreas is visible and generally normal in appearance, potentially mildly prominent and hypoechoic to surrounding tissue without any parenchymal changes, duct dilation, etc. The primary finding in the area of the pancreas is markedly enhanced hyperechoic mesentery surrounding it.

SPECIES

Feline

Free Abdomen

BREED

There is no evidence of free peritoneal effusion noted in these images.

DLH

There is no apparent lymphadenopathy noted in these images.

SEX

Spayed Female

ULTRASONOGRAPHIC FINDINGS

AGE

15 Years

- While the specific pancreatic changes are mild, the reactive mesentery is suggestive of inflammation and concerning for emerging or low-grade smoldering pancreatitis with possible secondary gastric ileus or delayed gastric emptying.

WEIGHT

8.5 Pounds

- **Scalloped spleen** – can be associated with benign or malignant infiltrative disease. Common causes include a reactive spleen secondary to immune stimulus or early infiltrative round cell neoplasia such as lymphoma or mast cell tumor.
- **Hyperechoic hepatomegaly** – This appearance is most consistent with benign hepatic lipodosis. Infiltrative disease such as amyloidosis or round cell neoplasia, such as mast cell tumor or less likely, lymphoma, is also possible.
- **Chronic Kidney Disease** – This appearance of the kidneys is consistent with chronic kidney disease such as chronic glomerular or interstitial nephritis, chronic pyelonephritis, etc.

INTERPRETED BY

Beth Johnson, DVM
DACVIM

INTERPRETATION OF THE FINDINGS & FURTHER RECOMMENDATIONS

IMAGING PERFORMED BY

Kelly Reschny

If not recently evaluated, a general metabolic health screen is recommended for this patient, beginning with a CBC/Chem panel and electrolytes.

HOSPITAL NAME

Halton Peel AH

Urinalysis and, if indicated based on urinalysis results, urine culture are recommended. If protein is present in an otherwise quiet sediment, protein quantification with a urine protein to creatinine ratio is recommended.

REFERRING VET

Dr. Walters

Additionally, given the reportedly new heart murmur, an echocardiogram is recommended.

INVOICE

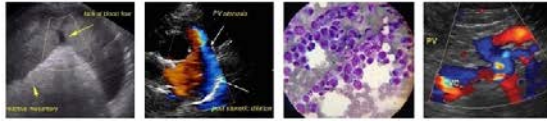
46817

Recommendations also include a quantitative PLI or ideally a gastrointestinal malabsorption panel (including cobalamin, folate, TLI and PLI) to Texas A&M GI Laboratory.

DATE

4/20/23

Pending above results and response to supportive symptomatic care, etc., fine needle aspirates of the spleen and/or liver may also need to be considered if patient's coagulation status is appropriate.



PATIENT

Minka Kovacevich

SPECIES

Feline

BREED

DLH

SEX

Spayed Female

AGE

15 Years

WEIGHT

8.5 Pounds

INTERPRETED BY

Beth Johnson, DVM
DACVIM

IMAGING PERFORMED BY

Kelly Reschny

HOSPITAL NAME

Halton Peel AH

REFERRING VET

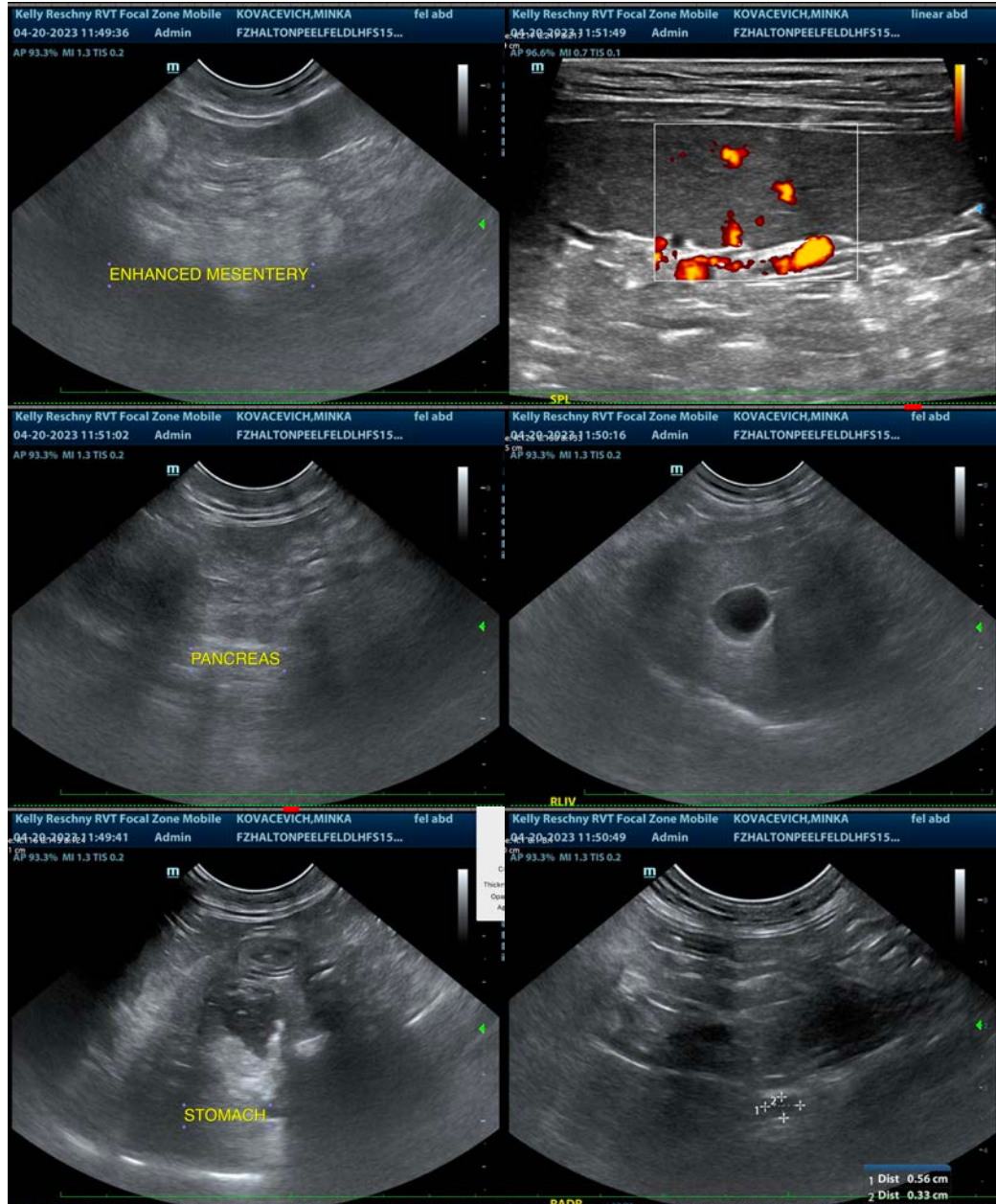
Dr. Walters

INVOICE

46817

DATE

4/20/23





PATIENT

Minka Kovacevich

SPECIES

Feline

BREED

DLH

SEX

Spayed Female

AGE

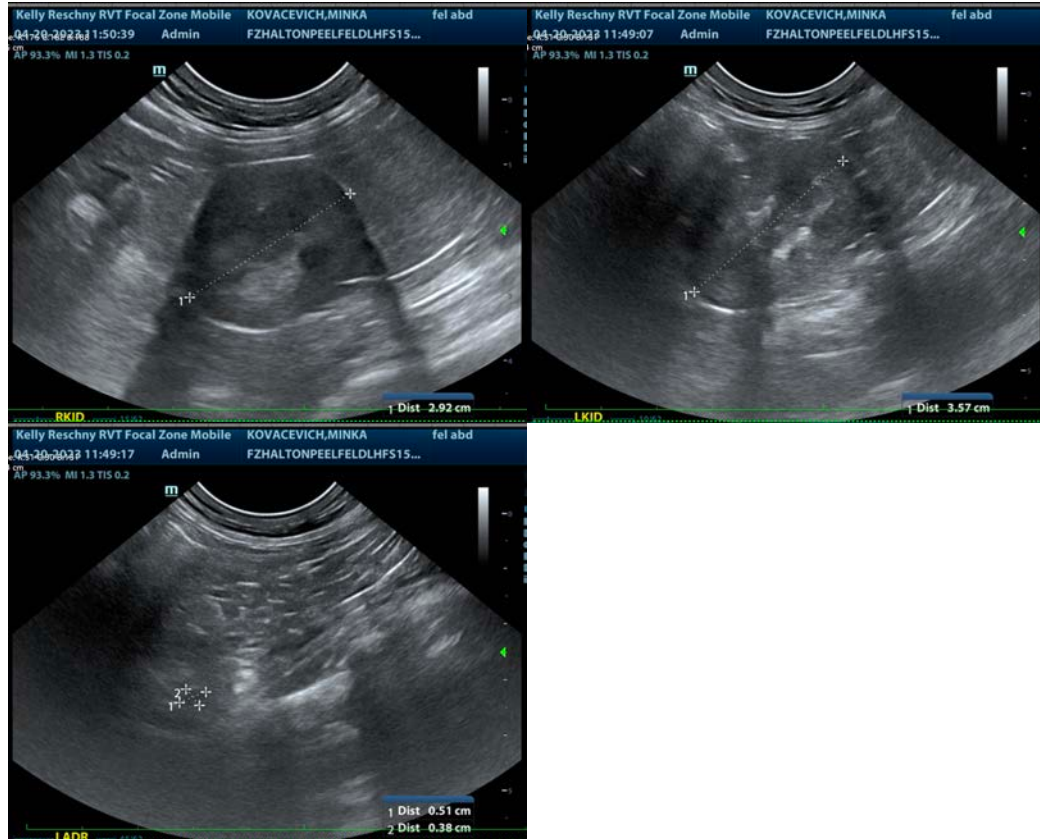
15 Years

WEIGHT

8.5 Pounds

INTERPRETED BY

Beth Johnson, DVM
DACVIM



IMAGING PERFORMED BY

Kelly Reschny

HOSPITAL NAME

Halton Peel AH

REFERRING VET

Dr. Walters

INVOICE

46817

DATE

4/20/23

The information and recommendations provided are based on the images presented by the referring veterinarian/sonographer. No evaluation can be communicated regarding pathology that was not visible in the image/video clips provided.

Thank you for this referral. If the clinical or image interpretation does not parallel your findings or if I can be of any further assistance please contact me.

Beth Johnson, DVM, DACVIM
Beth.Johnson@sonopath.com