

**PATIENT PRESENTING CLINICAL SIGNS**

Wylie Micoli supplemental bladder images, previous scan Apr 7/22 (report attached)

**SPECIES LIMITED ULTRASONOGRAPHIC EXAMINATION**

Canine

The urinary bladder is appropriately moderately distended with anechoic contents as well as suspended echogenic debris. Cranioventral urinary bladder wall is thick, measuring 0.52 cm. The mucosa is mildly irregular and contains multiple small, pedunculated masses extending into the lumen, consistent with polyps. No cystoliths are observed.

BREED

JRT

The visible pelvic urethra is normal in thickness with a smooth mucosal surface.

SEX

Neutered Male

- The urinary bladder wall changes in this patient are most consistent with chronic cystitis, potentially polypoid cystitis.

**INTERPRETATION OF THE FINDINGS & FURTHER RECOMMENDATIONS**

AGE

11 Months

Recommendations include determining the underlying cause, with differentials being chronic infections or even a parasite such as capillaria plica. If an underlying cause can be determined, then management of the underlying cause with monitoring of the bladder wall for improvement is recommended. If an underlying cause cannot be determined, cystoscopy is recommended for biopsies to obtain histopath as well as deep culture results. Therapeutic recommendations include management of the underlying cause +/- anti-inflammatories.

WEIGHT

8.2 kg

**INTERPRETED BY**

Beth Johnson, DVM  
DACVIM

**IMAGING PERFORMED BY**

Kelly Reschny

**HOSPITAL NAME**

Wellington AH

**REFERRING VET**

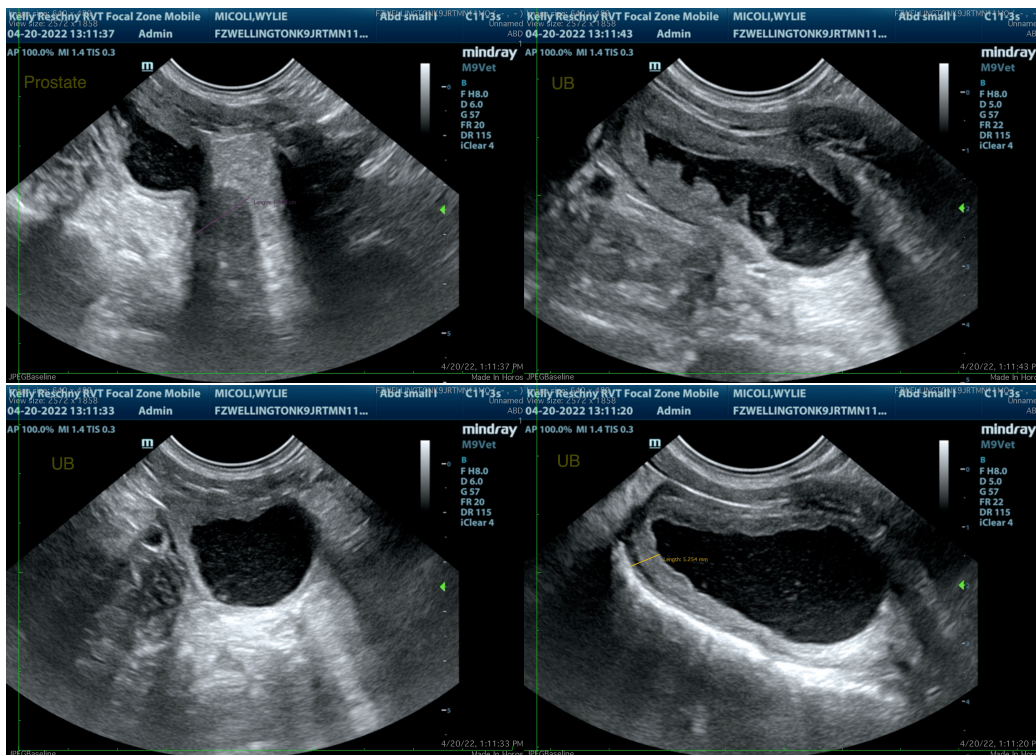
Dr. Dennis

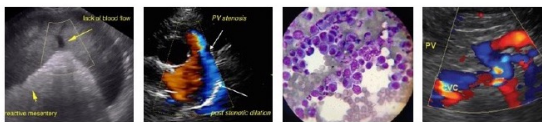
**INVOICE**

37027

**DATE**

4/20/22





**PATIENT**

Wylie Micoli

The information and recommendations provided are based on the images presented by the referring veterinarian/sonographer. No evaluation can be communicated regarding pathology that was not visible in the image/video clips provided.

**SPECIES**

Canine

Thank you for this referral. If the clinical or image interpretation does not parallel your findings or if I can be of any further assistance please contact me.

**Beth Johnson, DVM, DACVIM**  
Beth.Johnson@sonopath.com

**BREED**

JRT

**SEX**

Neutered Male

**AGE**

11 Months

**WEIGHT**

8.2 kg

**INTERPRETED BY**

Beth Johnson, DVM  
DACVIM

**IMAGING  
PERFORMED BY**

Kelly Reschny

**HOSPITAL NAME**

Wellington AH

**REFERRING VET**

Dr. Dennis

**INVOICE**

37027

**DATE**

4/20/22