

DATE PRESENTING CLINICAL SIGNS

4/20/22 P came in on 4/13/22 for a routine wellness exam and bloodwork.

PATIENT Current Medications: Simparica Trio- 1 chew monthly

Niki Pallack Lab Results: CBC WNL. Chem: Creat and BUN elevation- pre-renal vs renal (not post renal based on history/exam). SDMA normal but hemolysis is present. Elevated ALP and GGT, concern for liver/GB disease. Lipase slightly elevated, concern for possible pancreatitis vs intestinal disease. UA- very well concentrated, some elevations of BUN and Creatinine- could definitely be related to pre-renal causes. Proteinuria, UPC 0, normal. TT4 WNL.

SPECIES Radiographs:

Canine Date of Previous IntraPet Ultrasound: No previous.

BREED Sedation: Not required to complete full diagnostic ultrasound.
Stat Report: Not requested.

Toy Poodle

ULTRASONOGRAPHIC EXAMINATION OF THE ABDOMEN

SEX *Urinary System*

Neutered Male The urinary bladder is moderately distended with anechoic contents. No masses, inflammatory changes, echogenic sediment or cystoliths are observed. The urinary bladder, trigone and visible pelvic urethra are normal in thickness with a smooth mucosal surface.

AGE

9/13/10 Prostate (neutered) is normal in size, echotexture and echogenicity for a neutered male.

WEIGHT

14 Pounds The right kidney is normal in size (3.97 cm), shape and echogenicity. It has smooth peripheral margination. There is a normal 1:3 cortex to medulla ratio with appropriate corticomedullary distinction. There is no evidence of pyelectasia, mineral or infarcts observed. A hyperechoic band parallel to the corticomedullary border is present.

INTERPRETED BY

Beth Johnson, DVM
DACVIM

The left kidney is normal in size (4.02 cm), shape and echogenicity. It has smooth peripheral margination. There is a normal 1:3 cortex to medulla ratio with appropriate corticomedullary distinction. There is no evidence of pyelectasia, mineral or infarcts observed. A hyperechoic band parallel to the corticomedullary border is present.

IMAGING PERFORMED BY

Rachel Brilhart RDMS

Adrenal Glands

The right adrenal gland is normal in size (1.56 cm long x 0.71 cm at the cranial pole and 0.47 cm at the caudal pole), but plump. Corticomedullary structure is unremarkable. Visible surrounding vasculature appears normal.

HOSPITAL NAME

Taylorville Vet Clinic

The left adrenal gland is normal in size (1.5 cm long x 0.58 cm at the cranial pole and 0.53 cm at the caudal pole), but plump. Corticomedullary structure is unremarkable. Visible surrounding vasculature appears normal.

REFERRING VET

Dr. Bray

Spleen

The spleen is subjectively normal in size with a normal smooth capsular contour. Parenchyma is appropriately finely textured and homogenous with normal echogenicity relative to surrounding tissue (hyperechoic to liver). No focal nodules or masses are observed. Splenic vasculature appears normal.

INVOICE

37035

Liver

Liver is subjectively enlarged with rounded margins. Parenchyma is heterogenous characterized by multiple poorly defined hypoechoic nodules within otherwise hyperechoic liver parenchyma. Visible vasculature appears normal.

The gallbladder is non-distended in size. The wall is smooth without visible thickening. Luminal contents are primarily anechoic. There is no evidence of cystic or common bile duct dilation.

Gastrointestinal

The stomach wall is normal in thickness (canine < 0.5 cm and feline < 0.4 cm) and layering. The lumen of the stomach is empty with no evidence of obstruction, foreign material or infiltrative disease. Pyloric outflow tract appears patent.

The visible small intestines are normal in wall thickness and layering (canine duodenum < 0.5 cm and feline duodenum < 0.4 cm; other < 0.3 cm). Small intestinal motility appears adequate (1-3 contractions per min). The lumen of the small intestine is empty with no evidence of obstruction, foreign material or infiltrative disease.

The visible colon is normal in wall thickness (< 0.2 cm) and layering. Contents are consistent with normal formed feces and gas.

Pancreas

The pancreas is prominent in size and mildly irregular in shape with a diffusely coarse echotexture and heterogeneous to hyperechoic echogenicity. Peripancreatic hyperechoic fat is appreciated. No free fluid is present around the pancreas.

Free Abdomen

There is no evidence of peritoneal effusion. There is no apparent lymphadenopathy. No evidence of pericardial effusion noted.

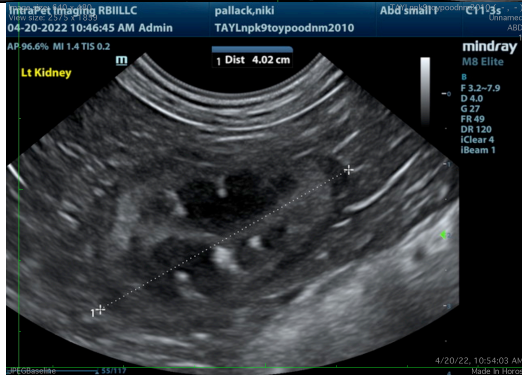
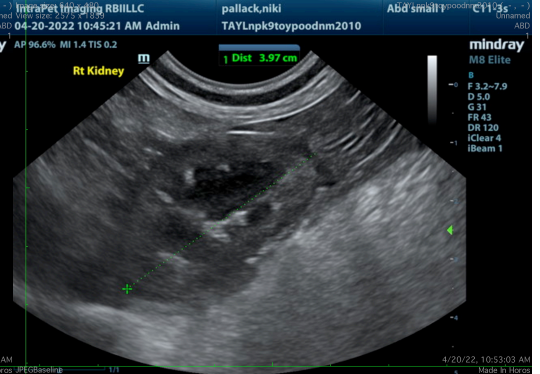
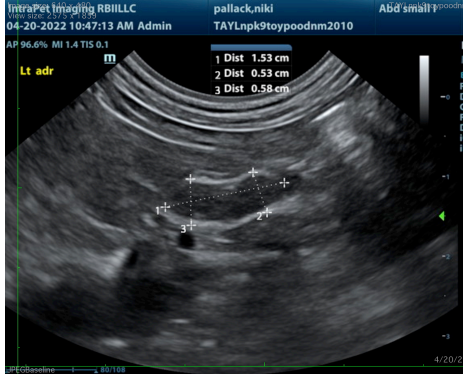
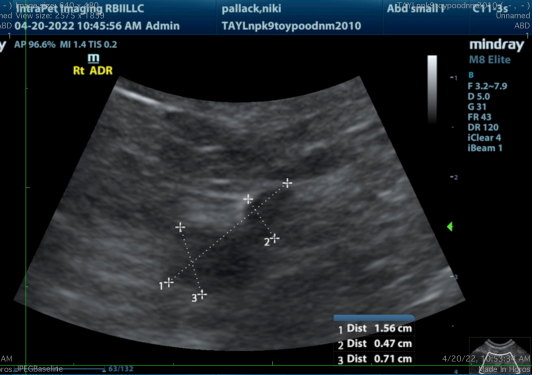
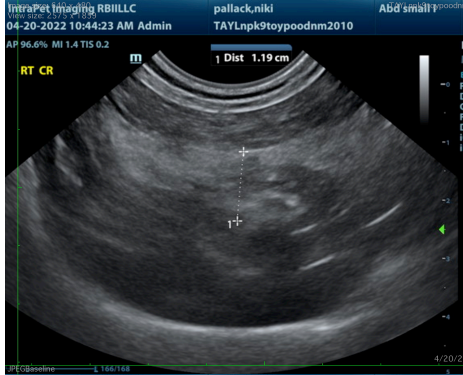
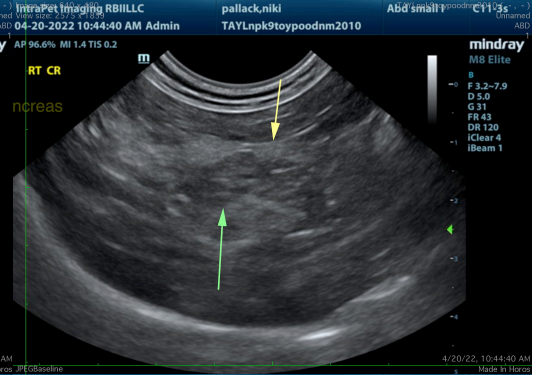
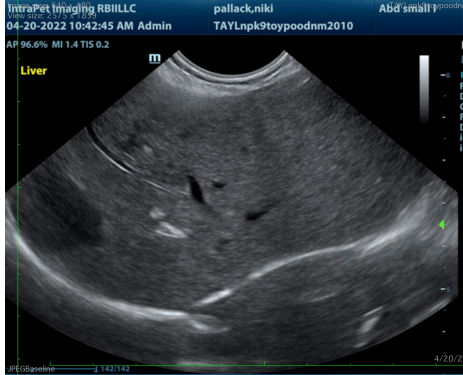
ULTRASONOGRAPHIC FINDINGS

- Chronic smoldering or acute on chronic pancreatitis – Heterogenous liver – Differentials for hepatic changes include both benign steroid (vacuolar) hepatopathy or extramedullary hematopoiesis as well as infiltrative round cell or metastatic neoplasia.
- Bilateral medullary Rim Sign - of unknown clinical significance and can be a normal variant. Medullary rim sign(s) should be interpreted in combination with other more specific indications of kidney disease such as isosthenuria, proteinuria, azotemia, etc.
- Bilateral adrenomegaly – consistent with adrenal hyperplasia secondary to pituitary depending hyperadrenocorticism vs normal variant.

INTERPRETATION OF THE FINDINGS & FURTHER RECOMMENDATIONS

Given this patient's well concentrated urine, true renal azotemia is less likely. However, given the azotemia and the medullary rim sign, close monitoring of renal values following rehydration is recommended. Blood pressure is also recommended if not recently evaluated.

Given the liver and adrenal changes combined with the increased Alk Phos, if clinical signs of hyperadrenocorticism such as polyuria, polydipsia, panting, etc. are present, testing for hyperadrenocorticism in the form of a low-dose Dexamethasone suppression test could be considered. A gastrointestinal malabsorption panel including PLI, TLI, folate and cobalamin is recommended to further assess the pancreas and bowel health. Otherwise, empirical medical recommendations include management of suspected pancreatitis with fluid therapy and potential transition to a low-fat diet. Following rehydration and transition to a low-fat diet, a recheck fasted chemistry panel to assess kidney values and triglycerides, etc. is recommended.



The information and recommendations provided are based on the images presented by the referring veterinarian/sonographer. No evaluation can be communicated regarding pathology that was not visible in the image/video clips provided.

Thank you for this referral. If the clinical or image interpretation does not parallel your findings or if I can be of any further assistance please contact me.

Beth Johnson, DVM, DACVIM
Beth.Johnson@sonopath.com