



PATIENT

Hank Sapien

SPECIES

Canine

BREED

Chiweenie

SEX

Neutered Male

AGE

Not Provided

WEIGHT

15 lbs

INTERPRETED BY

Beth Johnson, DVM
DACVIM

IMAGING PERFORMED BY

Michael Schacher

HOSPITAL NAME

Emergency Vets of
Idaho, LLC

REFERRING VET

Dr. Juli Sorenson

INVOICE

74148

DATE

4/2/26

PRESENTING CLINICAL SIGNS

Seizures - 3 x yesterday, first time seizures. ALT markedly elevated (>1000) on bloodwork)

ULTRASONOGRAPHIC EXAMINATION OF THE ABDOMEN

Urinary System

The urinary bladder is adequately distended with anechoic contents. No masses, inflammatory changes, echogenic sediment or cystoliths are observed. The urinary bladder, trigone and visible pelvic urethra are normal in thickness with a smooth mucosal surface.

Prostate is normal in size, echotexture and echogenicity for a neutered male.

Kidneys are overall normal in size and shape with smooth peripheral margination. A normal 1:3 cortex to medulla ratio is maintained. The medulla and cortices are uniform in texture with some mild increased cortical echogenicity and mild loss of corticomedullary distinction, expected in this age patient. There is no evidence of pyelectasia or infarcts observed. Left kidney measures 3.97 cm. An approximately 1.2 cm in diameter cortical cyst is noted on the caudal pole of the left kidney. The right kidney measures 4.4 cm. Pinpoint non-obstructive mineral densities are noted bilaterally.

Adrenal Glands

The areas of the adrenal glands are examined without evident adrenal gland pathology, but they are difficult to fully visualize/isolate for measurement.

Spleen

Spleen is subjectively normal in size with a normal smooth capsular contour. Parenchyma is appropriately finely textured and homogenous with normal echogenicity relative to surrounding tissue (hyperechoic to liver). Multifocal well-demarcated hyperechoic homogenous nodules are noted. Splenic vasculature appears normal.

Liver

Liver is subjectively enlarged with mildly irregular margins. Parenchyma is mildly heterogeneous characterized by multiple poorly defined hypoechoic nodules within otherwise hyperechoic liver parenchyma. Visible vasculature and biliary tree appear normal without distension or congestion.

The gallbladder is non-distended in size. The wall is smooth without visible thickening. Luminal contents are primarily anechoic. There is no evidence of cystic or common bile duct dilation.

Gastrointestinal

The visible stomach wall is normal in thickness and layering. The lumen of the stomach is empty with no evidence of obstruction, foreign material or infiltrative disease. Pyloric outflow tract appears patent.

The visible small intestines are normal in wall thickness and layering. Small intestinal motility appears adequate (1-3 contractions per min). The lumen of the small intestine is empty with no evidence of obstruction, foreign material or infiltrative disease.

The visible colon is normal in wall thickness (< 0.2 cm) and layering. Contents are consistent with normal formed feces and gas.



PATIENT

Hank Sapien

SPECIES

Canine

BREED

Chiweenie

SEX

Neutered Male

AGE

Not Provided

WEIGHT

15 lbs

INTERPRETED BY

Beth Johnson, DVM
DACVIM

IMAGING PERFORMED BY

Michael Schacher

HOSPITAL NAME

Emergency Vets of
Idaho, LLC

REFERRING VET

Dr. Juli Sorenson

INVOICE

74148

DATE

4/2/26

Pancreas

The pancreas that is observed appears appropriately isoechoic to surrounding omental fat. Visible capsule is smooth and normal in contour. Visible pancreatic parenchyma is homogenous and unremarkable. There is no visible pancreatic duct dilation. There is no evidence of active peripancreatic inflammation.

Free Abdomen

There is no visible free peritoneal effusion noted in these images.

There is no apparent pathologic lymphadenopathy noted in these images.

PRIMARY FINDINGS

- An obvious cause for the subtle liver changes is not identified in these images. Microscopic disease such as Leptospirosis, bacterial cholangiohepatitis, chronic active hepatitis, copper-associated hepatotoxicity, other hepatotoxicity, other reactive hepatopathy, infiltrative neoplasia (considered unlikely), etc. cannot be definitively ruled out.

SECONDARY FINDINGS

- Hyperechoic splenic nodules – most consistent with benign myelolipomas. Other differentials such as fibrosis or calcification caused by old hematomas or infarcts, chronic inflammation, granulomatous disease or metastatic disease cannot be ruled out, but are considered less likely.
- Moderate age related kidney changes with a cortical cyst in the left kidney and pinpoint non-obstructive mineral densities bilaterally.

INTERPRETATION OF THE FINDINGS & FURTHER RECOMMENDATIONS

There is not a definitive ultrasonographically visible intraabdominal explanation for either the patient's reportedly first-time seizures and/or the markedly increased ALT. Regarding the ALT, it can sometimes be a post-ictal finding. Therefore, monitoring may be appropriate, but if the ALT continues to increase and doesn't start to improve, differentials for a primary hepatocellular injury liver enzyme pattern (increased ALT) depend partially on the level of increase. Mild increases (less than 2 times normal) are often a "reactive hepatopathy" or the liver's response to an insult elsewhere in the body including, but not limited to, pancreatitis, gastroenteritis, parasitic disease, dental disease, vacuolar or endocrine hepatopathy from diabetes mellitus or hyperadrenocorticism (steroid-induced), hypoadrenocorticism, certain drugs (e.g. phenobarbital, corticosteroids, azathioprine, etc.), and muscle ALT (more likely if AST and CK concurrently increased).

It is a good indicator of active liver damage (cell membrane disruption, cellular necrosis), however, if the value is increased by at least 3-4 times normal. Differentials include infectious disease, including Leptospirosis, inflammatory disease (ie. active hepatitis, copper, other), toxic insult as well as infiltrative neoplasia.

ALT levels vary in cases of vascular anomalies such as microvascular dysplasia and portosystemic shunts (PSS), but are often less significantly increased.



PATIENT

Hank Sapien

SPECIES

Canine

BREED

Chiweenie

SEX

Neutered Male

AGE

Not Provided

WEIGHT

15 lbs

INTERPRETED BY

Beth Johnson, DVM
DACVIM

IMAGING PERFORMED BY

Michael Schacher

HOSPITAL NAME

Emergency Vets of Idaho, LLC

REFERRING VET

Dr. Juli Sorenson

INVOICE

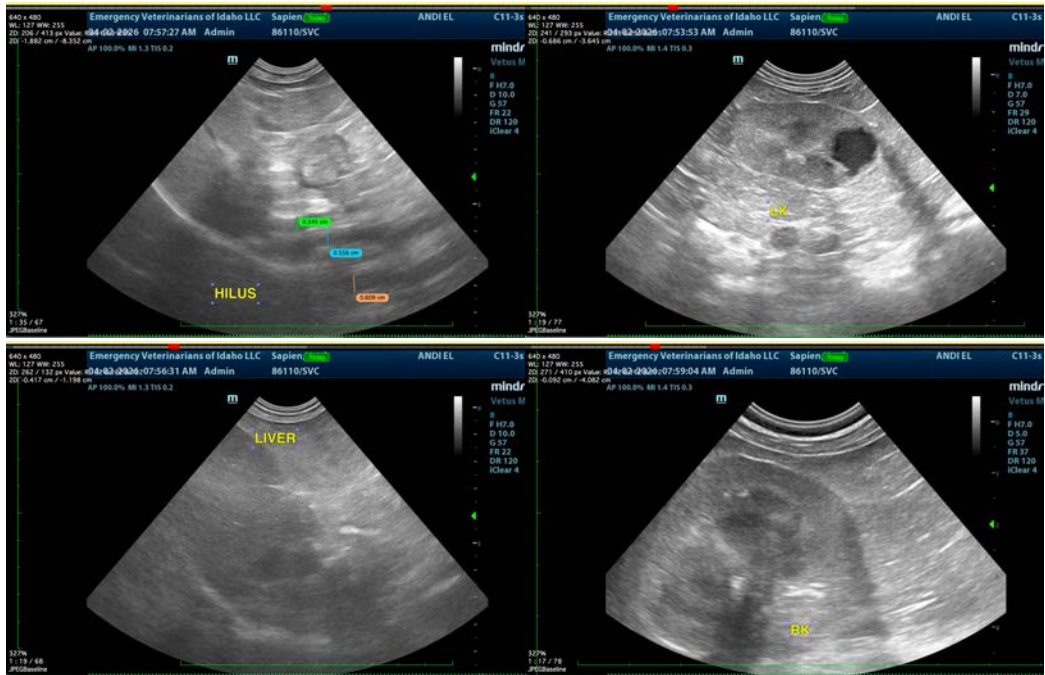
74148

DATE

4/2/26

- Testing for Leptospirosis could be considered.
- Bile acids could be considered, if tbili is not increased.
- An empirical course of antibiotics and empirical hepatic nutraceuticals may be tried, with monitoring of ALT for improvement. If improvement is noted, antibiotics should be continued until liver enzymes either normalize or plateau (recheck every 2-3 weeks); however, if improvement is not noted and/or enzyme increase progresses, antibiotics should not be continued long term and liver tissue sampling is recommended.
- FNA of the liver can be performed to assess inflammatory cell type, rule in/out round cell neoplasia, etc. (if patient's coagulation status is appropriate).
- If round cell neoplasia is not diagnosed, a liver biopsy (including copper level assessment) may be required to definitively diagnose the underlying hepatopathy.

Given the reported seizures, further recommendations are in part dependent on patient's age, but could warrant further investigation by a veterinary neurologist, and/or even advanced imaging.





PATIENT

Hank Sapien

SPECIES

Canine

BREED

Chiweenie

SEX

Neutered Male

AGE

Not Provided

WEIGHT

15 lbs

INTERPRETED BY

Beth Johnson, DVM
DACVIM

IMAGING PERFORMED BY

Michael Schacher

HOSPITAL NAME

Emergency Vets of
Idaho, LLC

REFERRING VET

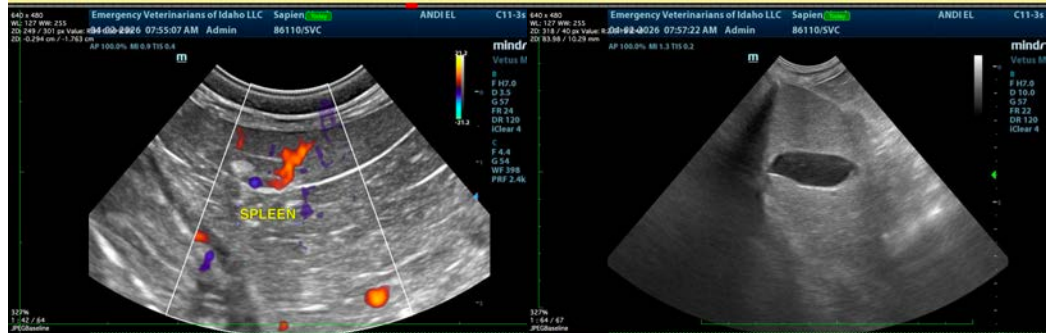Dr. Juli Sorenson

INVOICE

74148

DATE

4/2/26



The information and recommendations provided are based on the images presented by the referring veterinarian/sonographer. No evaluation can be communicated regarding pathology that was not visible in the image/video clips provided.

Thank you for this referral. If the clinical or image interpretation does not parallel your findings or if I can be of any further assistance please contact me.

Beth Johnson, DVM, DACVIM
info@sonopath.com