

**DATE PRESENTING CLINICAL SIGNS**

4/19/23 Lack of appetite, distended abdomen, lethargy, panting.

PATIENT Current Medications: Entyce 30mg/mL 15mL- started 4/15/23.

Riddick Bozzell Date of Previous IntraPet Ultrasound: No previous.

Sedation: Not required to complete full diagnostic ultrasound.

Stat Report: Declined at this time.

Imaging Performed By: Stephanie Warga RDCS, RVT.

SPECIES

Canine

ULTRASONOGRAPHIC EXAMINATION OF THE ABDOMEN**BREED**

Rottweiler

Urinary System

The urinary bladder is moderately distended with anechoic contents. No masses, inflammatory changes, echogenic sediment or cystoliths are observed. The urinary bladder, trigone and visible pelvic urethra are normal in thickness with a smooth mucosal surface.

SEX

Neutered Male

The right kidney is normal in size (8.15 cm), shape and echogenicity. It has smooth peripheral margination. There is a normal 1:3 cortex to medulla ratio with appropriate corticomedullary distinction. There is no evidence of pyelectasia, mineral or infarcts observed.

AGE

7/3/14

The left kidney is normal in size (7.62 cm), shape and echogenicity. It has smooth peripheral margination. There is a normal 1:3 cortex to medulla ratio with appropriate corticomedullary distinction. There is no evidence of pyelectasia, mineral or infarcts observed.

WEIGHT

120 Pounds

Adrenal Glands

The right adrenal gland is normal in size (1.0 cm at the cranial pole and 0.84 cm at the caudal pole), shape and contour. Corticomedullary structure is unremarkable. Visible surrounding vasculature appears normal.

INTERPRETED BY

Beth Johnson, DVM
DACVIM

The left adrenal gland is normal in size (2.8 cm long x 0.52 cm at the cranial pole and 0.55 cm at the caudal pole), shape and contour. Corticomedullary structure is unremarkable. Visible surrounding vasculature appears normal.

HOSPITAL NAME

Mount Airy AH

Spleen

The spleen is subjectively normal in size with a normal smooth capsular contour. Parenchyma is appropriately finely textured and homogenous with normal echogenicity relative to surrounding tissue (hyperechoic to liver). A 3.0 cm x 4.0 cm hypo- to anechoic nodule/mass is noted, resulting in a capsular bulge off of the mid spleen. Splenic vasculature appears normal.

REFERRING VET

Dr. Atchley

Liver

Liver is subjectively markedly enlarged with mildly irregular margins. Parenchyma is mottled by multifocal discrete hypoechoic and slightly heterogeneous nodules of varying sizes "moth-eaten". Visible vasculature and biliary tree appear normal without distension or congestion.

INVOICE

46786

Gallbladder is moderately distended with anechoic bile as well as mild suspended and gravity dependent echogenic debris. The wall is smooth without visible thickening. There is no evidence of cystic or CBD dilation. There is no evidence of effusion or inflammation.

Gastrointestinal

The stomach wall is normal in thickness (canine < 0.5 cm and feline < 0.4 cm) and layering. The lumen of the stomach is empty with no evidence of obstruction, foreign material or infiltrative disease. Pyloric outflow tract appears patent.

The visible small intestines are normal in wall thickness and layering (canine duodenum < 0.5 cm and feline duodenum < 0.4 cm; other < 0.3 cm). Small intestinal motility appears adequate (1-3 contractions per min). The lumen of the small intestine is empty with no evidence of obstruction, foreign material or infiltrative disease.

The visible colon is normal in wall thickness (< 0.2 cm) and layering. Contents are consistent with normal formed feces and gas.

Pancreas

The pancreatic parenchyma is appropriately isoechoic to surrounding tissue. Visible capsule is smooth and normal in contour. There is no visible pancreatic duct dilation. There is no evidence of active peripancreatic inflammation.

Free Abdomen

There is a large amount of anechoic free fluid present in these images.

There is no apparent lymphadenopathy noted in these images.

There is no evidence of heart base or pericardial pathology noted in these images at this time. If cardiac function evaluation is desired a full echocardiogram is recommended.

PRIMARY FINDINGS

- **Nodular Liver** - This finding is concerning for infiltrative disease such as round cell neoplasia or metastatic neoplasia. Benign disease (nodular hyperplasia) cannot be ruled out but is considered less likely.
- **Hypo to anechoic splenic nodule** – can represent a benign lesion such as a cyst, hematoma, nodular hyperplasia, extramedullary hematopoiesis, etc. However, given the marked pathology elsewhere, infiltrative neoplasia is considered more likely.
- Large amount of free abdominal fluid

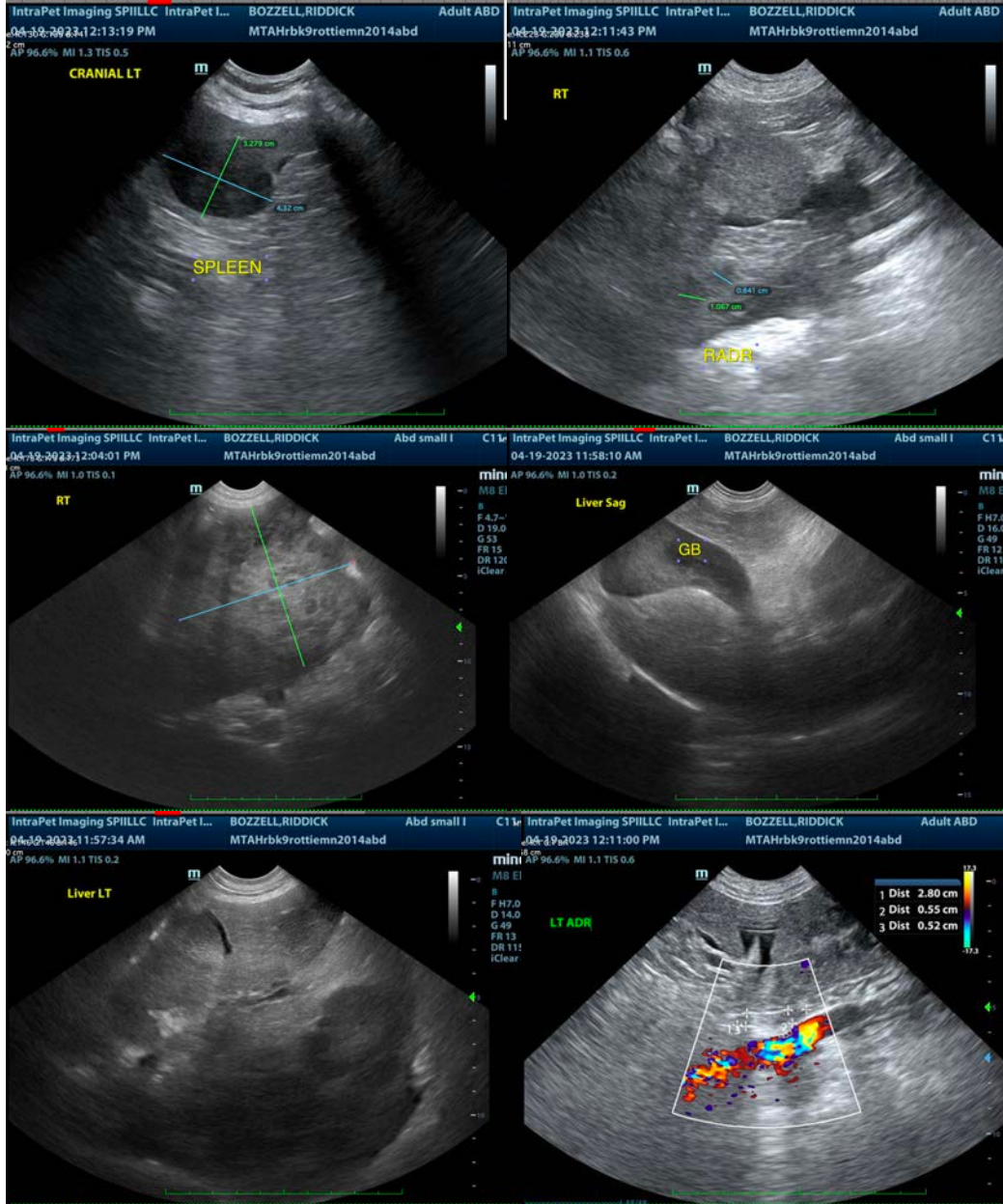
SECONDARY FINDINGS

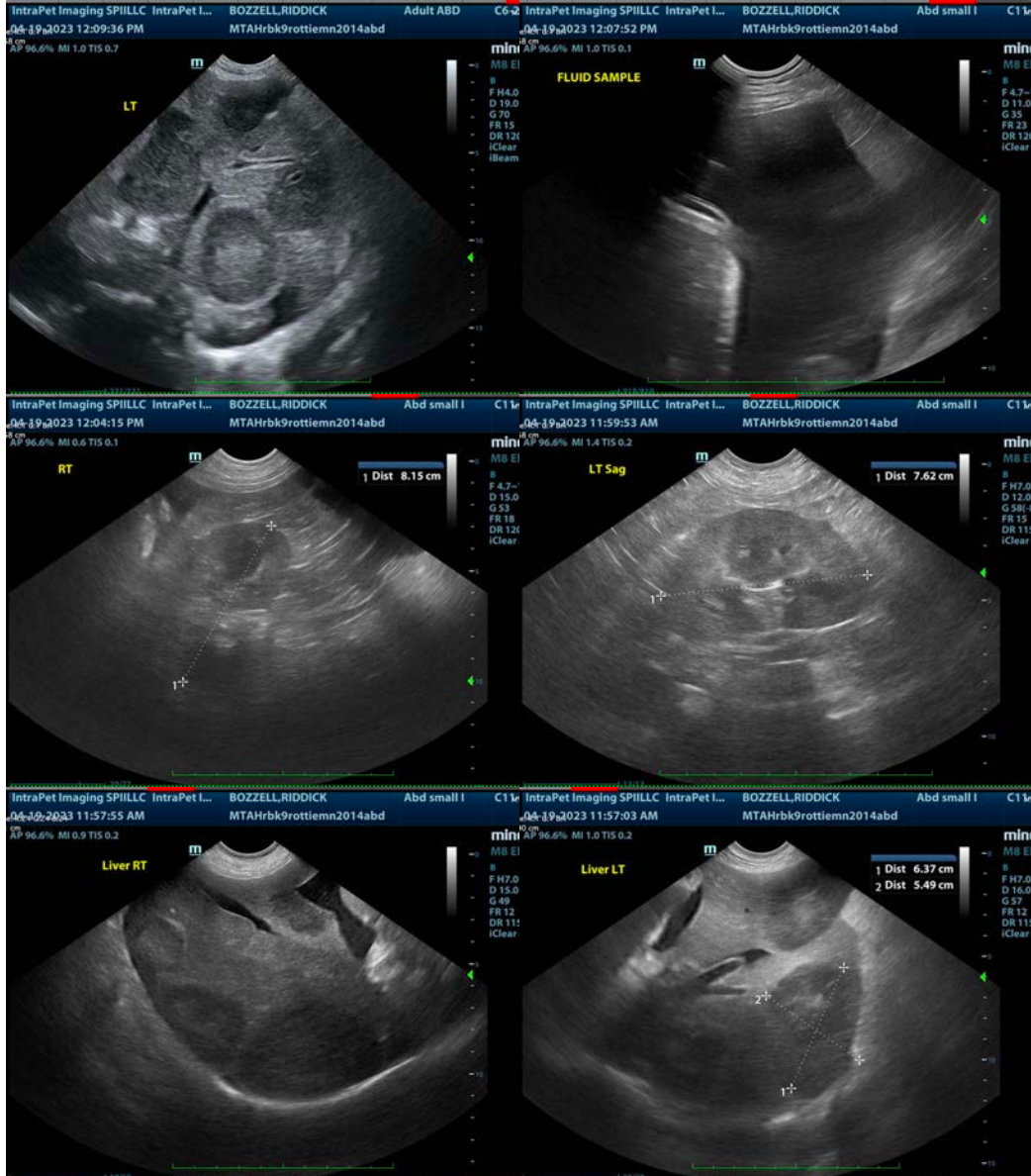
- **Mild gallbladder debris** - Cholecystic debris is of unknown clinical significance. It can be seen with biliary stasis from fasting or illness. Cholecystic debris is not necessarily related to hepatobiliary disease. Echogenic bile is most commonly an incidental finding in dogs and should be interpreted in combination with clinical signs such as nausea, inappetence, cranial abdominal discomfort and/or laboratory changes such as increased ALP and/or increased Tbili.

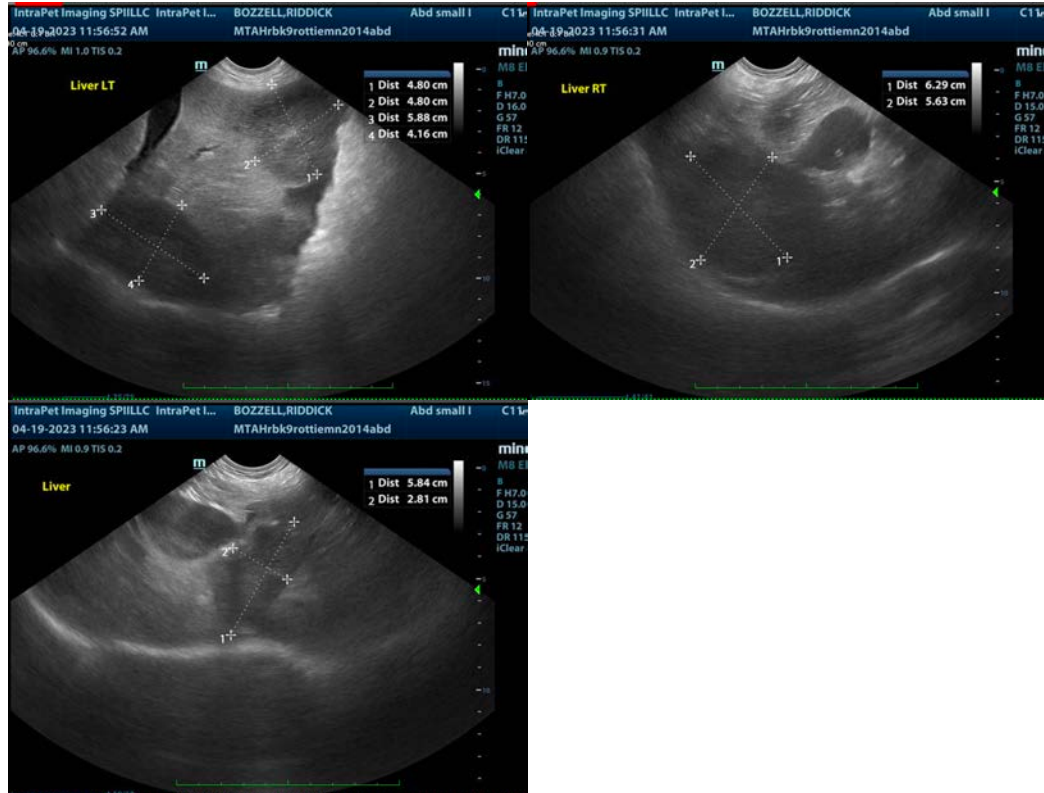
INTERPRETATION OF THE FINDINGS & FURTHER RECOMMENDATIONS

Three view thoracic radiographs are recommended for further assessment of cardio-pulmonary status as well as to further evaluate for any evidence of metastatic disease, if not recently evaluated.

While, if this is a hemoabdomen, an exploratory laparotomy to find, remove/stop the bleed may ultimately be necessary, the visible pathology is diffuse and not completely surgically resectable. Therefore, if possible, and if patient is stable and patient's coagulation status is appropriate, recommendations are to begin with fine needle aspirates of the liver nodules +/- the spleen.







The information and recommendations provided are based on the images presented by the referring veterinarian/sonographer. No evaluation can be communicated regarding pathology that was not visible in the image/video clips provided.

Thank you for this referral. If the clinical or image interpretation does not parallel your findings or if I can be of any further assistance please contact me.

Beth Johnson, DVM, DACVIM
Beth.Johnson@sonopath.com