

**DATE PRESENTING CLINICAL SIGNS**

4/19/23 Not eating well for several months and has gotten to where has not eaten very much at all past 5 days, also just noticed hematuria past day. Patient also has mild asthma/sinus congestion and is on medications for this.

PATIENT

Nyla Whatmough

Current Medications: Prednisolone 5mg EOD.

Lab Results: WNL.

Radiographs: WNL.

SPECIES

Feline

Date of Previous IntraPet Ultrasound: No previous.

Sedation: Not required to complete full diagnostic ultrasound.

Stat Report: Not requested.

Imaging Performed By: Stephanie Warga RDCS, RVT.

BREED

DSH

ULTRASONOGRAPHIC EXAMINATION OF THE ABDOMEN**SEX**

Spayed Female

Urinary System

Urinary bladder is adequately distended. It has a normal uniform wall thickness. Contents include primarily anechoic fluid with a large amount of echogenic non-shadowing debris, which could partially be incidental suspended lipid in a cat. However, given the marked debris, it is most likely combined with exfoliated cells, mucous and/or small blood clots, etc. Both sterile inflammation as well as urinary tract infection can also present with echogenic debris. No masses or cystoliths are observed. The trigone and visible pelvic urethra are normal in thickness with a smooth mucosal surface.

AGE

4/15/20

WEIGHT

13.7 Pounds

The kidneys are significantly enlarged in size. The left kidney measured 4.75 cm. The right kidney measures 5.2 cm. Overall increased echogenicity noted and mild decrease in corticomedullary distinction. Both kidneys demonstrate a mildly irregular shape, and both have evidence of scant suspected subcapsular free fluid, although perinephric free fluid can't be definitively rule out. Both kidneys are surrounded by enhanced hyperechoic mesenteric fat.

INTERPRETED BYBeth Johnson, DVM
DACVIM**Adrenal Glands**

The right adrenal gland is normal in size (0.41 cm), shape and contour. Corticomedullary structure is unremarkable. Visible surrounding vasculature appears normal.

HOSPITAL NAMEPleasantville AH of
Fallston

The left adrenal gland is normal in size (0.39 cm), shape and contour. Corticomedullary structure is unremarkable. Visible surrounding vasculature appears normal.

Spleen

The spleen is subjectively normal in size with a normal smooth capsular contour. Parenchyma is appropriately finely textured and homogenous with normal echogenicity relative to surrounding tissue (hyperechoic to liver). No focal nodules or masses are observed. Splenic vasculature appears normal.

REFERRING VET

Dr. Gounaris

Liver

The liver is subjectively normal in size with normal smooth curvilinear peripheral contour. Parenchyma is appropriately hypoechoic to the spleen in echogenicity and appropriately mildly coarse and homogenous in echotexture. No focal lesions are observed. Visible vasculature and biliary tree appear normal without distension or congestion.

INVOICE

46789

The gallbladder is non-distended in size. The wall is smooth without visible thickening. Luminal contents are primarily anechoic. There is no evidence of cystic or common bile duct dilation.

Gastrointestinal

The visible stomach wall is normal in thickness and layering. The stomach is mildly distended and contains an echogenic interface with distal progressively shadowing material consistent with hairball density (or similar fluid absorbing material) noted. Normal ingesta/gas can have a similar appearance, and this finding should be interpreted in combination with supporting clinical signs and/or improvement versus progression, etc.

The visible small intestine demonstrates areas of thick muscularis layer relative to mucosa (disruption of the normal 1:3 muscularis:mucosa ratio). Small intestinal submucosa is slightly irregular, thick and hyperechoic, without evident loss of layering appreciated. The lumen is empty with no evidence of obstruction or foreign material.

The colon is diffusely thick, measuring 0.38 cm thick with normal intact layering but a predominantly thick submucosa layer. Contents are consistent with normal formed feces and gas.

Pancreas

The observed pancreas appears appropriately isoechoic to surrounding omental fat. The capsule is mildly irregular in shape. Parenchyma is mildly heterogenous and coarse. There is no visible pancreatic duct dilation. There is no evidence of active peripancreatic inflammation.

Free Abdomen

There is no evidence of free peritoneal effusion noted in these images.

There is no apparent lymphadenopathy noted in these images.

**See above kidney description.

PRIMARY FINDINGS

- **Bilateral renomegaly with evidence of bilateral perinephric inflammation and suspect scant subcapsular free fluid** – These are all characteristics that can appear with renal lymphoma. Having said that, it is not a pathognomonic change, and severe nephritis, pyelonephritis, feline infectious peritonitis, toxic renal insult, etc. can mimic this presentation and can't be differentiated without additional information.
- Large amount of urinary bladder debris
- **Inflammatory bowel disease (IBD) pattern** – Thick muscularis has been reported with infiltrative bowel disease including both benign inflammatory disease as well as infiltrative neoplasia such as lymphoma. No aggressive lymphadenopathy, loss of layering, etc. is noted to make lymphoma more probable, but lymphoma cannot be definitively ruled out without tissue sampling.
- **Diffusely thick colon** – Likely the same underlying etiology as described for the small bowel.
- A gastric hairball or other similar appearing foreign material is possible based on these images. Having said that, full interpretation depends on clinical signs, last meal, etc., and this finding can occur with normal ingesta and gas and should be interpreted in combination with supporting clinical signs and/or changes over time.

ULTRASONOGRAPHIC FINDINGS

- **Pancreatic age-related remodeling** – Mild irregularities are consistent with benign age-related change. Low-grade smoldering chronic pancreatitis cannot be ruled out and should be suspected in the face of appropriate clinical signs.

INTERPRETATION OF THE FINDINGS & FURTHER RECOMMENDATIONS

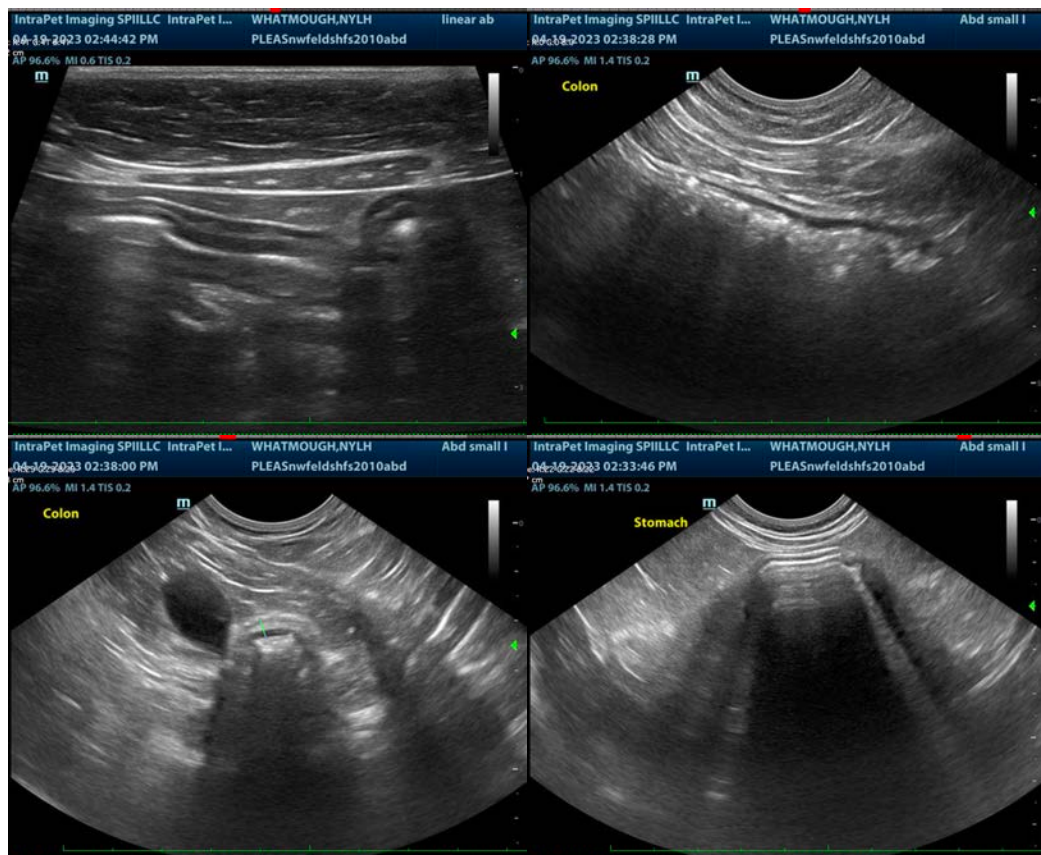
If not recently evaluated, a urinalysis and, if indicated based on urinalysis results, urine culture are recommended. If protein is present in an otherwise quiet sediment, protein quantification with a urine protein to creatinine ration is recommended.

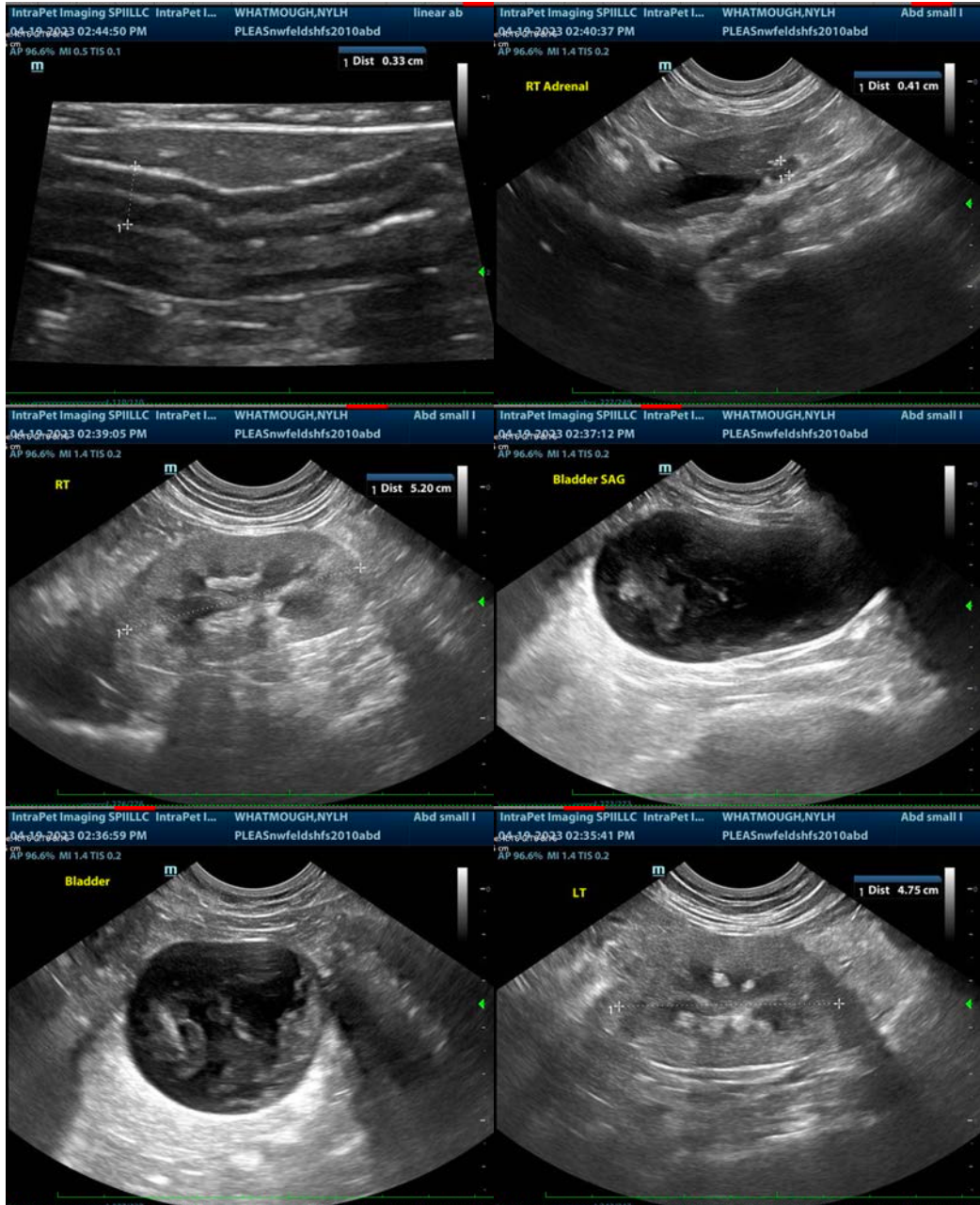
A fine needle aspirate of the kidneys, especially the right kidney, could be considered if patient's coagulation status is appropriate.

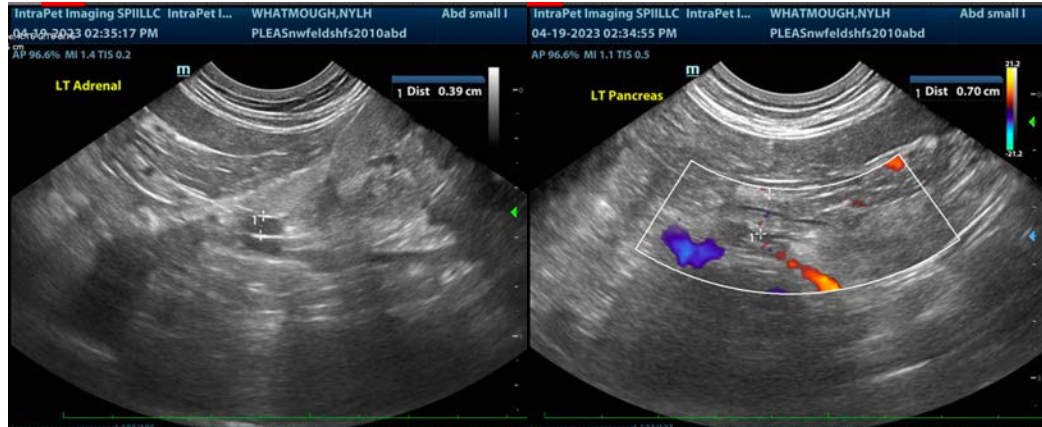
A gastrointestinal malabsorption panel (including cobalamin, folate, TLI and PLI) to Texas A&M GI Laboratory is recommended for further evaluation of GI and pancreatic function.

Ideally, biopsies of the GI tract, being sure to include ileum if possible, are recommended to definitively diagnose and therefore manage the infiltrative bowel disease.

If biopsies cannot be obtained, empirical therapies could include diet change, empirical deworming with a 5 day course of Panacur, cobalamin supplementation (unless cobalamin level is evaluated and supplementation is not warranted) and prednisolone (if not contraindicated based on patient contraindications, co-morbidities, etc.). Other supportive therapeutic considerations could include fiber supplementation, especially with large bowel diarrhea and/or a probiotic.







The information and recommendations provided are based on the images presented by the referring veterinarian/sonographer. No evaluation can be communicated regarding pathology that was not visible in the image/video clips provided.

Thank you for this referral. If the clinical or image interpretation does not parallel your findings or if I can be of any further assistance please contact me.

Beth Johnson, DVM, DACVIM
Beth.Johnson@sonopath.com