



PATIENT	PRESENTING CLINICAL SIGNS
Eevee Salameh	Elevation of liver enzymes during senior screen.
SPECIES	Abnormal PE/Chem/CBC/UA Results: CBC: Platelets 521 148 - 484 x10 ⁹ /L Biochemistry : Urea (BUN) 10.9 2.5 - 9.6 mmol/L Total Protein 85 52 - 82 g/L Albumin 42 23 - 40 g/L ALT 206 10 - 125 U/L Bilirubin - Total 41 0 - 15 µmol/L
Canine	
BREED	ULTRASONOGRAPHIC EXAMINATION OF THE ABDOMEN
Yorkshire Terrier X	Urinary System
SEX	Urinary bladder is adequately distended with primarily anechoic contents and occasional echogenic non-shadowing debris. Additionally, there is a large amount of mineral/sand debris and suspected conglomerated small cystoliths. Apical urinary bladder wall is diffusely thick (0.38 cm). Mucosa is hyperechoic and irregular. No masses or cystoliths are observed. The trigone and visible pelvic urethra are normal thickness with a smooth mucosal surface.
Spayed Female	
AGE	The right kidney is normal in size (cm), shape and echogenicity. It has smooth peripheral margination. There is a normal 1:3 cortex to medulla ratio with appropriate corticomedullary distinction. There is no evidence of pyelectasia, mineral or infarcts observed.
7 Years 8 Months	
WEIGHT	The left kidney is normal in size (cm), shape and echogenicity. It has smooth peripheral margination. There is a normal 1:3 cortex to medulla ratio with appropriate corticomedullary distinction. There is no evidence of pyelectasia, mineral or infarcts observed.
4.1 kg	
INTERPRETED BY	Adrenal Glands
Beth Johnson, DVM DACVIM	The right adrenal gland is normal in size (measurement), shape and contour. Corticomedullary structure is unremarkable. Visible surrounding vasculature appears normal.
IMAGING PERFORMED BY	The left adrenal gland is normal in size (measurement), shape and contour. Corticomedullary structure is unremarkable. Visible surrounding vasculature appears normal.
Dr. Gira	
HOSPITAL NAME	Spleen
Sabadilla AC	Spleen is subjectively normal in size with a normal smooth capsular contour. Parenchyma is appropriately finely textured and homogenous with normal echogenicity relative to surrounding tissue (hyperechoic to liver). Multifocal well-demarcated hyperechoic homogenous nodules are noted. Splenic vasculature appears normal.
REFERRING VET	Liver
Dr. Chmielinski	Liver is subjectively enlarged with mildly irregular margins. Parenchyma is heterogenous characterized by multiple poorly defined hypoechoic nodules within otherwise hyperechoic liver parenchyma. Additionally, there are multifocal discrete small hyperechoic nodules throughout the parenchyma. Visible vasculature and biliary tree appear normal without distension or congestion. Portal vein to caudal vena cava ratio is an appropriate 1:1.
INVOICE	
46764	
DATE	Gallbladder is moderately distended with anechoic bile as well as moderate suspended and gravity dependent echogenic debris. The wall is smooth without visible thickening. There is no evidence of cystic or CBD dilation. There is no evidence of effusion or inflammation.
4/19/23	



PATIENT	Gastrointestinal
Eevee Salameh	The stomach wall is normal in thickness (canine < 0.5 cm and feline < 0.4 cm) and layering. The lumen of the stomach is empty with no evidence of obstruction, foreign material or infiltrative disease. Pyloric outflow tract appears patent.
SPECIES	
Canine	The visible small intestines are normal in wall thickness and layering (canine duodenum < 0.5 cm and feline duodenum < 0.4 cm; other < 0.3 cm). Small intestinal motility appears adequate (1-3 contractions per min). The lumen of the small intestine is empty with no evidence of obstruction, foreign material or infiltrative disease.
BREED	
Yorkshire Terrier X	The visible colon is normal in wall thickness (< 0.2 cm) and layering. Contents are consistent with normal formed feces and gas.
SEX	
Spayed Female	Pancreas
AGE	The pancreatic parenchyma is appropriately isoechoic to surrounding tissue. Visible capsule is smooth and normal in contour. There is no visible pancreatic duct dilation. There is no evidence of active peripancreatic inflammation.
7 Years 8 Months	
WEIGHT	Free Abdomen
4.1 kg	There is no evidence of free peritoneal effusion noted in these images.
INTERPRETED BY	The sublumbar and mesenteric lymph nodes are prominent in size with swollen capsular contour. Normal elongated shape (length to width ratio) is maintained. There is no loss of parenchymal detail.
Beth Johnson, DVM DACVIM	PRIMARY FINDINGS
IMAGING PERFORMED BY	<ul style="list-style-type: none"> • Heterogenous Liver – These changes are most consistent with benign processes such as nodular hyperplasia, steroid (vacuolar) hepatopathy, extramedullary hematopoiesis or possibly chronic inflammatory disease and less commonly infiltrative round cell or metastatic neoplasia. • Liver nodules – Differentials for discrete liver nodules include primarily benign changes such as nodular hyperplasia, fibrosis of an old hematoma, granuloma, myelolipoma, etc.; however, while considered less likely, primary hepatic neoplasia, infiltrative round cell neoplasia and metastatic disease can mimic benign lesions and cannot be definitively ruled out. • Moderate gallbladder debris - Cholecystic debris is of unknown clinical significance. It can be seen with biliary stasis from fasting or illness. Cholecystic debris is not necessarily related to hepatobiliary disease. Echogenic bile is most commonly an incidental finding in dogs and should be interpreted in combination with clinical signs such as nausea, inappetence, cranial abdominal discomfort and/or laboratory changes such as increased ALP and/or increased Tbili. • Chronic Cystitis with a large amount of mineral/sand debris and small cystoliths suspected - Urinary bladder wall changes are most consistent with chronic cystitis. Infiltrative neoplasia cannot be ruled out but is considered less likely give the location and diffuse nature of the changes. • Reactive sublumbar and mesenteric lymph nodes – infiltrative neoplastic disease cannot be ruled out but is considered less likely.
Dr. Gira	
HOSPITAL NAME	
Sabadilla AC	
REFERRING VET	
Dr. Chmielinski	
INVOICE	
46764	
DATE	
4/19/23	



PATIENT

Eevee Salameh

SPECIES

Canine

BREED

Yorkshire Terrier X

SEX

Spayed Female

AGE

7 Years 8 Months

WEIGHT

4.1 kg

INTERPRETED BY

Beth Johnson, DVM
DACVIM

IMAGING PERFORMED BY

Dr. Gira

HOSPITAL NAME

Sabadilla AC

REFERRING VET

Dr. Chmielinski

INVOICE

46764

DATE

4/19/23

SECONDARY FINDINGS

- **Hyperechoic splenic nodules** – most consistent with benign myelolipomas. Other differentials such as fibrosis or calcification caused by old hematomas or infarcts, chronic inflammation, granulomatous disease or metastatic disease cannot be ruled out, but are considered less likely.

INTERPRETATION OF THE FINDINGS & FURTHER RECOMMENDATIONS

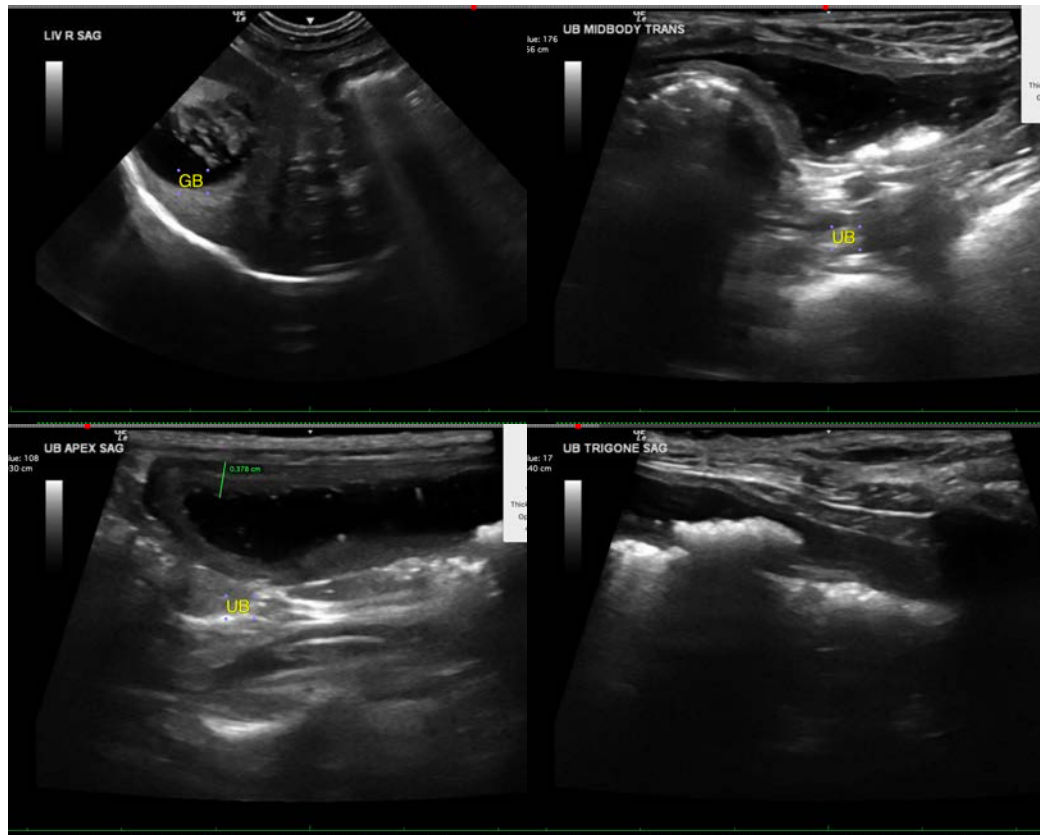
The majority of the pathology above trends in appearance toward benign. However, given the progressively increasing liver enzymes, further evaluation is recommended, beginning with testing for Leptospirosis as well as a fine needle aspirate of the liver if patient's coagulation status is appropriate.

In the meantime, if Ursodiol has not been included with the reported hepatic nutraceuticals, Ursodiol therapy could be considered.

Additionally, ruling out hemolysis of the sample contributing to the newly increased bilirubin is recommended.

Regarding the urinary bladder mineral, analysis of the type of mineral is important to help determine treatment/prevention. Therefore, a urinalysis and, if indicated based on urinalysis results, urine culture are recommended. If protein is present in an otherwise quiet sediment, protein quantification with a urine protein to creatinine ratio is recommended.

Pending results of urinalysis, retrieval of some of the mineral debris via a sedated or anesthetized bladder flush or voiding urohydropropulsion could potentially be considered.





PATIENT

Eevee Salameh

SPECIES

Canine

BREED

Yorkshire Terrier X

SEX

Spayed Female

AGE

7 Years 8 Months

WEIGHT

4.1 kg

INTERPRETED BY

Beth Johnson, DVM
DACVIM

IMAGING PERFORMED BY

Dr. Gira

HOSPITAL NAME

Sabadilla AC

REFERRING VET

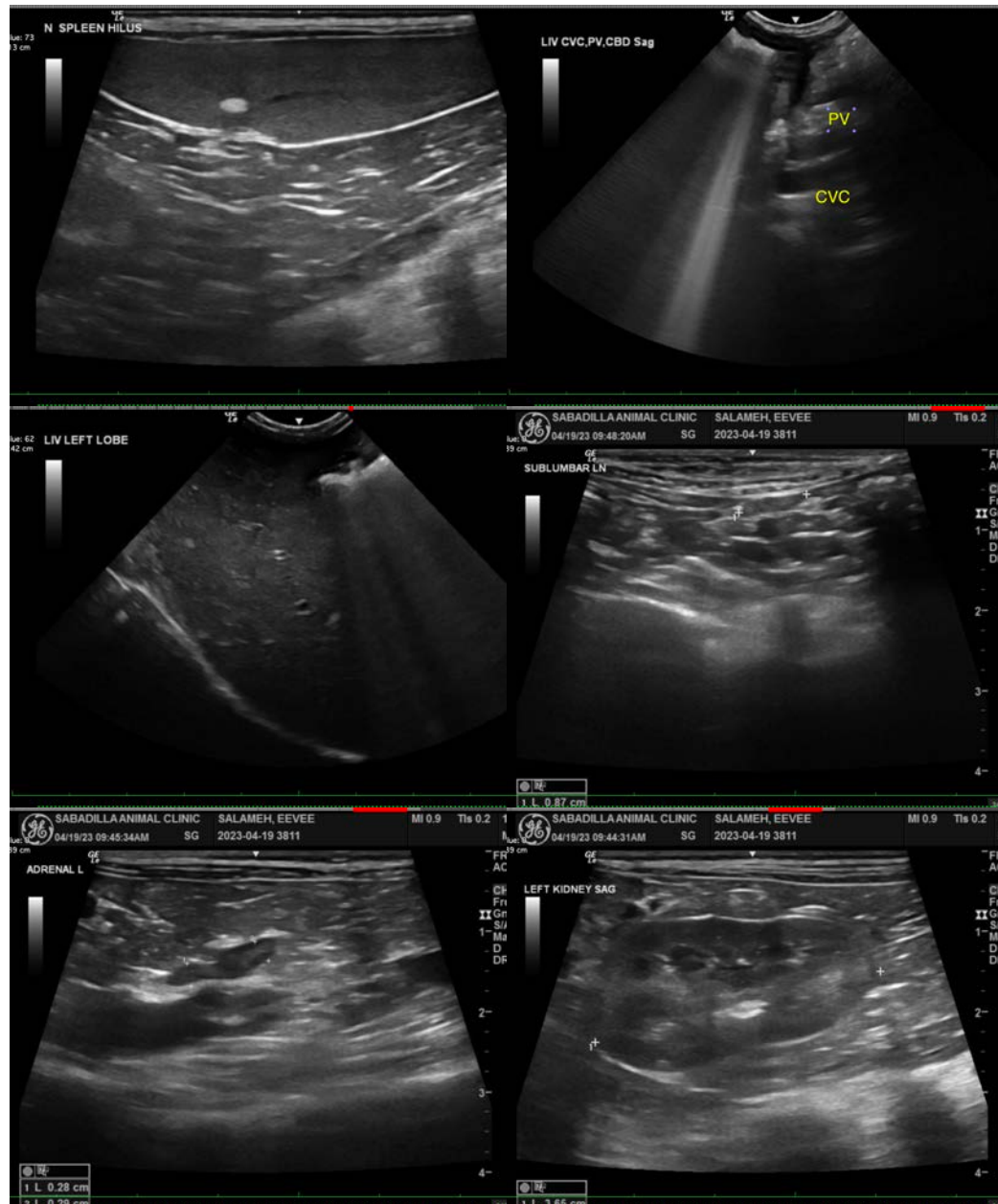
Dr. Chmielinski

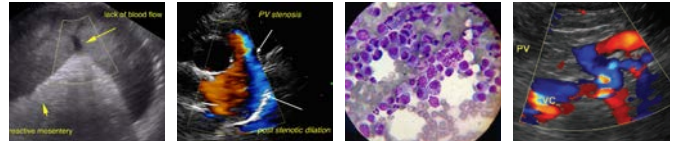
INVOICE

46764

DATE

4/19/23





PATIENT

Eevee Salameh

SPECIES

Canine

BREED

Yorkshire Terrier X

SEX

Spayed Female

AGE

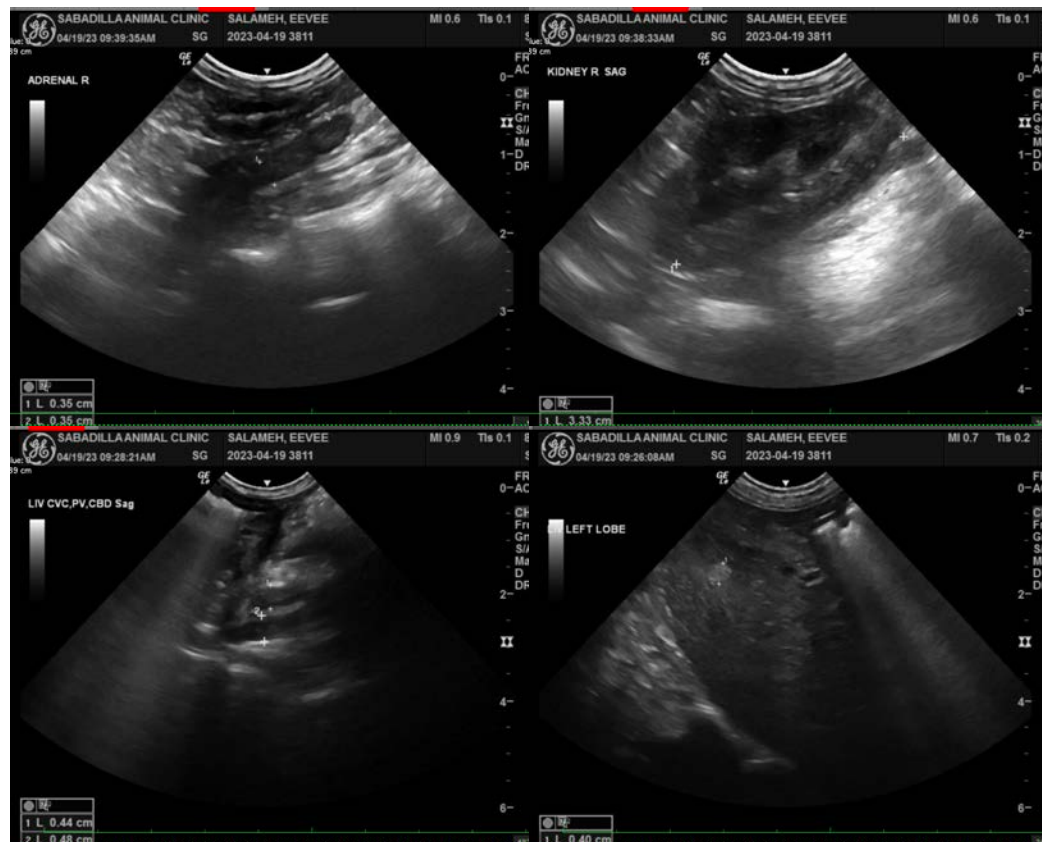
7 Years 8 Months

WEIGHT

4.1 kg

INTERPRETED BY

Beth Johnson, DVM
DACVIM



IMAGING PERFORMED BY

Dr. Gira

HOSPITAL NAME

Sabadilla AC

REFERRING VET

Dr. Chmielinski

INVOICE

46764

DATE

4/19/23

The information and recommendations provided are based on the images presented by the referring veterinarian/sonographer. No evaluation can be communicated regarding pathology that was not visible in the image/video clips provided.

Thank you for this referral. If the clinical or image interpretation does not parallel your findings or if I can be of any further assistance please contact me.

Beth Johnson, DVM, DACVIM
Beth.Johnson@sonopath.com