

**DATE PRESENTING CLINICAL SIGNS**

4/18/23 Presented for glaucoma that was unable to resolve with medical management. Performed bloodwork prior to enucleation and noted increased liver values. Abdominal x-rays showed large mass in the right cranial abdomen.

PATIENT

Sammie O'Shea Current Medications: Cefpodoxime 200mg SID, Gabapentin 600mg ½ BID, Deramaxx 100mg ½ SID.

Date of Previous IntraPet Ultrasound: No previous.

Sedation: Not required to complete full diagnostic ultrasound.

SPECIES

Stat Report: Not requested.

Canine

Imaging Performed By: Andi Parkinson, BS, RDMS.

BREED**ULTRASONOGRAPHIC EXAMINATION OF THE ABDOMEN**

Hound X

Urinary System

The urinary bladder is moderately distended with anechoic contents. No masses, inflammatory changes, echogenic sediment or cystoliths are observed. The urinary bladder, trigone and visible pelvic urethra are normal in thickness with a smooth mucosal surface.

SEX

Spayed Female

The right kidney is normal in size (6.52 cm), shape and echogenicity. It has smooth peripheral margination. There is a normal 1:3 cortex to medulla ratio with appropriate corticomedullary distinction. There is no evidence of pyelectasia, mineral or infarcts observed.

AGE

5/6/13

The left kidney is normal in size (6.31 cm), shape and echogenicity. It has smooth peripheral margination. There is a normal 1:3 cortex to medulla ratio with appropriate corticomedullary distinction. There is no evidence of pyelectasia, mineral or infarcts observed.

WEIGHT

64.7 Pounds

Adrenal Glands**INTERPRETED BY**

The right adrenal gland is normal in size (2.72 cm long x 1.06 cm at the cranial pole and 0.70 cm at the caudal pole), shape and contour. Corticomedullary structure is unremarkable. Visible surrounding vasculature appears normal.

Beth Johnson, DVM
DACVIM

HOSPITAL NAME

The left adrenal gland is normal in size (2.71 cm long x 1.02 cm at the cranial pole and 0.90 cm at the caudal pole), shape and contour. Corticomedullary structure is unremarkable. Visible surrounding vasculature appears normal.

Timonium AH

REFERRING VET**Spleen**

The spleen is subjectively normal in size with a normal smooth capsular contour. Parenchyma is appropriately finely textured and homogenous with normal echogenicity relative to surrounding tissue (hyperechoic to liver). No focal nodules or masses are observed. Splenic vasculature appears normal.

Dr. Lentz

INVOICE**Liver**

The liver is subjectively normal in size with normal smooth curvilinear peripheral contour. Parenchyma is appropriately hypoechoic to the spleen in echogenicity and appropriately mildly coarse and homogenous in echotexture. In the right caudal liver, there is an approximately 9.0 cm x 10 cm enlarged, rounded, partially heterogeneous, primarily isoechoic, non-cystic, non-cavitated mass-like lesion with some multifocal hyperechoic areas/nodules within it. Visible vasculature and biliary tree appear normal without distension or congestion.

46739

Gallbladder is moderately distended with anechoic bile as well as mild suspended and gravity dependent echogenic debris. The wall is smooth without visible thickening. There is no evidence of cystic or CBD dilation. There is no evidence of effusion or inflammation.

Gastrointestinal

The visible stomach wall is normal in thickness and layering. The lumen of the stomach is mildly distended with very echogenic reverberation artifact from intraluminal gas. There is no evidence of obstruction, foreign material or infiltrative disease; however, complete visualization of far wall is partially inhibited by gas. Pyloric outflow tract appears patent.

The visible small intestines are normal in wall thickness and layering (canine duodenum < 0.5 cm and feline duodenum < 0.4 cm; other < 0.3 cm). Small intestinal motility appears adequate (1-3 contractions per min). The lumen of the small intestine is empty with no evidence of obstruction, foreign material or infiltrative disease.

The visible colon is normal in wall thickness (< 0.2 cm) and layering. Contents are consistent with normal formed feces and gas.

Pancreas

The pancreatic parenchyma is appropriately isoechoic to surrounding tissue. Visible capsule is smooth and normal in contour. There is no visible pancreatic duct dilation. There is no evidence of active peripancreatic inflammation.

Free Abdomen

There is no evidence of free peritoneal effusion noted in these images.

There is no apparent lymphadenopathy noted in these images.

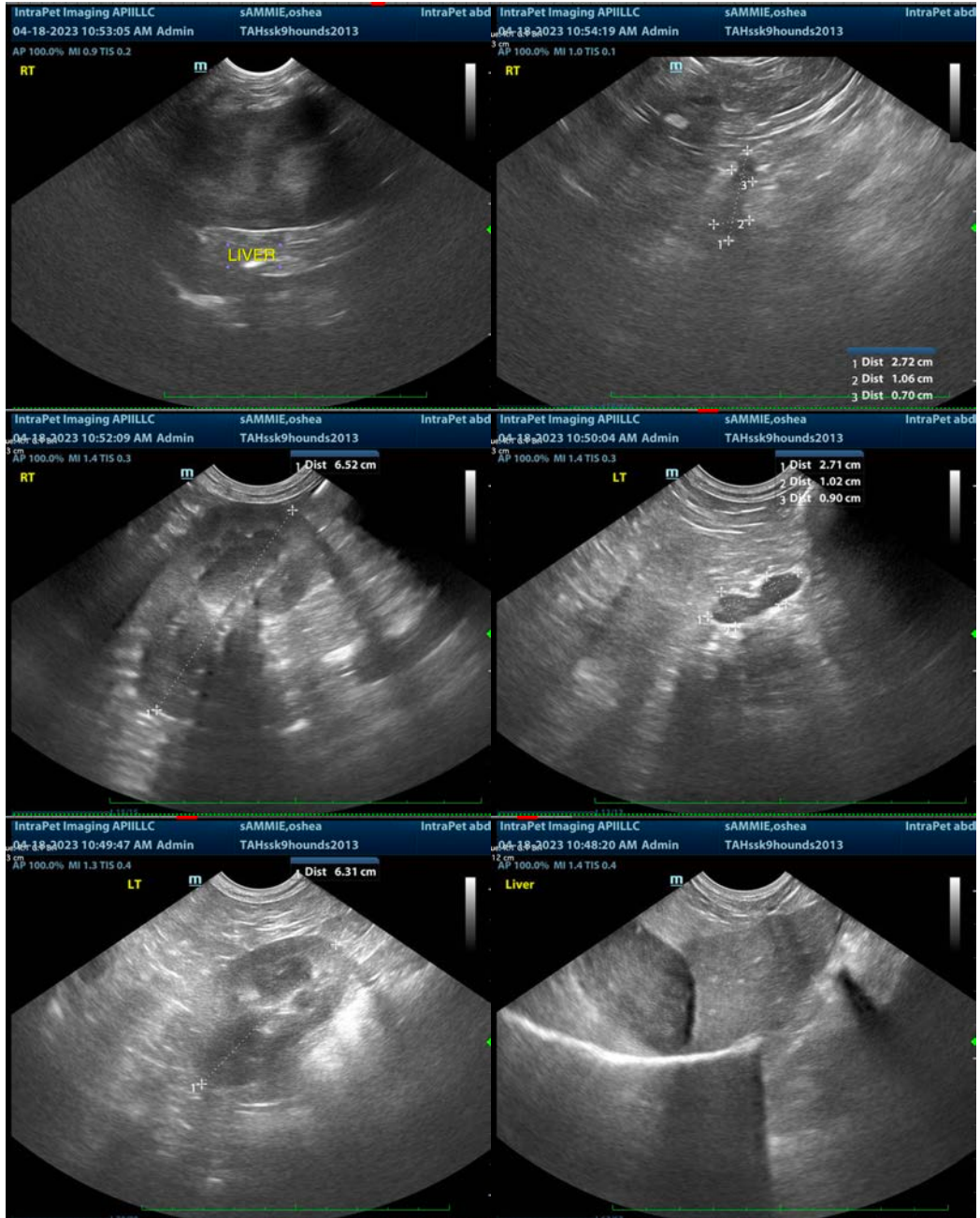
ULTRASONOGRAPHIC FINDINGS

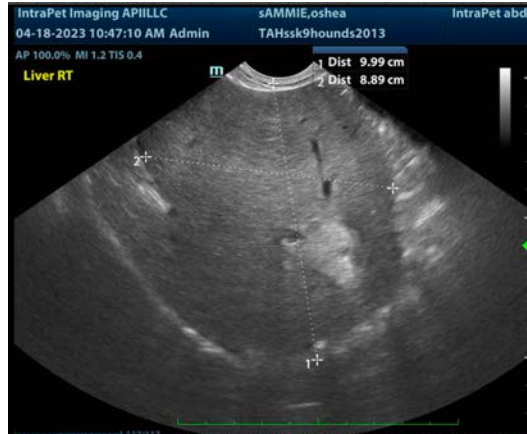- **Caudal right, mildly heterogeneous, isoechoic liver mass** – This trends in appearance toward benign, as can be seen with marked vacuolar hepatopathy or nodular hyperplasia, or even an adenoma/hepatoma, etc. However, infiltrative neoplasia including round cell neoplasia, primary hepatocellular carcinoma, etc. are possible, and can't be differentiated without tissue sampling.
- **Mild gallbladder debris** - Cholecystic debris is of unknown clinical significance. It can be seen with biliary stasis from fasting or illness. Cholecystic debris is not necessarily related to hepatobiliary disease. Echogenic bile is most commonly an incidental finding in dogs and should be interpreted in combination with clinical signs such as nausea, inappetence, cranial abdominal discomfort and/or laboratory changes such as increased ALP and/or increased Tbili.

INTERPRETATION OF THE FINDINGS & FURTHER RECOMMENDATIONS

Three view thoracic radiographs are recommended for further assessment of cardio-pulmonary status as well as to further evaluate for any evidence of metastatic disease, if not recently evaluated.

As was visibly performed in these images, a fine needle aspirate of the enlarged right liver/liver mass is recommended if patient's coagulation status is appropriate.





The information and recommendations provided are based on the images presented by the referring veterinarian/sonographer. No evaluation can be communicated regarding pathology that was not visible in the image/video clips provided.

Thank you for this referral. If the clinical or image interpretation does not parallel your findings or if I can be of any further assistance please contact me.

Beth Johnson, DVM, DACVIM
Beth.Johnson@sonopath.com