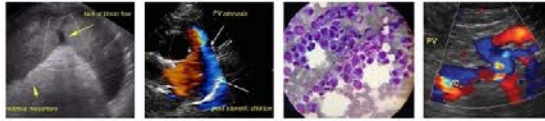


PATIENT	PRESENTING CLINICAL SIGNS
Percy Gain	Low grade pyrexia, generalized Lymphadenopathy, dental calculus. Patient has not been on any parasite protection. Not acting himself, quiet and decreased appetite. Gave Cerenia and Convenia. Has been on Furosemide 10mg daily since Sept 2021.
SPECIES	
Canine	Abnormal PE/Chem/CBC/UA Results: Rads suggestive of splenomegaly and cardiomegaly. HCT, HGB, MCV, Retic-HBG, Platelets, PCT all low. MPV high. SDMA elevated at 21. T4 normal. Snap CPL abnormal.
BREED	
Cavalier King Charles Spaniel	
SEX	ULTRASONOGRAPHIC EXAMINATION OF THE ABDOMEN
Neutered Male	Urinary System
AGE	The urinary bladder is moderately distended with anechoic contents. No masses, inflammatory changes, echogenic sediment or cystoliths are observed. The urinary bladder, trigone and visible pelvic urethra are normal in thickness with a smooth mucosal surface.
10 Years	The right kidney is normal in size (5.38 cm), shape and echogenicity. It has smooth peripheral margination. There is a normal 1:3 cortex to medulla ratio with appropriate corticomedullary distinction. There is no evidence of pyelectasia, mineral or infarcts observed.
WEIGHT	The left kidney is normal in size (4.39 cm), shape and echogenicity. It has smooth peripheral margination. There is a normal 1:3 cortex to medulla ratio with appropriate corticomedullary distinction. There is no evidence of pyelectasia, mineral or infarcts observed.
10 kg	
INTERPRETED BY	Adrenal Glands
Beth Johnson, DVM DACVIM	The right adrenal gland is normal in size (1.32 cm long x 1.3 cm at the cranial pole and 0.74 cm at the caudal pole), shape and contour. Corticomedullary structure is unremarkable. Visible surrounding vasculature appears normal.
IMAGING PERFORMED BY	The left adrenal gland is normal in size (1.73 cm long x 0.58 cm at the cranial pole and 0.53 cm at the caudal pole), shape and contour. Corticomedullary structure is unremarkable. Visible surrounding vasculature appears normal.
Crystal Hill	
HOSPITAL NAME	Spleen
Acton Vet Clinic	Spleen is subjectively large in size with subtly scalloped or undulating capsular contour. Parenchyma is normal in echogenicity with a mildly coarse/heterogenous echotexture. No focal nodules or masses are observed. Splenic vasculature appears normal.
REFERRING VET	Liver
Dr. Hess	The liver is subjectively normal in size with normal smooth curvilinear peripheral contour. Parenchyma is appropriately hypoechoic to the spleen in echogenicity and appropriately mildly coarse and homogenous in echotexture. No focal lesions are observed. Visible vasculature and biliary tree appear normal without distension or congestion.
INVOICE	
46723	
DATE	
4/18/23	The gallbladder is non-distended in size. The wall is smooth without visible thickening. Luminal contents are primarily anechoic. There is no evidence of cystic or common bile duct dilation.



PATIENT *Gastrointestinal*

Percy Gain The stomach wall is normal in thickness (canine < 0.5 cm and feline < 0.4 cm) and layering. The lumen of the stomach is empty with no evidence of obstruction, foreign material or infiltrative disease. Pyloric outflow tract appears patent.

SPECIES

Canine

The visible small intestines are normal in wall thickness and layering (canine duodenum < 0.5 cm and feline duodenum < 0.4 cm; other < 0.3 cm). Small intestinal motility appears adequate (1-3 contractions per min). The lumen of the small intestine is empty with no evidence of obstruction, foreign material or infiltrative disease.

BREED

Cavalier King Charles
Spaniel

SEX

Neutered Male

The visible colon is normal in wall thickness (< 0.2 cm) and layering. Contents are consistent with normal formed feces and gas.

AGE

10 Years

Pancreas

The pancreatic parenchyma is appropriately isoechoic to surrounding tissue. Visible capsule is smooth and normal in contour. There is no visible pancreatic duct dilation. There is no evidence of active peripancreatic inflammation.

WEIGHT

10 kg

Free Abdomen

There is no evidence of free peritoneal effusion noted in these images.

INTERPRETED BY

Beth Johnson, DVM
DACVIM

Sublumbar and mesenteric lymph nodes are enlarged with swollen irregular capsular contour and loss of normal length to width ratio (rounded in shape). Nodes are hypoechoic with loss of normal parenchymal detail.

IMAGING PERFORMED BY

Crystal Hill

ULTRASONOGRAPHIC FINDINGS

- **Scalloped spleen** – can be associated with benign or malignant infiltrative disease. Common causes include a reactive spleen secondary to immune stimulus or early infiltrative round cell neoplasia such as lymphoma or mast cell tumor.
- **Aggressive sublumbar and mesenteric lymph nodes** – most consistent with infiltrative round cell or metastatic neoplasia. A benign aggressive inflammatory response cannot be ruled out without tissue sampling +/- culture.

HOSPITAL NAME

Acton Vet Clinic

INTERPRETATION OF THE FINDINGS & FURTHER RECOMMENDATIONS

REFERRING VET

Dr. Hess

Given this patient's reported diffuse lymphadenopathy combined with the intraabdominal lymphadenopathy, infiltrative neoplasia such as lymphoma is a top differential. However, other inflammatory diseases including infectious disease cannot be definitively ruled out.

INVOICE

46723

Recommendations include fine needle aspirates of the enlarged lymph nodes as the next diagnostic step if patient's coagulation status is appropriate. Additionally, a fine needle aspirate of the spleen could be considered.

DATE

4/18/23



PATIENT

Percy Gain

SPECIES

Canine

BREED

Cavalier King Charles
Spaniel

SEX

Neutered Male

AGE

10 Years

WEIGHT

10 kg

INTERPRETED BY

Beth Johnson, DVM
DACVIM

**IMAGING
PERFORMED BY**

Crystal Hill

HOSPITAL NAME

Acton Vet Clinic

REFERRING VET

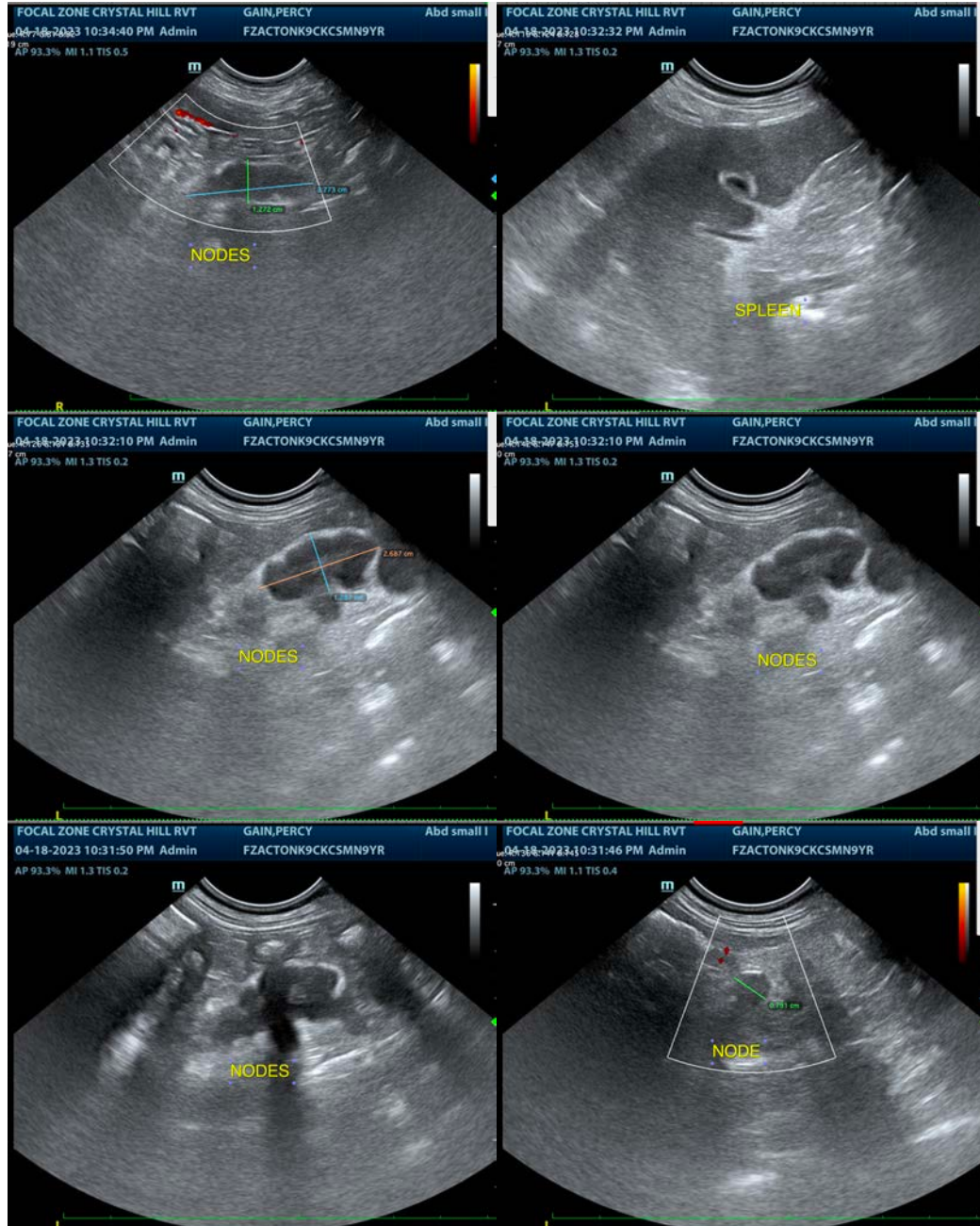
Dr. Hess

INVOICE

46723

DATE

4/18/23





PATIENT

Percy Gain

SPECIES

Canine

BREED

Cavalier King Charles
Spaniel

SEX

Neutered Male

AGE

10 Years

WEIGHT

10 kg

INTERPRETED BY

Beth Johnson, DVM
DACVIM

**IMAGING
PERFORMED BY**

Crystal Hill

HOSPITAL NAME

Acton Vet Clinic

REFERRING VET

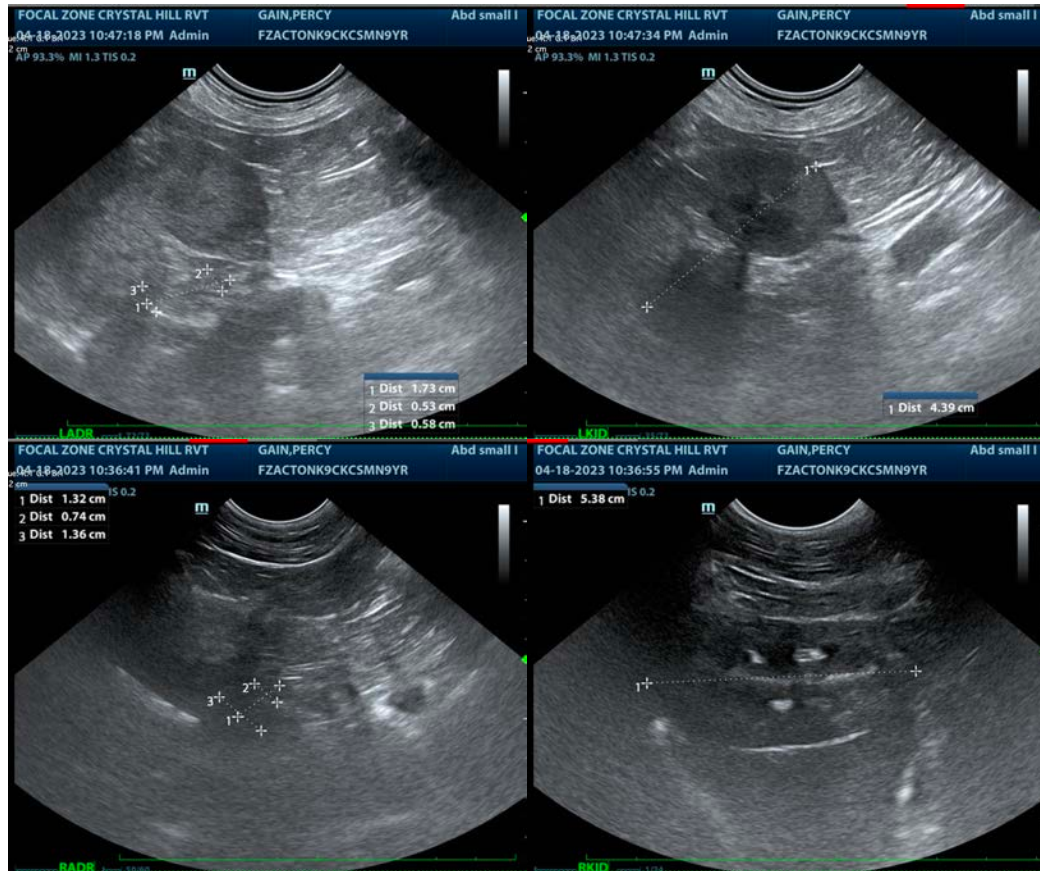
Dr. Hess

INVOICE

46723

DATE

4/18/23



The information and recommendations provided are based on the images presented by the referring veterinarian/sonographer. No evaluation can be communicated regarding pathology that was not visible in the image/video clips provided.

Thank you for this referral. If the clinical or image interpretation does not parallel your findings or if I can be of any further assistance please contact me.

Beth Johnson, DVM, DACVIM
Beth.Johnson@sonopath.com