

**DATE PRESENTING CLINICAL SIGNS**

4/18/23 Recheck hx right adrenal mass suspect pheochromocytoma.

PATIENT

Mabel Hollenbach

Current Medications: Provable SID, Budesonide 1mg twice weekly, Vetri Source Sam E 225mg SID, Dasuquin SID, Fish Oil SID, Proin 25mg 1.5 BID, Pala tech cran ½ SID, Trilostane 2.5mg BID, Aspirin 6mg/mL 1mL SID.

Date of Previous IntraPet Ultrasound: 12/6/22. See attached.

Sedation: Not required to complete full diagnostic ultrasound.

SPECIES

Canine

Stat Report: Not requested.

Imaging Performed By: Andi Parkinson, BS, RDMS.

BREED

Shih Tzu X

ULTRASONOGRAPHIC EXAMINATION OF THE ABDOMEN**Urinary System**

The urinary bladder is moderately distended with anechoic contents. No masses, inflammatory changes, echogenic sediment or cystoliths are observed. The urinary bladder, trigone and visible pelvic urethra are normal in thickness with a smooth mucosal surface.

SEX

Spayed Female

The right kidney is normal in size (5.19 cm), shape and echogenicity. It has smooth peripheral margination. There is a normal 1:3 cortex to medulla ratio with appropriate corticomedullary distinction. There is no evidence of pyelectasia, mineral or infarcts observed.

AGE

1/25/13

The left kidney is normal in size (4.45 cm), shape and echogenicity. It has smooth peripheral margination. There is a normal 1:3 cortex to medulla ratio with appropriate corticomedullary distinction. There is no evidence of pyelectasia, mineral or infarcts observed.

WEIGHT

22 Pounds

Adrenal Glands

The right adrenal gland is enlarged (2.5 cm x 2.5 cm) with mild heterogenous parenchymal changes. Swollen capsular expansion is noted without evident capsular escape or vascular invasion.

INTERPRETED BY

Beth Johnson, DVM
DACVIM

The left adrenal gland is normal in size (2.17 cm long x 0.70 cm at the cranial pole and 0.61 cm at the caudal pole), shape and contour. A hyperechoic nodule is noted in the cranial pole. Nodule does not disrupt normal shape and/or architecture. Visible surrounding vasculature appears normal.

HOSPITAL NAME

Perry Hall AH

Spleen

The spleen is subjectively normal in size with a normal smooth capsular contour. Parenchyma is appropriately finely textured and homogenous with normal echogenicity relative to surrounding tissue (hyperechoic to liver). No focal nodules or masses are observed. Splenic vasculature appears normal.

REFERRING VET

Dr. Baer

Liver

The liver is subjectively normal in size with normal smooth curvilinear peripheral contour. Parenchyma is appropriately hypoechoic to the spleen in echogenicity and appropriately mildly coarse and homogenous in echotexture. No focal lesions are observed. Visible vasculature and biliary tree appear normal without distension or congestion.

INVOICE

46729

The gallbladder is non-distended in size. The wall is smooth without visible thickening. Luminal contents are primarily anechoic. There is no evidence of cystic or common bile duct dilation.

Gastrointestinal

The stomach wall is normal in thickness (canine < 0.5 cm and feline < 0.4 cm) and layering. The lumen of the stomach is empty with no evidence of obstruction, foreign material or infiltrative disease. Pyloric outflow tract appears patent.

The visible small intestines are normal in wall thickness and layering (canine duodenum < 0.5 cm and feline duodenum < 0.4 cm; other < 0.3 cm). Small intestinal motility appears adequate (1-3 contractions per min). The lumen of the small intestine is empty with no evidence of obstruction, foreign material or infiltrative disease.

The visible colon is normal in wall thickness (< 0.2 cm) and layering. Contents are consistent with normal formed feces and gas.

Pancreas

The observed pancreas appears appropriately isoechoic to surrounding omental fat. The capsule is mildly irregular in shape. Parenchyma is mildly heterogenous and coarse. There is no visible pancreatic duct dilation. There is no evidence of active peripancreatic inflammation.

Free Abdomen

There is no evidence of free peritoneal effusion noted in these images.

There is no apparent lymphadenopathy noted in these images.

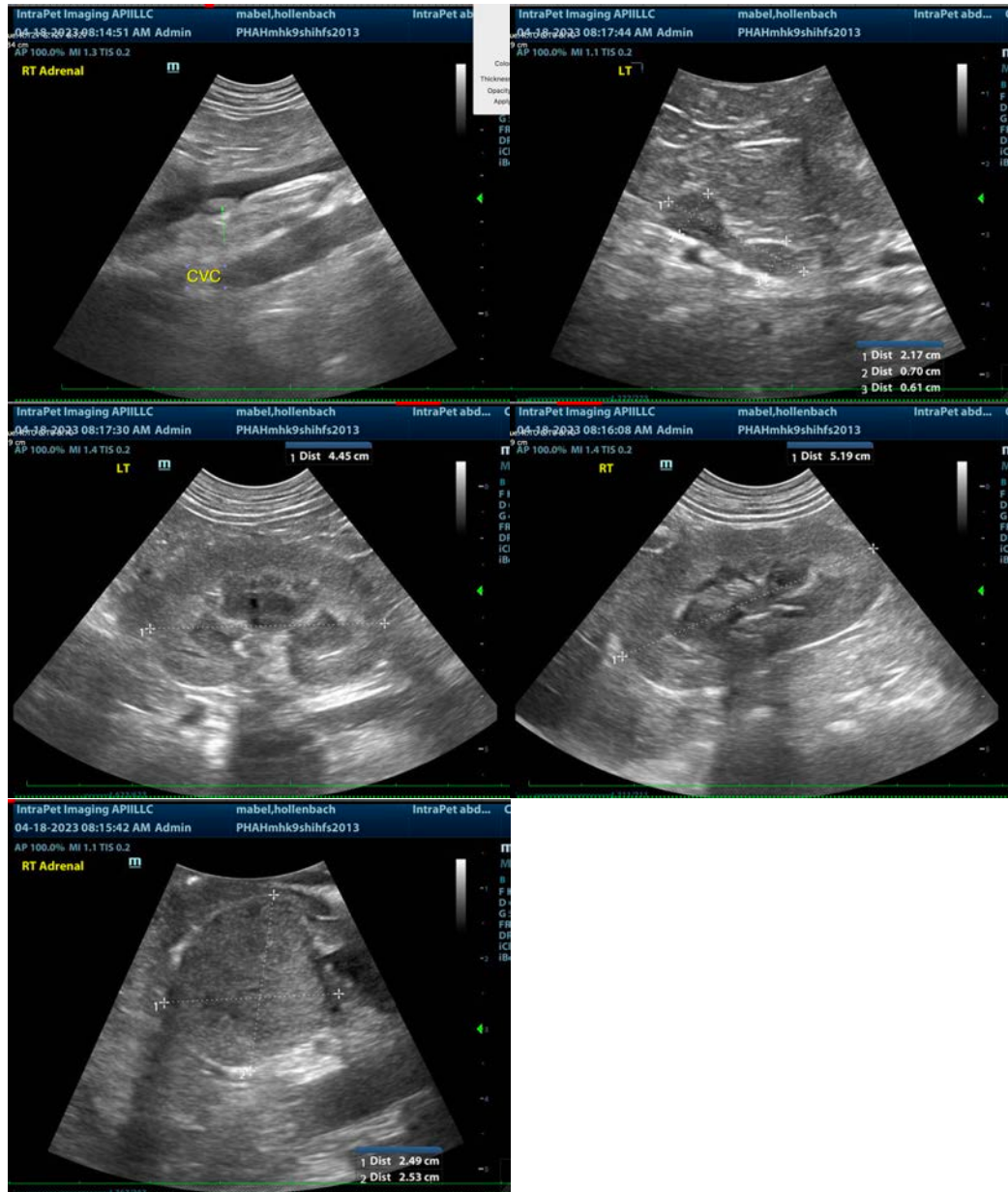
A small echogenic density is still present within the caudal vena near the right adrenal mass, and unchanged.

ULTRASONOGRAPHIC FINDINGS

- **Right adrenal mass with possible vascular invasion versus thrombus** – This finding is concerning for adenocarcinoma versus possibly pheochromocytoma versus other. A benign adenoma with possible thrombus within the vena cava versus tumor invasion can't be ruled out but is considered less likely.
- **Left adrenal nodule** – This is benign in appearance and has not changed significantly from previous studies.
- **Pancreatic age-related remodeling** – Mild irregularities are consistent with benign age-related change. Low-grade smoldering chronic pancreatitis cannot be ruled out and should be suspected in the face of appropriate clinical signs.

INTERPRETATION OF THE FINDINGS & FURTHER RECOMMENDATIONS

This exam is largely unchanged from the previous study. Therefore, further recommendations are similar and primarily dependent on what has already been, results, patient improvement, progression, etc. If not already evaluated, an abdominal CT scan could also be considered for potentially more information regarding the caudal vena cava density.



The information and recommendations provided are based on the images presented by the referring veterinarian/sonographer. No evaluation can be communicated regarding pathology that was not visible in the image/video clips provided.

Thank you for this referral. If the clinical or image interpretation does not parallel your findings or if I can be of any further assistance please contact me.

Beth Johnson, DVM, DACVIM
Beth.Johnson@sonopath.com