

**DATE PRESENTING CLINICAL SIGNS**

4/18/23

May 2022 anemia/thrombocytopenia (Hct: 27%, Plt: 56K) confirmed on blood smear. Ecanis positive. Started Doxycycline and Prednisolone- improved and normalized. Tapered pred quickly as counts normalized quickly after Doxy/Pred started. Low plt returned July 2022. Restarted Doxycycline and increased prednisone. Slow taper over the next 6 months of pred. Off pred at the end of Nov and

**PATIENT**

Buddy Seward

multiple normal CBC since D/C of medications. 4/17: Presented for lethargy, decreased appetite, abdominal distention, Hct: 29%, Plt: 65K. Slide agglutination negative. Blood smear- Plt count 60K. nonregenerative anemia currently

**SPECIES**

Canine

Current Medications: Begin Prednisone 40mg once daily, Begin Mycophenolate 250mg cap PO q 12 hrs, Cerenia 60mg once daily

**BREED**

Beagle

Lab Results: 4/17 Hct 29%- nonregenerative. Plt: 65K (manual 60K). Slide agglutination negative  
Radiographs: 4/17- decreased abdominal detail and significant enlargement of spleen.

**SEX**

Neutered Male

Date of Previous IntraPet Ultrasound: No previous.  
Sedation: Not required to complete full diagnostic ultrasound.  
Stat Report: Not requested.  
Imaging Performed By: Andi Parkinson, BS, RDMS.

**ULTRASONOGRAPHIC EXAMINATION OF THE ABDOMEN****AGE**

11/12/16

**Urinary System**

The urinary bladder is moderately distended with anechoic contents. No masses, inflammatory changes, echogenic sediment or cystoliths are observed. The urinary bladder, trigone and visible pelvic urethra are normal in thickness with a smooth mucosal surface.

**WEIGHT**

51.5 Pounds

The prostate is unable to be well visualized in these images.

**INTERPRETED BY**Beth Johnson, DVM  
DACVIM

The area of the right kidney is examined without evident pathology, but the kidney is not distinctly visualized to obtain a measurement.

**HOSPITAL NAME**

Timonium AH

The left kidney is normal in size (6.42 cm), shape and echogenicity. It has smooth peripheral margination. There is a normal 1:3 cortex to medulla ratio with appropriate corticomedullary distinction. There is no evidence of pyelectasia, mineral or infarcts observed.

**Adrenal Glands****REFERRING VET**

Dr. McMichael

The right adrenal gland is unable to be well visualized in these images.

The left adrenal gland is normal in size (2.11 cm long x 0.56 cm at the cranial pole and 0.72 cm at the caudal pole), shape and contour. Corticomedullary structure is unremarkable. Visible surrounding vasculature appears normal.

**INVOICE**

46733

**Spleen**

Spleen is subjectively large in size with a swollen and scalloped/undulating capsular contour. Multifocal coalescing nodules are noted throughout the parenchyma. Splenic vasculature appears normal. Enhanced hyperechoic surrounding fat is noted.

**Liver**

Liver is subjectively enlarged (swollen contour) without disruption of architecture. It has a normal homogenous echotexture. Parenchyma is diffusely hyperechoic characterized by less prominent than normal portal vein walls and increased echogenicity relative to the spleen and falciform fat. No focal lesions are observed. Visible vasculature and biliary tree appear normal without distension or congestion.

The gallbladder is non-distended in size. The wall is smooth without visible thickening. Luminal contents are primarily anechoic. There is no evidence of cystic or common bile duct dilation.

### ***Gastrointestinal***

The stomach wall is normal in thickness (canine < 0.5 cm and feline < 0.4 cm) and layering. The lumen of the stomach is empty with no evidence of obstruction, foreign material or infiltrative disease. Pyloric outflow tract appears patent.

The visible small intestines are normal in wall thickness and layering (canine duodenum < 0.5 cm and feline duodenum < 0.4 cm; other < 0.3 cm). Small intestinal motility appears adequate (1-3 contractions per min). The lumen of the small intestine is empty with no evidence of obstruction, foreign material or infiltrative disease.

The visible colon is normal in wall thickness (< 0.2 cm) and layering. Contents are consistent with normal formed feces and gas.

### ***Pancreas***

The pancreatic parenchyma is appropriately isoechoic to surrounding tissue. Visible capsule is smooth and normal in contour. There is no visible pancreatic duct dilation. There is no evidence of active peripancreatic inflammation.

### ***Free Abdomen***

There is no evidence of free peritoneal effusion noted in these images.

Diffuse lymphadenopathy is noted throughout the cranial abdomen.

## **ULTRASONOGRAPHIC FINDINGS**

- **Honeycomb Spleen** – This finding is strongly suggestive of infiltrative disease such as round cell neoplasia. Benign disease cannot be ruled out but is considered less likely.
- **Hyperechoic hepatomegaly** - This appearance is non-specific and most consistent with a benign steroid (endocrine) or vacuolar hepatopathy or reactive or idiopathic hepatopathy. Inflammatory and/or infiltrative disease (such as round cell neoplasia) are also possible but considered less likely.
- **Diffuse cranial abdominal lymphadenopathy** – Both reactive lymphadenopathy as well as infiltrative neoplasia are differentials and cannot be differentiated with tissue sampling.

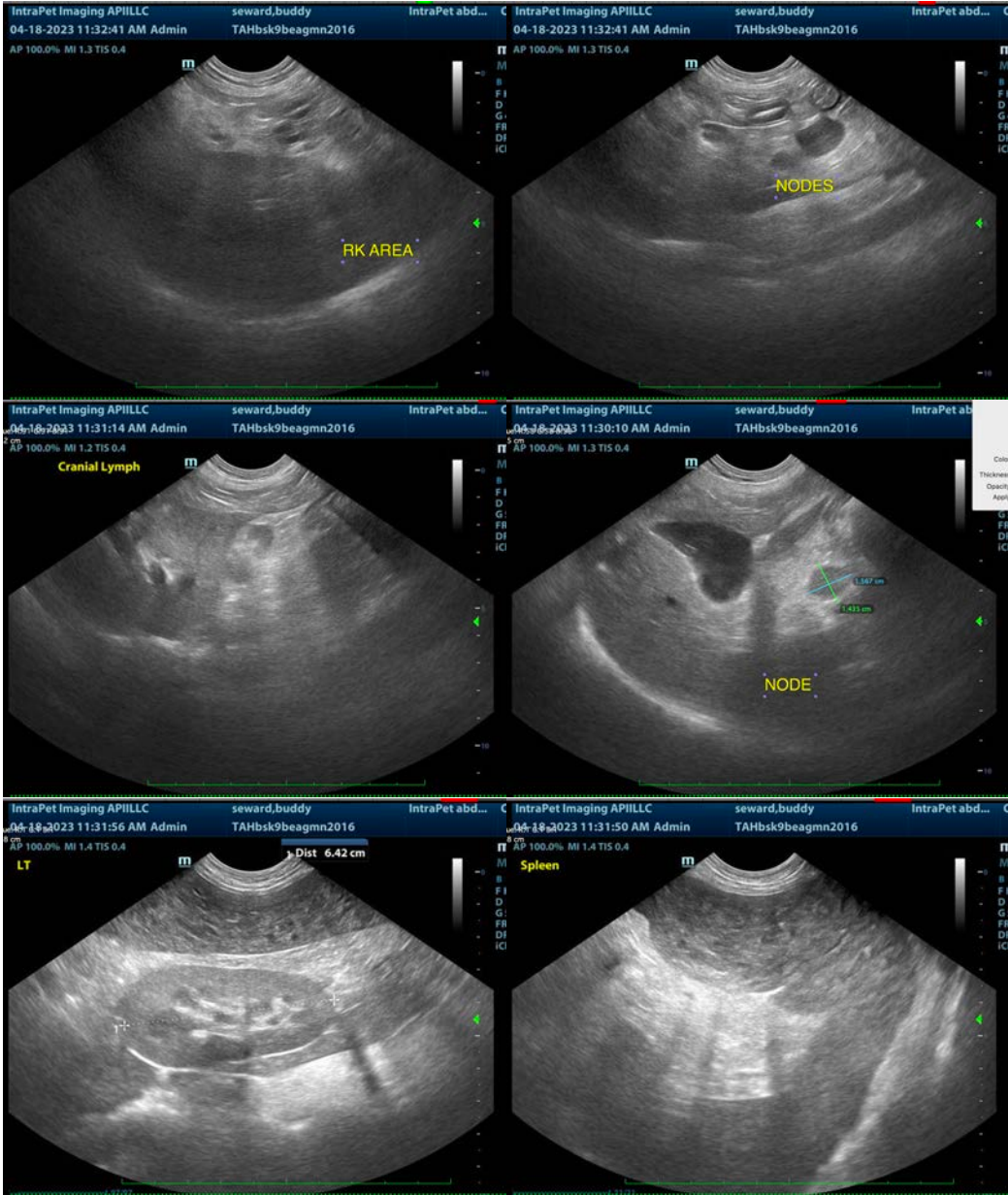
## **INTERPRETATION OF THE FINDINGS & FURTHER RECOMMENDATIONS**

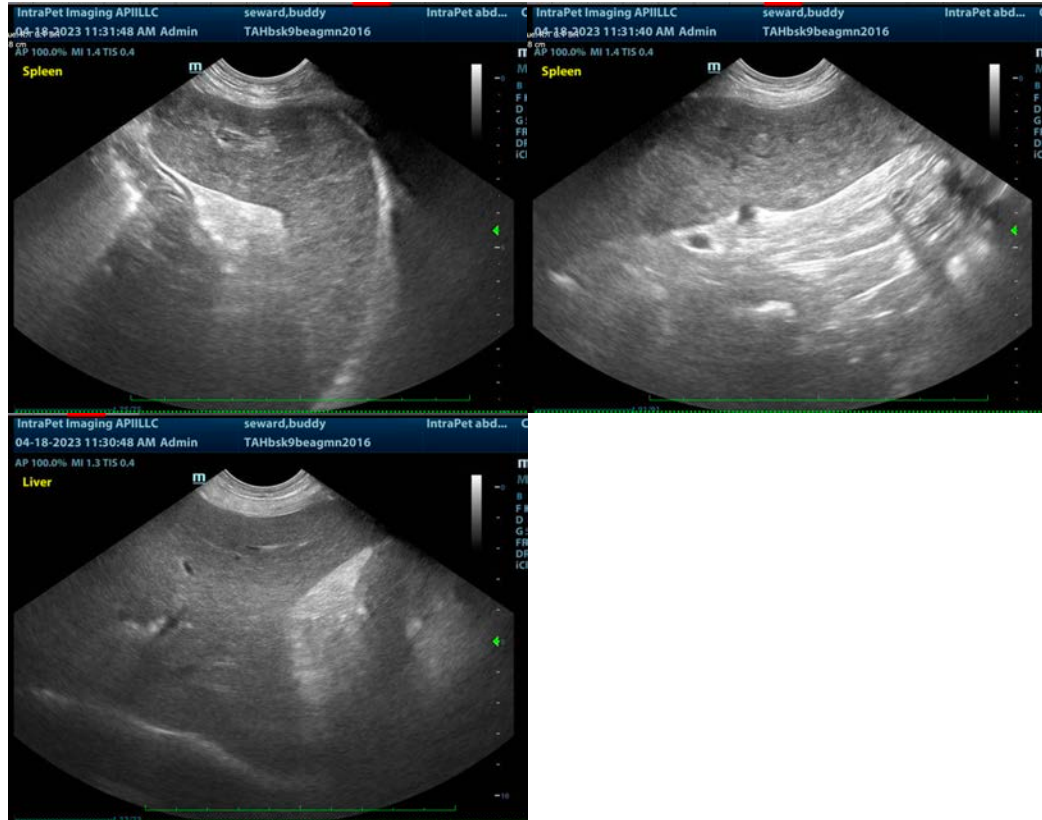
The appearance of the spleen and lymphadenopathy is concerning for infiltrative neoplasia versus an infectious disease or strictly autoimmune. However, the course of this disease for almost a year now seems unlikely if the underlying etiology was neoplasia. Having said that, recommendations include (if not recently evaluated):

Three view thoracic radiographs are recommended for further assessment of cardio-pulmonary status as well as to further evaluate for any evidence of metastatic disease, if not recently evaluated.

Ultimately, fine needle aspirates of the spleen +/- the enlarged lymph nodes are recommended if a platelet count safe enough to perform them can be reached. If not, potentially bone marrow cytology would yield a diagnosis with less risk of uncontrollable hemorrhage. Additionally, recheck of this patient's infectious disease status is recommended.

In the meantime, as is reportedly already in place, and given the continued relapses off of Prednisone, a 2<sup>nd</sup> immunosuppressant is recommended. Hopefully by implementing a 2<sup>nd</sup> immunosuppressant, the prednisone can ultimately be tapered and discontinued. However, given the multiple relapses, discontinuation of all immunosuppressants again is not recommended. Recommendations include finding the lowest tolerated dose for lifelong therapy.





The information and recommendations provided are based on the images presented by the referring veterinarian/sonographer. No evaluation can be communicated regarding pathology that was not visible in the image/video clips provided.

Thank you for this referral. If the clinical or image interpretation does not parallel your findings or if I can be of any further assistance please contact me.

**Beth Johnson, DVM, DACVIM**  
Beth.Johnson@sonopath.com