



PATIENT

Trixie Cinq Mars

SPECIES

Feline

BREED

DSH

SEX

Spayed Female

AGE

14 Years

WEIGHT

13.3 lbs

INTERPRETED BY

Beth Johnson, DVM
DACVIM

IMAGING PERFORMED BY

Dr. Vincent Tavella

HOSPITAL NAME

Williamsburg
Veterinary Clinic

REFERRING VET

Dr. Christopher Dewitt

INVOICE

74534

DATE

4/17/26

PRESENTING CLINICAL SIGNS

Patient is currently managed well for diabetes mellitus with senvelgo. Also on hydrolyzed diet for food sensitivity. Seen on 4/10 for abnormal urinary signs. Bloodwork and UA ta that time were wnl. Over the last 5 days, patient has become anorexic and has not had bowel movements.

Abnormal PE/Chem/CBC/UA Results: PE: Obese, mild dehydration, anorexia. Chem/CBC - pending UA - USG 1.042, no glucosuria. No ketonuria.

ULTRASONOGRAPHIC EXAMINATION OF THE ABDOMEN

Urinary System

The urinary bladder is adequately distended with anechoic contents. No masses, inflammatory changes, echogenic sediment or cystoliths are observed. The urinary bladder, trigone and visible pelvic urethra are normal in thickness with a smooth mucosal surface.

The right kidney is normal is size (4.2 cm), shape and echogenicity. It has smooth peripheral margination. There is a normal 1:3 cortex to medulla ratio with appropriate corticomedullary distinction. There is no evidence of pyelectasia, mineral or infarcts observed.

The left kidney is normal is size (3.8 cm), shape and echogenicity. It has smooth peripheral margination. There is a normal 1:3 cortex to medulla ratio with appropriate corticomedullary distinction. There is no evidence of pyelectasia, mineral or infarcts observed.

Adrenal Glands

The area of the right adrenal gland is examined without evident adrenal gland pathology but is difficult to fully visualized/isolate for measurement.

The left adrenal gland is normal in size (0.53 cm), shape and overall architecture, echogenicity and echotexture. Visible surrounding vasculature appears normal.

Spleen

The spleen is subjectively normal in size with a normal smooth capsular contour. Parenchyma is appropriately finely textured and homogenous with normal echogenicity relative to surrounding tissue (hyperechoic to liver). No focal nodules or masses are observed. Splenic vasculature appears normal.

Liver

The liver is subjectively normal in size with normal smooth curvilinear peripheral contour. Parenchyma is appropriately hypoechoic to the spleen in echogenicity and appropriately mildly coarse and homogenous in echotexture. No focal lesions are observed. Visible vasculature and biliary tree appear normal without distension or congestion.

The gallbladder is non-distended in size. The wall is smooth without visible thickening. Luminal contents are primarily anechoic. There is no evidence of cystic or common bile duct dilation.

Gastrointestinal

The visible stomach wall is normal in thickness and layering. The lumen of the stomach is empty with no evidence of obstruction, foreign material or infiltrative disease. Pyloric outflow tract appears patent.



PATIENT

Trixie Cinq Mars

SPECIES

Feline

BREED

DSH

SEX

Spayed Female

AGE

14 Years

WEIGHT

13.3 lbs

INTERPRETED BY

Beth Johnson, DVM
DACVIM

IMAGING PERFORMED BY

Dr. Vincent Tavella

HOSPITAL NAME

Williamsburg
Veterinary Clinic

REFERRING VET

Dr. Christopher Dewitt

INVOICE

74534

DATE

4/17/26

The visible small intestine demonstrates areas of moderately thick muscularis layer relative to mucosa (disruption of the normal 1:3 muscularis:mucosa ratio). Small intestinal submucosa is slightly irregular, thick and hyperechoic, without evident loss of layering appreciated. The lumen of the small intestine is empty with no evidence of obstruction or foreign material.

The visible colon is normal in wall thickness (< 0.2 cm) and layering. Contents are consistent with normal formed feces and gas.

Pancreas

Pancreas is prominent (enlarged) in size, hypoechoic to surrounding tissue and has a mildly irregular undulating contour. Parenchyma is coarse with mixed echogenic remodeling noted. No pancreatic duct dilation is noted.

Free Abdomen

There is no visible free peritoneal effusion noted in these images.

There is no apparent pathologic lymphadenopathy noted in these images.

ULTRASONOGRAPHIC FINDINGS

- Moderate inflammatory bowel disease (IBD) pattern – Thick muscularis has been reported with infiltrative bowel disease including both benign inflammatory disease as well as infiltrative neoplasia such as lymphoma. No loss of layering or distinct characteristics of malignancy are present. Therefore, differentials cannot be further ranked without tissue sampling.
- Concurrent chronic low-grade smoldering pancreatitis can't be ruled out and should be suspected as a potential contributing factor to patient's reported clinical signs.

INTERPRETATION OF THE FINDINGS & FURTHER RECOMMENDATIONS

A gastrointestinal malabsorption panel (including cobalamin, folate, TLI and PLI) to Texas A&M GI Laboratory is recommended for further evaluation of GI and pancreatic function.

Further evaluation for possible pain (dental, orthopedic, other), upper respiratory disease or oropharyngeal disease, cardiac disease and/or neurologic disease vs other as possible causes for decreased appetite is also recommended.

Pending results of above, if supportive/symptomatic medical management does not improve clinical signs, and a diagnosis is not made, biopsies of the GI tract, being sure to include ileum, if possible, could be considered to further investigate possible contributing bowel disease.

Other than supportive/symptomatic medical management of clinical signs, further treatment recommendations are largely dependent on results of the above.



PATIENT

Trixie Cinq Mars

SPECIES

Feline

BREED

DSH

SEX

Spayed Female

AGE

14 Years

WEIGHT

13.3 lbs

INTERPRETED BY

Beth Johnson, DVM
DACVIM

IMAGING PERFORMED BY

Dr. Vincent Tavella

HOSPITAL NAME

Williamsburg
Veterinary Clinic

REFERRING VET

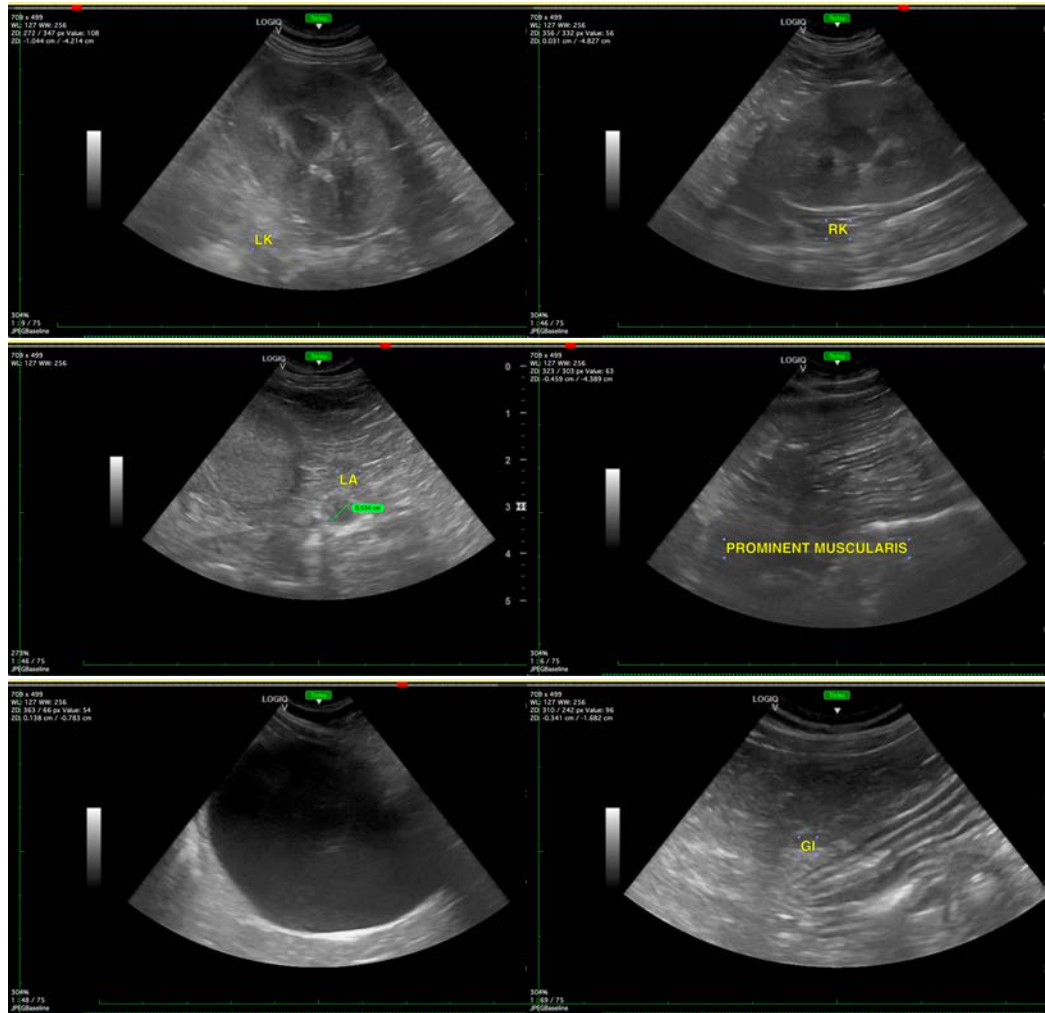
Dr. Christopher Dewitt

INVOICE

74534

DATE

4/17/26



The information and recommendations provided are based on the images presented by the referring veterinarian/sonographer. No evaluation can be communicated regarding pathology that was not visible in the image/video clips provided.

Thank you for this referral. If the clinical or image interpretation does not parallel your findings or if I can be of any further assistance please contact me.

Beth Johnson, DVM, DACVIM
info@sonopath.com