

PATIENT

Oreo Hunter

SPECIES

Canine

BREED

Heeler Mix

SEX

Neutered Male

AGE

14 years

WEIGHT

46.4 lbs

INTERPRETED BY

Beth Johnson, DVM
DACVIM

IMAGING PERFORMED BY

Jenna Walsh, CVT

HOSPITAL NAME

West Hills AH

REFERRING VET

Dr Glaze

INVOICE

12769

DATE

4.17.23

PRESENTING CLINICAL SIGNS

History: 13-year-old MN Blue Heeler x with 2 week history of inappetance, history of coughing for past 6 months, now intermittent non weight bearing lame on right forelimb Current Medications Cerenia, megestrol esterase, gabapentin, amantadine, entyce Radiographic Findings Soft tissue nodule - right caudal lung lobe, normal abdomen and trunk rads Primary Question/Differential to Be Answered in This Exam Cause of inappetance? neoplasia? Cause of proteinuria?

Abnormal PE/Chem/CBC/UA Results: K: 3.7 (N: 4), Na:K Ratio: 41 (N 28-37), UPC 4.1

ULTRASONOGRAPHIC EXAMINATION OF THE ABDOMEN

Urinary System

Urinary bladder is adequately distended with anechoic contents. No masses, inflammatory changes, echogenic sediment or cystoliths are observed. The urinary bladder, trigone and visible pelvic urethra are normal in thickness with a smooth mucosal surface.

Prostate is normal in size, echotexture and echogenicity for a neutered male.

Left kidney is normal in size (6.05 cm), shape and echogenicity. It has smooth peripheral margination. There is a normal 1:3 cortex to medulla ratio with appropriate corticomedullary distinction. There is no evidence of pyelectasia, mineral or infarcts observed.

Right kidney is normal in size (5.99 cm), shape and echogenicity. It has smooth peripheral margination. There is a normal 1:3 cortex to medulla ratio with appropriate corticomedullary distinction. There is no evidence of pyelectasia, mineral or infarcts observed.

Adrenal Glands

The left gland is plump/swollen in size (3.49 cm long / 0.98 cm at cranial pole / 1.26 cm at caudal pole) Normal shape and contour are maintained without evidence of capsular invasion. Corticomedullary structure is unremarkable. A hyperechoic nodule is noted in the caudal pole. Nodule does not disrupt normal shape and/or architecture. Visible surrounding vasculature appears normal.

The right gland is plump/swollen in size (2.41 cm long / 1.80 cm at cranial pole / 0.85 cm at caudal pole). Normal shape and contour are maintained without evidence of capsular invasion. Corticomedullary structure is unremarkable. Visible surrounding vasculature appears normal.

Spleen

Spleen is subjectively normal in size with a normal smooth capsular contour. Parenchyma is appropriately finely textured and homogenous with normal echogenicity relative to surrounding tissue (hyperechoic to liver). No focal nodules or masses are observed. Splenic vasculature appears normal.

Liver

Liver is subjectively normal in size with normal smooth curvilinear peripheral contour. Parenchyma is appropriately hypoechoic to the spleen in echogenicity and appropriately mildly coarse and homogenous in echotexture. No focal lesions are observed. Visible vasculature and biliary tree appear normal without distension or congestion.

Gallbladder is non-distended in size. The wall is smooth without visible thickening. Luminal contents are primarily anechoic. There is no evidence of cystic or common bile duct dilation.



PATIENT

Oreo Hunter

SPECIES

Canine

BREED

Heeler Mix

SEX

Neutered Male

AGE

14 years

WEIGHT

46.4 lbs

INTERPRETED BY

Beth Johnson, DVM
DACVIM

IMAGING PERFORMED BY

Jenna Walsh, CVT

HOSPITAL NAME

West Hills AH

REFERRING VET

Dr Glaze

INVOICE

12769

DATE

4.17.23

Gastrointestinal

The visible stomach wall is normal in thickness and layering. The lumen of the stomach is mildly distended with very echogenic reverberation artifact from intraluminal gas. There is no evidence of obstruction, foreign material or infiltrative disease; however, complete visualization of far wall is partially inhibited by gas. Pyloric outflow tract appears patent.

The visible small intestines are normal in wall thickness and layering. Small intestinal motility appears adequate (1-3 contractions per min). The lumen of the small intestine is empty with no evidence of obstruction, foreign material or infiltrative disease.

The visible colon is normal in wall thickness and layering. Contents are consistent with normal formed feces and gas.

Pancreas

The observed pancreas appears appropriately isoechoic to surrounding omental fat. Visible capsule is smooth and normal in contour. Visible pancreatic parenchyma is homogenous and unremarkable. There is no visible pancreatic duct dilation. There is no evidence of active peripancreatic inflammation.

Free Abdomen

There is no evidence of peritoneal effusion. There is no apparent lymphadenopathy.

ULTRASONOGRAPHIC FINDINGS

Primary Findings

- Bilateral adrenomegaly with hyperechoic adrenal nodule in the caudal pole – consistent with adrenal hyperplasia secondary to pituitary dependent hyperadrenocorticism vs stress or normal variant. Interpret in combination with clinical signs of hyperadrenocorticism.

INTERPRETATION OF THE FINDINGS & FURTHER RECOMMENDATIONS

- This patient's bilateral adrenomegaly is possibly consistent with pituitary-dependent hyperadrenocorticism, which can result in proteinuria, as is reported in this patient. However, typically, hyperadrenocorticism does not result in decreased appetite. Additionally, hyperadrenocorticism should not be worked up in the face of concurrent illness, due to the risk of false positives. The exception to this is a pituitary-dependent macroadenoma. Therefore, a pituitary CT scan could potentially be considered. Additionally, blood pressure is recommended, if not recently evaluated, given the concern for possible hyperadrenocorticism as well as the proteinuria.
- This patient has several other conditions that are more likely contributing to the overall malaise and decreased appetite, including the reported pulmonary nodule and the reported lameness. Therefore, recommendations include addressing those two problems potentially with a thoracic CT as well, fine-needle aspirate, or other sampling of the liver nodule if possible; as well as x-rays, etc. of the lameness to see if the diagnosis that could be contributing to decreased appetite is reached prior to further pursuing hyperadrenocorticism due to a macroadenoma.



PATIENT

Oreo Hunter

SPECIES

Canine

BREED

Heeler Mix

SEX

Neutered Male

AGE

14 years

WEIGHT

46.4 lbs

INTERPRETED BY

Beth Johnson, DVM
DACVIM

IMAGING PERFORMED BY

Jenna Walsh, CVT

HOSPITAL NAME

West Hills AH

REFERRING VET

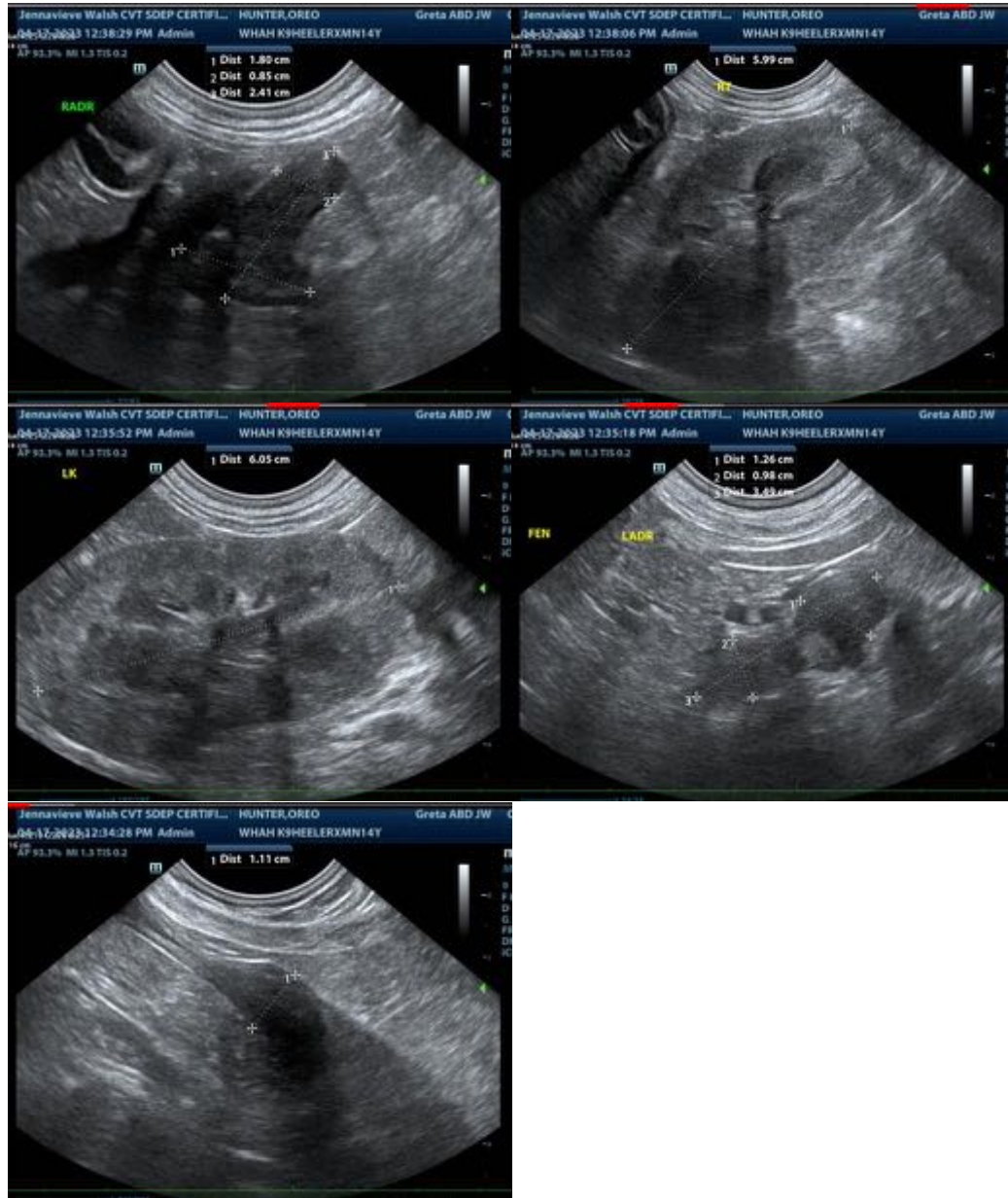
Dr Glaze

INVOICE

12769

DATE

4.17.23



The information and recommendations provided are based on the images presented by the referring veterinarian. No evaluation can be communicated regarding pathology that was not visible in the image/video clips provided.

Thank you for this referral. If the clinical or image interpretation does not parallel your findings or if I can be of any further assistance, please contact me.

Beth Johnson, DVM DACVIM
Beth.Johnson@SonoPath.com