

**DATE PRESENTING CLINICAL SIGNS**

4.17.2023 Weight loss. 8.6lbs 10/21/22 to 6.3lbs 3/20/23. Hx of CKD.

**PATIENT**

Cleo Kruse  
 Current Medications: Cerenia 16mg ¼ SID.  
 Lab Results: See attached.  
 Date of Previous IntraPet Ultrasound: No previous.  
 Sedation: Not required to complete full diagnostic ultrasound.  
 Stat Report: Not requested.

**SPECIES**

Feline  
 Imaging Performed By: Stephanie Warga RDCS, RVT.

**ULTRASONOGRAPHIC EXAMINATION OF THE ABDOMEN****BREED**

DSH

**Urinary System**

The urinary bladder is moderately distended with anechoic contents. No masses, inflammatory changes, echogenic sediment or cystoliths are observed. The urinary bladder, trigone and visible pelvic urethra are normal in thickness with a smooth mucosal surface.

**SEX**

Female Spayed

Kidneys are overall normal in size (left kidney 3.35 cm) (right kidney 3.26 cm) and shape with smooth peripheral margination. A normal 1:3 cortex to medulla ratio is maintained. The medulla and cortices are uniform in texture with some mild increased cortical echogenicity and mild loss of corticomedullary distinction, expected in this age patient. There is no evidence of pyelectasia, mineral or infarcts observed.

**AGE**

8/8/2008

**Adrenal Glands**

The left adrenal gland is normal in size (0.28 cm), shape and contour. Corticomedullary structure is unremarkable. Visible surrounding vasculature appears normal.

**WEIGHT**

2.85 kg

The right adrenal gland is normal in size (0.32 cm), shape and contour. Corticomedullary structure is unremarkable. Visible surrounding vasculature appears normal.

**INTERPRETED BY**

Beth Johnson, DVM  
 DACVIM

**Spleen**

The spleen is subjectively normal in size with a normal smooth capsular contour. Parenchyma is appropriately finely textured and homogenous with normal echogenicity relative to surrounding tissue (hyperechoic to liver). No focal nodules or masses are observed. Splenic vasculature appears normal.

**HOSPITAL NAME**

Cat Hospital Towson

**Liver**

Liver is normal to subjectively small in size with slightly undulating or scalloped capsular contour or margins. Patchy ill-defined areas of increased echogenicity are present with reduced visualization of vessels. No overt nodules or masses are observed. Visible vasculature and biliary tree appear normal without distension or congestion.

**REFERRING VET**

Dr. Martin

Gallbladder is moderately distended with anechoic bile as well as suspended and gravity dependent echogenic debris. The wall is smooth without visible thickening. The cystic and common bile duct are tortuous, but non-pathologically distended (which is often a normal anatomic variant in a senior cat). There is no evidence of effusion or inflammation.

**INVOICE**

12771

**Gastrointestinal**

The visible stomach wall is normal in thickness (CANINE < 0.5 cm) (FELINE < 0.4 cm) and layering. The lumen of the stomach is empty with no evidence of obstruction, foreign material or infiltrative disease. Pyloric outflow tract appears patent.

The visible small intestine demonstrates areas of thick muscularis layer relative to mucosa (disruption of the normal 1:3 muscularis:mucosa ratio). Small intestinal submucosa is slightly irregular, thick and hyperechoic, without evident loss of layering appreciated. The lumen of the small intestine is empty with no evidence of obstruction, foreign material or infiltrative disease.

The visible colon is normal in wall thickness (< 0.2 cm) and layering. Contents are consistent with normal formed feces and gas.

### ***Pancreas***

The observed pancreas is prominent (enlarged) in size, hypoechoic to surrounding tissue and irregular in shape with a swollen undulating contour. Pancreatic duct dilation is noted. Enhanced hyperechoic ill-defined surrounding fat is noted.

### ***Free Abdomen***

There is no free fluid.

Mesenteric lymph nodes are prominent in size with swollen capsular contour. Normal elongated shape (length to width ratio) is maintained. There is no loss of parenchymal detail.

## **ULTRASONOGRAPHIC FINDINGS**

### **Primary Findings**

- Inflammatory bowel disease (IBD) pattern – Thick muscularis has been reported with infiltrative bowel disease including both benign inflammatory disease as well as infiltrative neoplasia such as lymphoma. No aggressive lymphadenopathy, loss of layering, etc. is noted to make lymphoma more probable, but lymphoma cannot be definitively ruled out without tissue sampling
- Reactive lymph nodes – infiltrative neoplastic disease cannot be ruled out but is considered less likely.
- Chronic active pancreatitis
- Liver is subjectively enlarged (swollen contour) without disruption of architecture. It has a normal homogenous echotexture. Parenchyma is diffusely hyperechoic characterized by less prominent than normal portal vein walls and increased echogenicity relative to the spleen and falciform fat. No focal lesions are observed. Visible vasculature and biliary tree appear normal without distension or congestion.
- Mild gallbladder debris – Cholecystic debris is of unknown clinical significance. It can be seen with biliary stasis from fasting or illness, however, it can also be associated with hepatobiliary disease in cats and should be interpreted in combination with clinical signs such as nausea, inappetence, cranial abdominal discomfort and/or laboratory changes such as increased ALP and/or increased Tbili.

### **Secondary Findings**

- Age-related kidney changes.

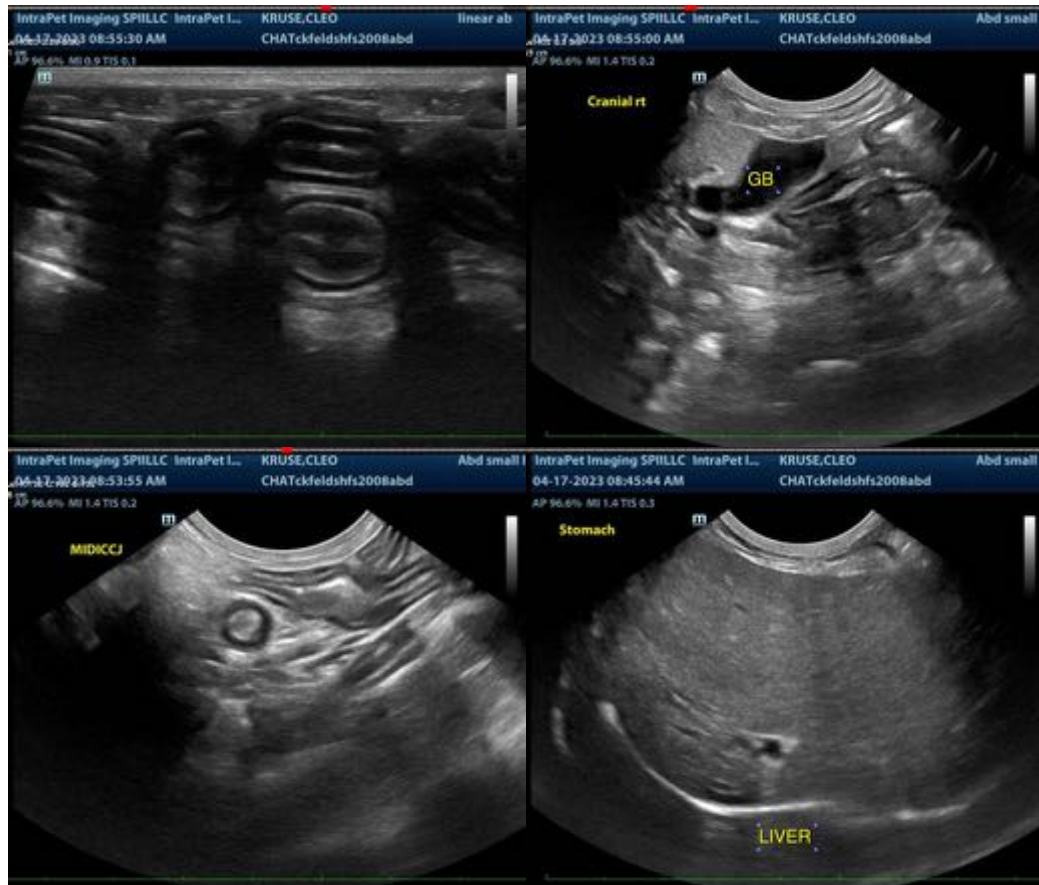
## **INTERPRETATION OF THE FINDINGS & FURTHER RECOMMENDATIONS**

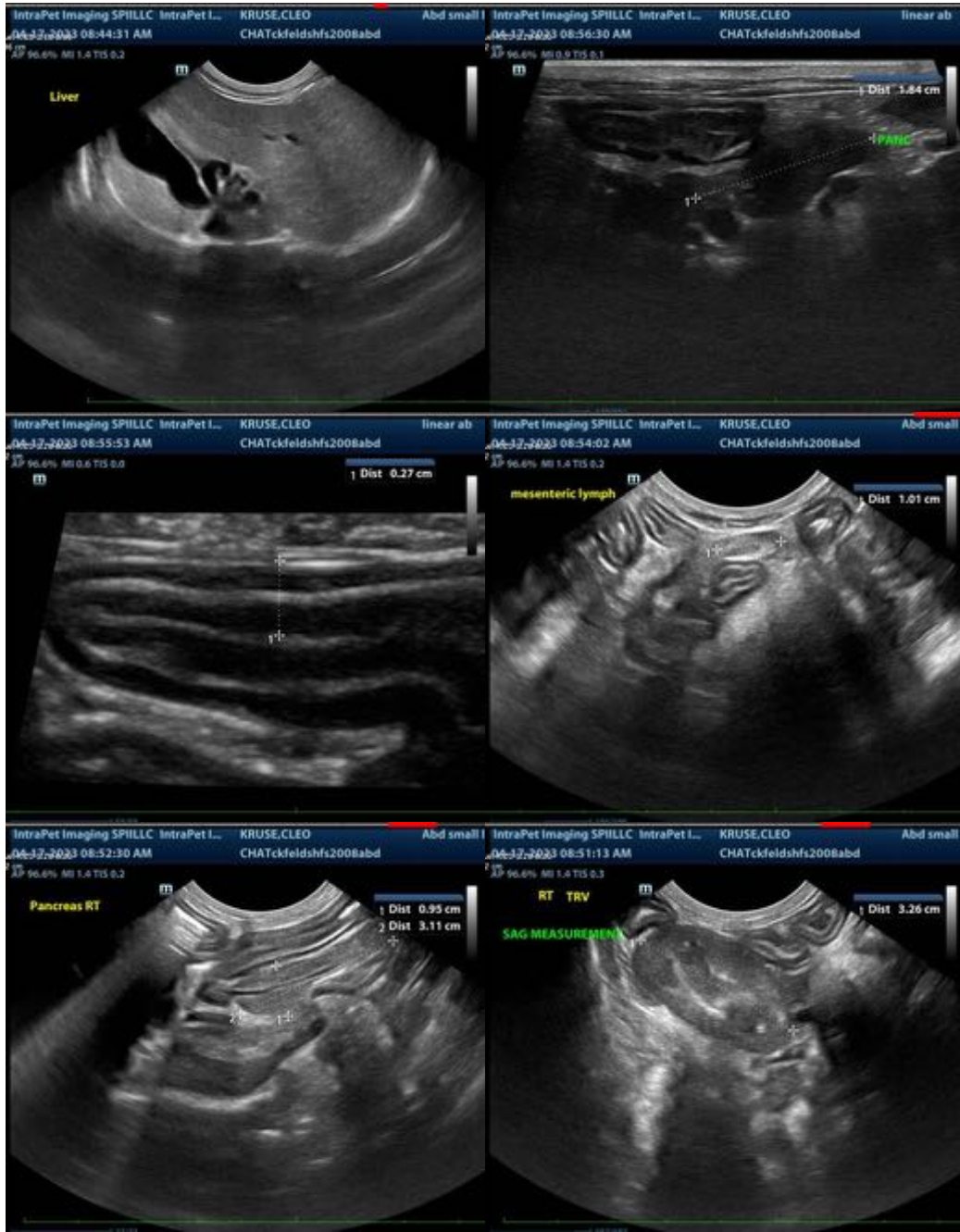
Further recommendations for this patient's reported weight loss is partially dependent on appetite. If patient's appetite is decreased, it could be partially related to the reported chronic kidney disease. Supportive/symptomatic medical management of possible gastritis, nausea, etc., associated with chronic kidney disease could be considered, beginning with antiemetics, gastric protectants, and appetite

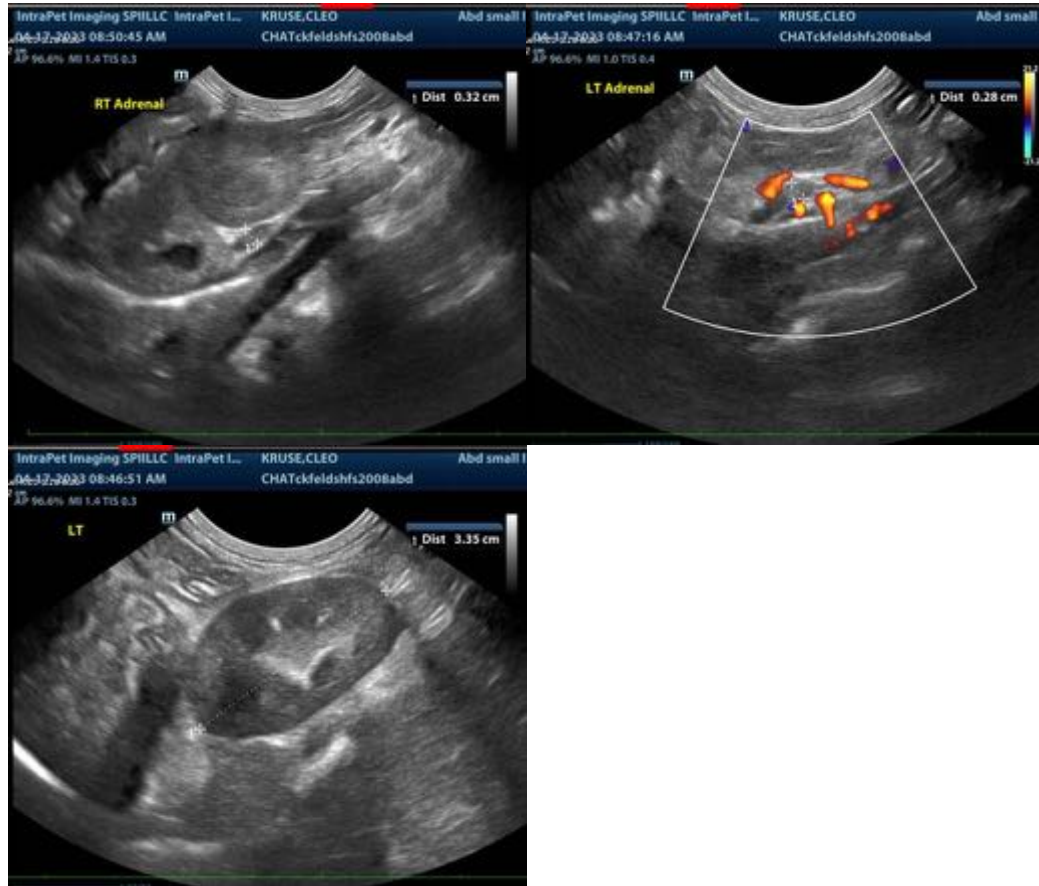
stimulants. However, given the appearance of the bowel, concurrent infiltrative bowel disease is also likely and is more highly suspected as a contributing cause in the face of a normal or even increased appetite; in which case, a gastrointestinal malabsorption panel (including cobalamin, folate, TLI and PLI) to Texas A&M GI Laboratory is recommended for further evaluation of GI and pancreatic function.

Ideally, biopsies of the GI tract, being sure to include ileum if possible, are recommended to definitively diagnose and therefore manage the infiltrative bowel disease.

If biopsies cannot be obtained, empirical therapies could include diet change, empirical deworming with a 5-day course of Panacur, cobalamin supplementation (unless cobalamin level is evaluated and supplementation is not warranted) and prednisolone (if not contraindicated based on patient contraindications, co-morbidities, etc.). Other supportive therapeutic considerations could include fiber supplementation, especially with large bowel diarrhea and/or a probiotic.







The information and recommendations provided are based on the images presented by the referring veterinarian/sonographer. No evaluation can be communicated regarding pathology that was not visible in the image/video clips provided.

Thank you for this referral. If the clinical or image interpretation does not parallel your findings or if I can be of any further assistance, please contact me.

**Beth Johnson, DVM, DACVIM**  
Beth.Johnson@sonopath.com