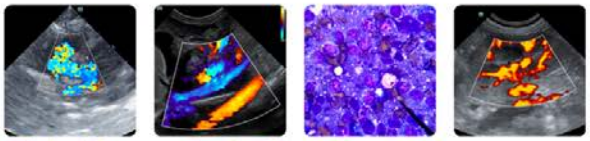

PATIENT
Rosie Hanlon

SPECIES
Canine

BREED
Mini Schnauzer

SEX
Spayed Female

AGE
10 Years

WEIGHT
18 lbs

INTERPRETED BY
Beth Johnson, DVM DACVIM

IMAGING PERFORMED BY
Julia Bakker, DVM

HOSPITAL NAME
Orange Blossom Veterinary Imaging

REFERRING VET
Ashley Sorice, DVM

INVOICE
74530

DATE
4/16/26

PRESENTING CLINICAL SIGNS

O feels P has a pot-bellied appearance as well as PU/PD at home, discussed HAC at length and diagnostic approach (abdominal U/S, ACTH stim), O would like to schedule abdominal US next week if possible (heading up north in a few weeks).

Sample of abdominal effusion taken today to send for fluid analysis. It was straw in color.
Abnormal PE/Chem/CBC/UA Results: Hyperglobulinemia 4.3 ALP 801 Chol 412 Lipase 365 Hyperphosphatemia 6.3 Platelet 529

ULTRASONOGRAPHIC EXAMINATION OF THE ABDOMEN

Urinary System

The urinary bladder is adequately distended with anechoic contents. No masses, inflammatory changes, echogenic sediment or cystoliths are observed. The urinary bladder, trigone and visible pelvic urethra are normal in thickness with a smooth mucosal surface.

The right kidney is normal is size (5.04 cm), shape and echogenicity. It has smooth peripheral margination. There is a normal 1:3 cortex to medulla ratio with appropriate corticomedullary distinction. There is no evidence of pyelectasia, mineral or infarcts observed.

The left kidney is normal is size (5.64 cm), shape and echogenicity. It has smooth peripheral margination. There is a normal 1:3 cortex to medulla ratio with appropriate corticomedullary distinction. There is no evidence of pyelectasia, mineral or infarcts observed.

Adrenal Glands

The right adrenal gland is normal in size (0.77 cm at cranial pole and 0.43 cm at caudal pole), shape and overall architecture, echogenicity and echotexture. Visible surrounding vasculature appears normal.

The left adrenal gland is normal in size (0.48 cm at cranial pole and 0.57 cm at caudal pole), shape and overall architecture, echogenicity and echotexture. Visible surrounding vasculature appears normal.

Spleen

Spleen is subjectively normal in size with a normal smooth capsular contour. Parenchyma is appropriately finely textured and homogenous with normal echogenicity relative to surrounding tissue (hyperechoic to liver). Multifocal well-demarcated hyperechoic homogenous nodules are noted. Splenic vasculature appears normal.

Liver

Liver is subjectively enlarged with mildly irregular margins. Parenchyma is markedly heterogenous characterized by multiple poorly defined hypoechoic nodules within otherwise hyperechoic liver parenchyma. Visible vasculature and biliary tree appear normal without distension or congestion.

Gallbladder is moderately distended with anechoic bile as well as suspended and gravity dependent echogenic debris. The wall is smooth without visible thickening. There is no evidence of cystic or CBD dilation. There is no evidence of effusion or inflammation.

PATIENT
Rosie Hanlon

SPECIES
Canine

BREED
Mini Schnauzer

SEX
Spayed Female

AGE
10 Years

WEIGHT
18 lbs

INTERPRETED BY
Beth Johnson, DVM DACVIM

IMAGING PERFORMED BY
Julia Bakker, DVM

HOSPITAL NAME
Orange Blossom Veterinary Imaging

REFERRING VET
Ashley Sorice, DVM

INVOICE
74530

DATE
4/16/26

Gastrointestinal

The visible stomach wall is normal in thickness and layering. The lumen of the stomach is empty with no evidence of obstruction, foreign material or infiltrative disease. Pyloric outflow tract appears patent.

The visible small intestines are normal in wall thickness and layering. Hyperechoic mucosal fogging or speckling is noted. Small intestinal motility appears adequate (1-3 contractions per min). The lumen is mildly distended with echogenic non-shadowing luminal contents and gas consistent with normal ingesta/chyme. There is no evidence of obstruction, foreign material or infiltrative disease.

The visible colon is normal in wall thickness (< 0.2 cm) and layering. Contents are consistent with normal formed feces and gas.

Pancreas

The pancreas that is observed appears appropriately isoechoic to surrounding omental fat. Visible capsule is smooth and normal in contour. Visible pancreatic parenchyma is homogenous and unremarkable. There is no visible pancreatic duct dilation. There is no evidence of active peripancreatic inflammation.

Free Abdomen

There is a small amount of free fluid noted in these images.

No definitive lymphadenopathy noted, but in the right cranial abdomen there is a very subtle hypoechoic 0.90 cm x 1.5 cm density that could represent a lymph node, although I believe it is a caudal subtle liver nodule.

PRIMARY FINDINGS

- The liver changes described above could represent a benign process such as nodular hyperplasia, steroid or vacuolar hepatopathy, extramedullary hematopoiesis, or even chronic inflammatory disease, but infiltrative neoplasia such as round cell neoplasia, metastatic neoplasia, other can't be ruled out without tissue sampling.

- Mild gallbladder debris - Cholecystic debris is of unknown clinical significance. It can be seen with biliary stasis from fasting or illness. Cholecystic debris is not necessarily related to hepatobiliary disease. Echogenic bile is most commonly an incidental finding in dogs and should be interpreted in combination with clinical signs such as nausea, inappetence, cranial abdominal discomfort and/or laboratory changes such as increased ALP and/or increased Tbili.

- Mucosal speckling – Mucosal speckling is often present with inflammatory bowel disease (IBD). It is not specific for type or severity of disease. Mild speckling change can occur as a normal patient variant in the post-prandial state.

- The small amount of free fluid is of unknown origin. Differentials (unless already ruled out) could include increased hydrostatic pressure (cardiac disease and/or vascular or lymph blockage), decreased oncotic pressure (low albumin), vasculitis, paraneoplastic fluid, rupture/leakage of/from an organ (GI, GB, UB, other), blood (hemoabdomen), other.

PATIENT

Rosie Hanlon

SPECIES

Canine

BREED

Mini Schnauzer

SEX

Spayed Female

AGE

10 Years

WEIGHT

18 lbs

INTERPRETED BY

Beth Johnson, DVM DACVIM

IMAGING PERFORMED BY

Julia Bakker, DVM

HOSPITAL NAME

Orange Blossom Veterinary Imaging

REFERRING VET

Ashley Sorice, DVM

INVOICE

74530

DATE

4/16/26

SECONDARY FINDINGS

- Hyperechoic splenic nodules – most consistent with benign myelolipomas. Other differentials such as fibrosis or calcification caused by old hematomas or infarcts, chronic inflammation, granulomatous disease or metastatic disease cannot be ruled out, but are considered less likely.

INTERPRETATION OF THE FINDINGS & FURTHER RECOMMENDATIONS

As is reportedly already pending, submission of the free abdominal fluid for analysis and cytology is recommended.

Pending results of that evaluation, fine needle aspirates of the liver could be considered if patient's coagulation status is appropriate.

Three view thoracic radiographs are recommended for further assessment of cardio-pulmonary status as well as to further evaluate for any evidence of metastatic disease, if not recently evaluated.

The gastrointestinal changes are of unknown contribution to patient's reported presenting complaint, but especially if combined with any clinical gastrointestinal history potentially warrant further investigation including a routine fecal/giardia exam.

A gastrointestinal malabsorption panel (including cobalamin, folate, TLI and PLI) to Texas A&M GI Laboratory is recommended for further evaluation of GI and pancreatic function.

A fecal enteropathogen PCR panel to Texas A&M GI Laboratory could be considered for further evaluation of possible infectious disease. Contact lab for recommendations on how long to discontinue antibiotics (if indicated) prior to obtaining a stool sample for submission.

Other than supportive/symptomatic medical management of clinical signs, further treatment recommendations are largely dependent on results of the above.

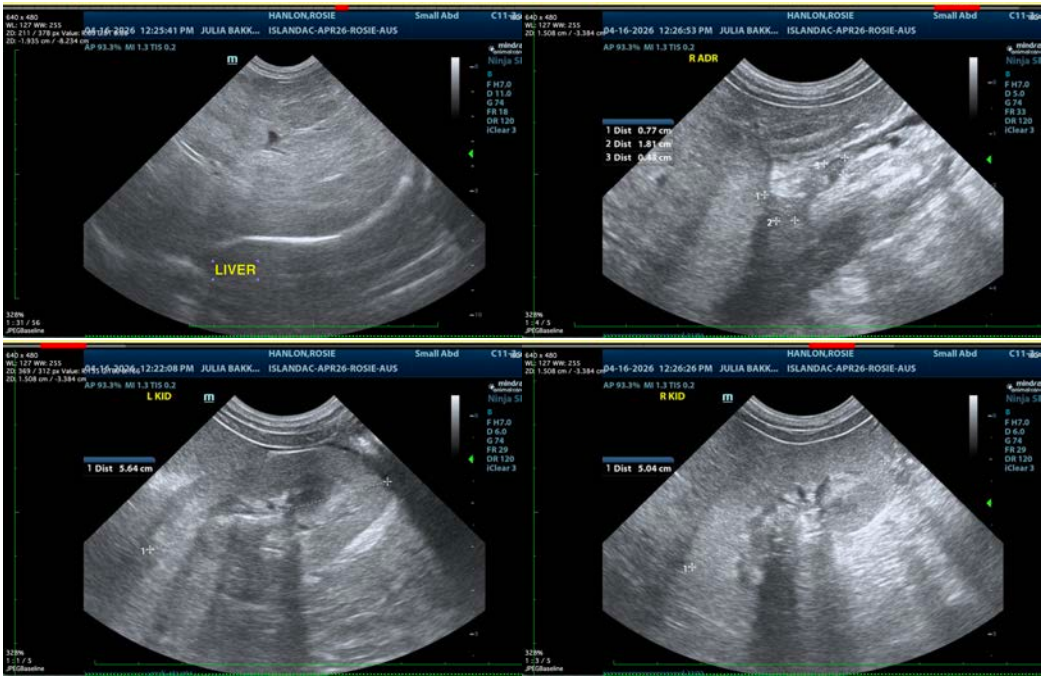

SonoPath
FOSTERING THE ART OF VETERINARY MEDICINE™

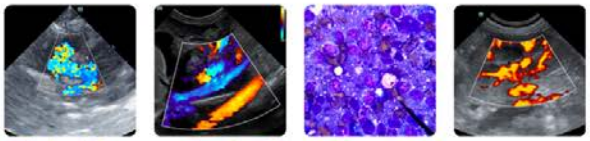

Clinical Sonography & Telecytology
Educational Teleconsultation Services™

SonoPath.com info@sonopath.com 1.800.838.4268

PATIENT

Rosie Hanlon

SPECIES

Canine

BREED

Mini Schnauzer

SEX

Spayed Female

AGE

10 Years

WEIGHT

18 lbs

INTERPRETED BY

Beth Johnson, DVM DACVIM

IMAGING PERFORMED BY

Julia Bakker, DVM

HOSPITAL NAME

Orange Blossom Veterinary Imaging

REFERRING VET

Ashley Sorice, DVM

INVOICE

74530

DATE

4/16/26

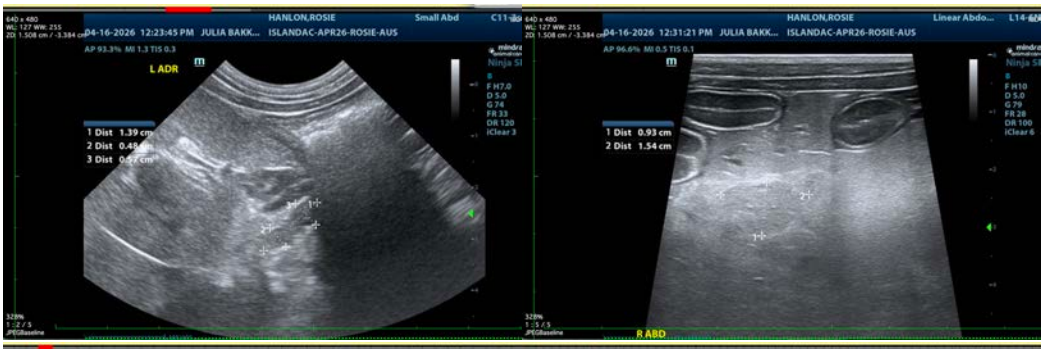

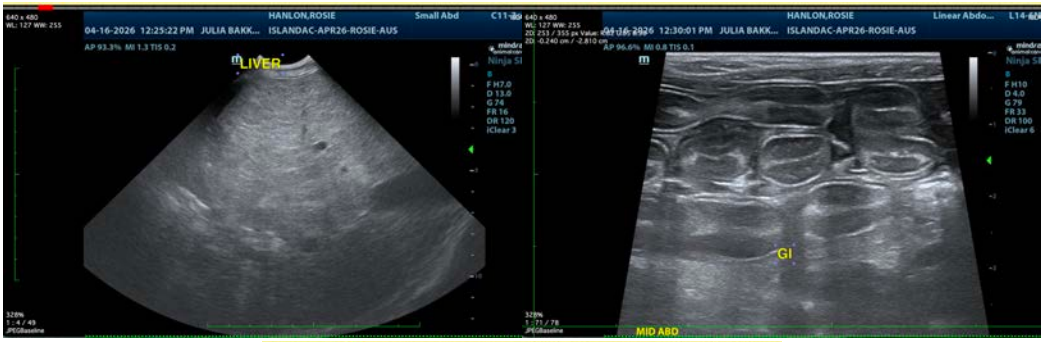

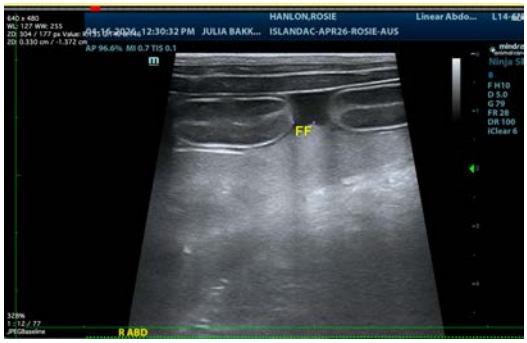

The information and recommendations provided are based on the images presented by the referring veterinarian/sonographer. No evaluation can be communicated regarding pathology that was not visible in the image/video clips provided.

Thank you for this referral. If the clinical or image interpretation does not parallel your findings or if I can be of any further assistance please contact me.

Beth Johnson, DVM, DACVIM
info@sonopath.com