

**PATIENT**

Cecil Kuzo

SPECIES

Feline

BREED

Domestic Shorthair

SEX

Neutered Male

AGE

10 Years 5 Months

WEIGHT

10.55

INTERPRETED BYBeth Johnson, DVM
DACVIM**IMAGING
PERFORMED BY**

Jessica Green

HOSPITAL NAMEStanglein Veterinary
Clinic**REFERRING VET**

Dr. Laura Green

INVOICE

74492

DATE

4/15/26

PRESENTING CLINICAL SIGNS

On C/D for FLUTD/UO. Chronic soft stool (years). Recently incredibly ravenous but losing weight. Has lost ~4#. On Clavamox (and since starting meds patient's appetite is now decreased below "normal").

Abnormal PE/Chem/CBC/UA Results: Hct 26.9%, WBC 27K, Neuts 19K. All else wnl, including T4.

ULTRASONOGRAPHIC EXAMINATION OF THE ABDOMEN**Urinary System**

Urinary bladder is adequately distended. It has a normal uniform wall thickness. Contents include primarily anechoic fluid with a large amount of echogenic non-shadowing debris, most consistent with exfoliated cells, crystals, mucous and/or small blood clots likely combined with incidental suspended lipid. Both sterile inflammation as well as urinary tract infection can present with echogenic debris. No masses or definitive cystoliths are observed. The trigone and visible pelvic urethra are normal in thickness with a smooth mucosal surface.

Kidneys are bilaterally small, irregular and diffusely echogenic with decreased corticomedullary distinction and poor visualization of internal architecture. There is no pyelectasia noted. Left kidney measures 4.05 cm. Right kidney measures 4.7 cm. Small non-obstructive nephroliths are noted bilaterally.

Adrenal Glands

The right adrenal gland is normal in size (0.49 cm), shape and overall architecture, echogenicity and echotexture. Visible surrounding vasculature appears normal.

The left adrenal gland is normal in size (0.54 cm), shape and overall architecture, echogenicity and echotexture. Visible surrounding vasculature appears normal.

Spleen

The spleen is subjectively normal in size with a normal smooth capsular contour. Parenchyma is appropriately finely textured and homogenous with normal echogenicity relative to surrounding tissue (hyperechoic to liver). No focal nodules or masses are observed. Splenic vasculature appears normal.

Liver

The liver is subjectively normal in size with normal smooth curvilinear peripheral contour. Parenchyma is appropriately hypoechoic to the spleen in echogenicity and appropriately mildly coarse and homogenous in echotexture. No focal lesions are observed. Visible vasculature and biliary tree appear normal without distension or congestion.

The gallbladder is non-distended in size. The wall is smooth without visible thickening. Luminal contents are primarily anechoic. There is no evidence of cystic or common bile duct dilation.

Gastrointestinal

The visible stomach wall is normal in thickness and layering. The lumen is mildly distended with primarily fluid as well as some echogenic non-shadowing luminal contents and gas consistent with normal chyme. There is no evidence of obstruction, foreign material, or infiltrative disease. Pyloric outflow tract appears patent.



PATIENT

Cecil Kuzo

SPECIES

Feline

BREED

Domestic Shorthair

SEX

Neutered Male

AGE

10 Years 5 Months

WEIGHT

10.55

INTERPRETED BY

Beth Johnson, DVM
DACVIM

IMAGING PERFORMED BY

Jessica Green

HOSPITAL NAME

Stanglein Veterinary
Clinic

REFERRING VET

Dr. Laura Green

INVOICE

74492

DATE

4/15/26

The visible small intestine demonstrates areas of mildly to moderately thick muscularis layer relative to mucosa (disruption of the normal 1:3 muscularis:mucosa ratio). Small intestinal submucosa is slightly irregular, thick and hyperechoic, without evident loss of layering appreciated. The lumen is mildly distended with echogenic non-shadowing luminal contents and gas consistent with normal ingesta/chyme. There is no evidence of obstruction, foreign material or infiltrative disease.

The visible colon is normal in wall thickness (< 0.2 cm) and layering. The lumen is diffusely moderately to significantly distended with soft stool.

Pancreas

The pancreas that is observed appears appropriately isoechoic to surrounding omental fat. Visible capsule is smooth and normal in contour. Visible pancreatic parenchyma is homogenous and unremarkable. There is no visible pancreatic duct dilation. There is no evidence of active peripancreatic inflammation.

Free Abdomen

There is a trace amount of free fluid noted in these images.

Mesenteric lymph nodes are prominent in size with swollen capsular contour. Normal elongated shape (length to width ratio) is maintained. There is no loss of parenchymal detail.

ULTRASONOGRAPHIC FINDINGS

- Mild to moderate inflammatory bowel disease (IBD) pattern – Thick muscularis has been reported with infiltrative bowel disease including both benign inflammatory disease as well as infiltrative neoplasia such as lymphoma. No loss of layering or distinct characteristics of malignancy are present. Therefore, differentials cannot be further ranked without tissue sampling.
- Moderately reactive mesenteric lymph nodes – infiltrative neoplastic disease cannot be ruled out but is considered less likely.
- The mild amount of free fluid is of unknown origin. Differentials (unless already ruled out) could include increased hydrostatic pressure (cardiac disease and/or vascular or lymph blockage), decreased oncotic pressure (low albumin), vasculitis, paraneoplastic fluid, rupture/leakage of/from an organ (GI, GB, UB, other), blood (hemoabdomen), other.
- Mild to moderate bilateral chronic kidney disease changes with small non-obstructive nephroliths bilaterally.

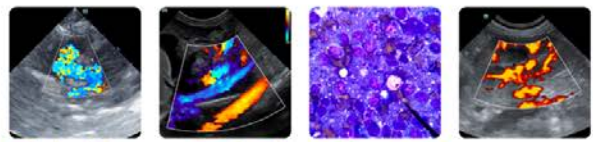
SECONDARY FINDINGS

- Large amount of echogenic urinary bladder debris.

INTERPRETATION OF THE FINDINGS & FURTHER RECOMMENDATIONS

A routine fecal/giardia exam is recommended if not recently evaluated.

A gastrointestinal malabsorption panel (including cobalamin, folate, TLI and PLI) to Texas A&M GI Laboratory is recommended for further evaluation of GI and pancreatic function.



PATIENT

Cecil Kuzo

SPECIES

Feline

BREED

Domestic Shorthair

SEX

Neutered Male

AGE

10 Years 5 Months

WEIGHT

10.55

INTERPRETED BY

Beth Johnson, DVM
DACVIM

IMAGING PERFORMED BY

Jessica Green

HOSPITAL NAME

Stanglein Veterinary
Clinic

REFERRING VET

Dr. Laura Green

INVOICE

74492

DATE

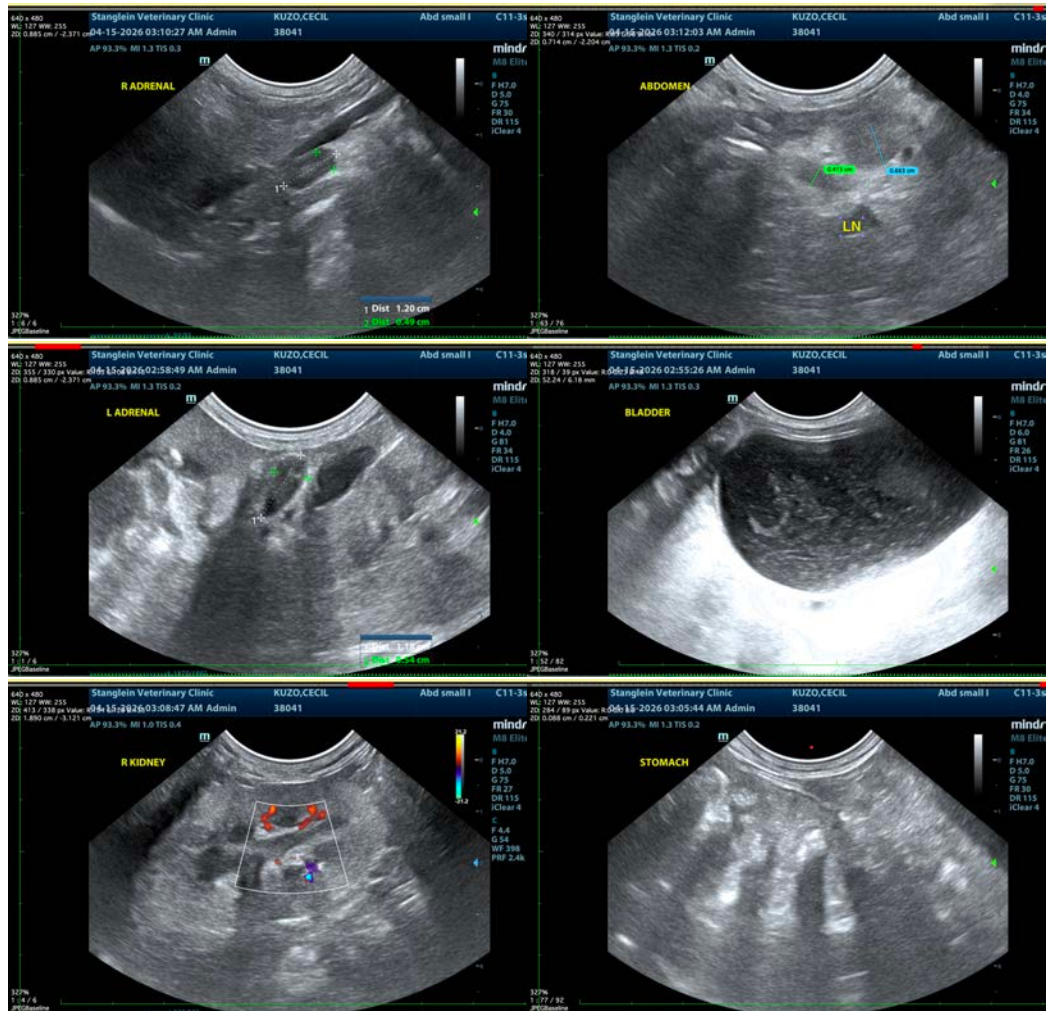
4/15/26

A fecal enteropathogen PCR panel to Texas A&M GI Laboratory could be considered for further evaluation of possible infectious disease. Contact lab for recommendations on how long to discontinue antibiotics (if indicated) prior to obtaining a stool sample for submission.

Ultimately, biopsies of the GI tract, being sure to include ileum, if possible, may be necessary for definitive diagnosis and therefore to further guide medical management.

In the meantime, supportive/symptomatic medical management of clinical signs is recommended, including a probiotic (such as visbiome or proviable), empirical deworming with a 5-day course of Panacur and, if tolerated, a transition in diet, based on trial-and-error response, beginning possibly with a gastrointestinal biome diet vs a hydrolyzed protein diet vs other. Some patients respond to one brand/version of a hydrolyzed protein diet better than another brand, so several brand attempts may be required.

Given patient's reported urinary history, consultation with a veterinary nutritionist could be considered to help manage multiple disease processes that potentially require different diets.





PATIENT

Cecil Kuzo

SPECIES

Feline

BREED

Domestic Shorthair

SEX

Neutered Male

AGE

10 Years 5 Months

WEIGHT

10.55

INTERPRETED BY

Beth Johnson, DVM
DACVIM

IMAGING PERFORMED BY

Jessica Green

HOSPITAL NAME

Stanglein Veterinary
Clinic

REFERRING VET

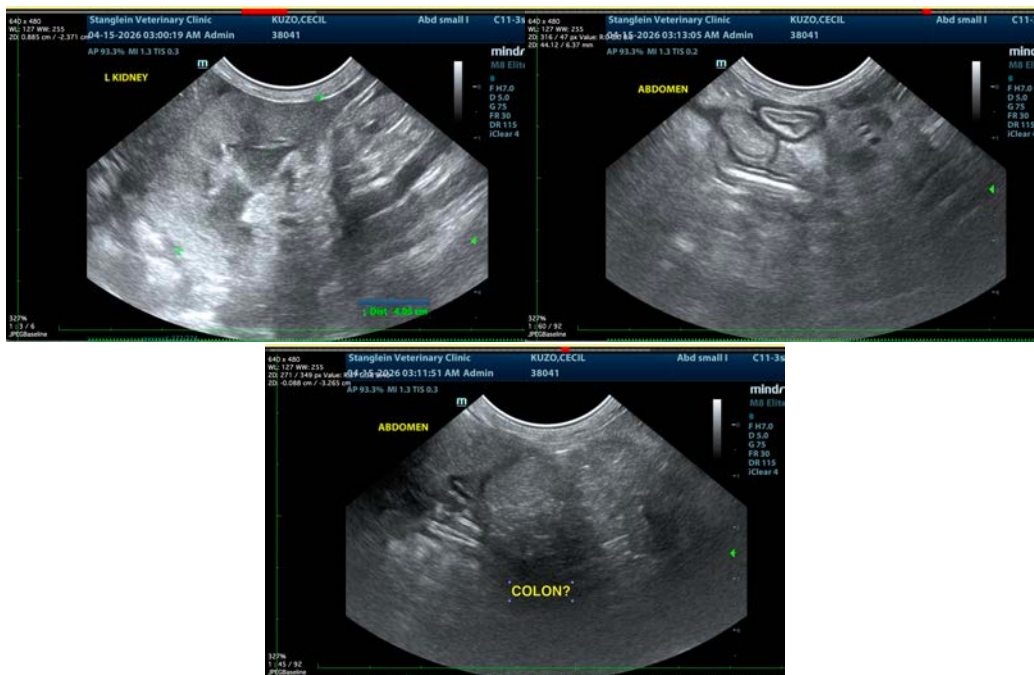
Dr. Laura Green

INVOICE

74492

DATE

4/15/26



The information and recommendations provided are based on the images presented by the referring veterinarian/sonographer. No evaluation can be communicated regarding pathology that was not visible in the image/video clips provided.

Thank you for this referral. If the clinical or image interpretation does not parallel your findings or if I can be of any further assistance please contact me.

Beth Johnson, DVM, DACVIM
info@sonopath.com