



## PATIENT

Hailey Weiner

## SPECIES

Canine

## BREED

Boxer x

## SEX

Spayed Female

## AGE

15 Years

## WEIGHT

40 lbs

## INTERPRETED BY

Beth Johnson, DVM  
DACVIM

## IMAGING PERFORMED BY

Julia Bakker, DVM

## HOSPITAL NAME

Orange Blossom  
Veterinary Imaging

## REFERRING VET

Tiffany Rimar, DVM

## INVOICE

74448

## DATE

4/14/26

## PRESENTING CLINICAL SIGNS

Screening for causes of hematuria. Patient was treated with marbofloxacin for a week for a proteus based UTI. Patient is paraplegic.

## ULTRASONOGRAPHIC EXAMINATION OF THE ABDOMEN

### Urinary System

Urinary bladder is adequately distended with primarily anechoic contents and occasional echogenic non-shadowing debris. Apical urinary bladder wall is diffusely thick (0.70 cm). Mucosa is hyperechoic and irregular. No masses observed. An approximately 0.81 cm x 1.76 cm mineral shadowing density is noted along the dependent inner wall, consistent with either one discrete cystolith or less likely a pile of smaller cystoliths and mineral/sand debris. The trigone and visible pelvic urethra are normal thickness with a smooth mucosal surface.

The right kidney is normal is size (5.75 cm), shape and echogenicity. It has smooth peripheral margination. There is a normal 1:3 cortex to medulla ratio with appropriate corticomedullary distinction. There is no evidence of pyelectasia, mineral or infarcts observed.

The left kidney is normal is size (5.25 cm), shape and echogenicity. It has smooth peripheral margination. There is a normal 1:3 cortex to medulla ratio with appropriate corticomedullary distinction. There is no evidence of pyelectasia, mineral or infarcts observed.

### Adrenal Glands

Adrenal glands are small (flattened contour). Corticomedullary structure is unremarkable. Visible surrounding vasculature appears normal. Left measures 0.44 cm at the cranial pole and 0.37 cm at the caudal pole. Right measures 0.57 cm at the cranial pole and 0.31 cm at the caudal pole.

### Spleen

Spleen is subjectively normal in size with a normal smooth capsular contour. Parenchyma is appropriately finely textured and homogenous with normal echogenicity relative to surrounding tissue (hyperechoic to liver). No focal nodules or masses are observed. Multifocal mineral foci are noted. Splenic vasculature appears normal.

### Liver

The liver is subjectively normal in size with normal smooth curvilinear peripheral contour. Parenchyma is appropriately hypoechoic to the spleen in echogenicity and appropriately mildly coarse and homogenous in echotexture. No focal lesions are observed. Visible vasculature and biliary tree appear normal without distension or congestion.

Gallbladder is moderately distended with anechoic bile as well as suspended and gravity dependent echogenic debris. The wall is smooth without visible thickening. There is no evidence of cystic or CBD dilation. There is no evidence of effusion or inflammation.

### Gastrointestinal

The visible stomach wall is normal in thickness and layering. The lumen of the stomach is mildly distended with a small to moderate amount of echogenic non-shadowing luminal contents and gas



## PATIENT

Hailey Weiner

## SPECIES

Canine

## BREED

Boxer x

## SEX

Spayed Female

## AGE

15 Years

## WEIGHT

40 lbs

## INTERPRETED BY

Beth Johnson, DVM  
DACVIM

## IMAGING PERFORMED BY

Julia Bakker, DVM

## HOSPITAL NAME

Orange Blossom  
Veterinary Imaging

## REFERRING VET

Tiffany Rimar, DVM

## INVOICE

74448

## DATE

4/14/26

consistent with normal ingesta. There is no evidence of obstruction, foreign material or infiltrative disease. Pyloric outflow tract appears patent.

The visible small intestines are normal in wall thickness and layering. Small intestinal motility appears adequate (1-3 contractions per min). The lumen of the small intestine is empty with no evidence of obstruction, foreign material or infiltrative disease.

The visible colon is normal in wall thickness (< 0.2 cm) and layering. Contents are consistent with normal formed feces and gas.

### **Pancreas**

The pancreas that is observed appears appropriately isoechoic to surrounding omental fat. Visible capsule is smooth and normal in contour. Visible pancreatic parenchyma is homogenous and unremarkable. There is no visible pancreatic duct dilation. There is no evidence of active peripancreatic inflammation.

### **Free Abdomen**

There is no visible free peritoneal effusion noted in these images.

There is no apparent pathologic lymphadenopathy noted in these images.

### **ULTRASONOGRAPHIC FINDINGS**

- Chronic Cystitis - Urinary bladder wall changes are most consistent with chronic cystitis. Infiltrative neoplasia cannot be ruled out but is considered less likely give the location and diffuse nature of the changes.
- Suspect cystolith or pile of smaller cystoliths is unable to be definitively ruled out.
- Flat adrenal glands – This can be a normal patient variant and/or a sign of exogenous cortisol administration. If exogenous steroids are not being administered, hypoadrenocorticism (either relative or absolute) should be considered.
- Spleen mineralization – This is a benign change but can be associated with endocrinopathies, especially hyperadrenocorticism.
- Moderate gallbladder debris - Cholecystic debris is of unknown clinical significance. It can be seen with biliary stasis from fasting or illness. Cholecystic debris is not necessarily related to hepatobiliary disease. Echogenic bile is most commonly an incidental finding in dogs and should be interpreted in combination with clinical signs such as nausea, inappetence, cranial abdominal discomfort and/or laboratory changes such as increased ALP and/or increased Tbili.

### **INTERPRETATION OF THE FINDINGS & FURTHER RECOMMENDATIONS**

Urinalysis and, if indicated based on urinalysis results, urine culture is recommended. If protein is present in an otherwise quiet sediment, protein quantification with a urine protein to creatinine ratio is recommended.

Additionally, if not recently evaluated, a full general metabolic health screen is recommended to also include CBC/Chem panel and electrolytes.



**PATIENT**

Hailey Weiner

**SPECIES**

Canine

**BREED**

Boxer x

**SEX**

Spayed Female

**AGE**

15 Years

**WEIGHT**

40 lbs

**INTERPRETED BY**

Beth Johnson, DVM  
DACVIM

**IMAGING PERFORMED BY**

Julia Bakker, DVM

**HOSPITAL NAME**

Orange Blossom  
Veterinary Imaging

**REFERRING VET**

Tiffany Rimar, DVM

**INVOICE**

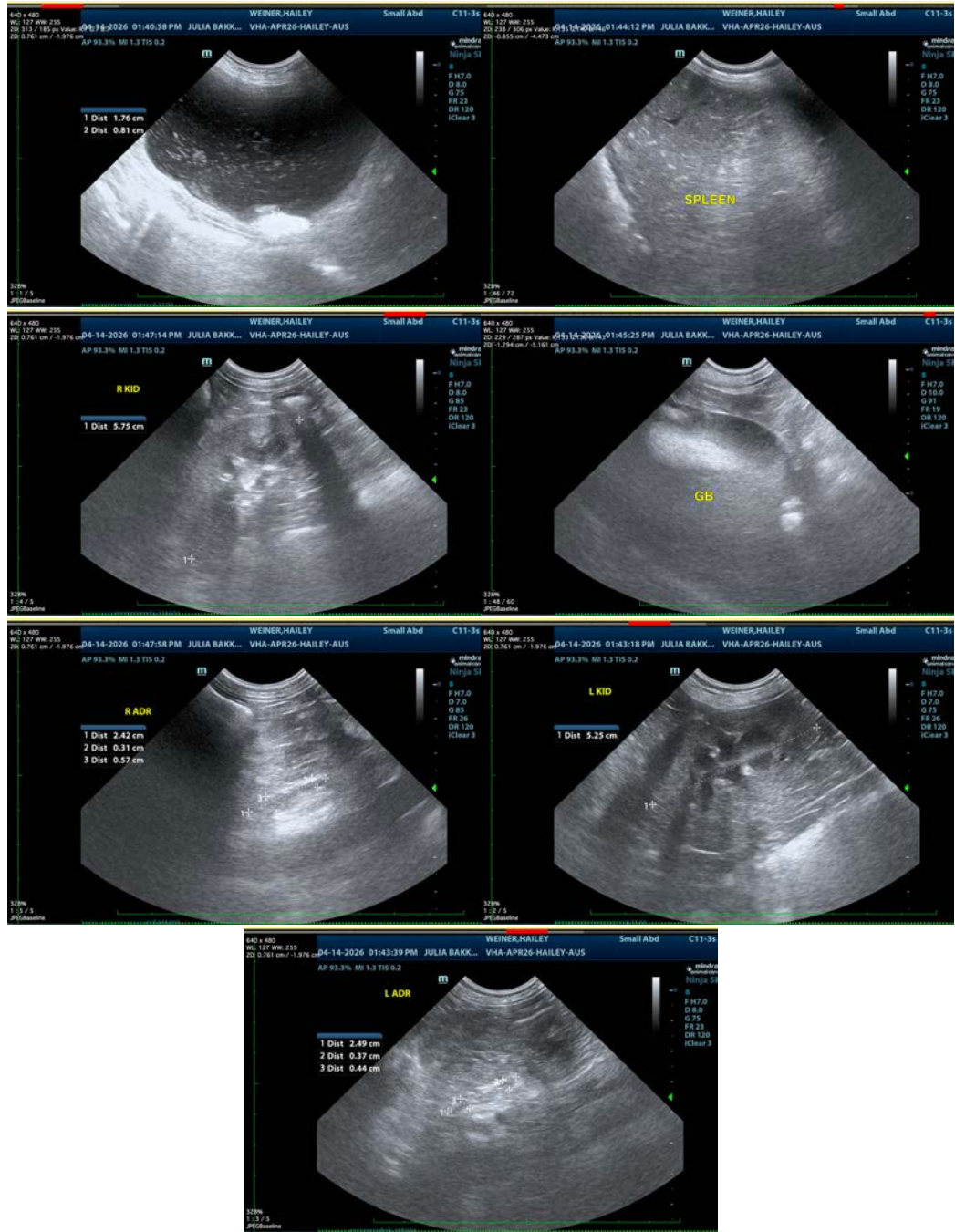
74448

**DATE**

4/14/26

A baseline cortisol is recommended. If baseline cortisol is less than 2, a full ACTH stimulation test is recommended to rule out hypoadrenocorticism.

Other than supportive/symptomatic medical management of clinical signs, further treatment recommendations are largely dependent on results of the above.





## PATIENT

Hailey Weiner

## SPECIES

Canine

## BREED

Boxer x

## SEX

Spayed Female

## AGE

15 Years

## WEIGHT

40 lbs

## INTERPRETED BY

Beth Johnson, DVM  
DACVIM

## IMAGING PERFORMED BY

Julia Bakker, DVM

## HOSPITAL NAME

Orange Blossom  
Veterinary Imaging

## REFERRING VET

Tiffany Rimar, DVM

## INVOICE

74448

## DATE

4/14/26

The information and recommendations provided are based on the images presented by the referring veterinarian/sonographer. No evaluation can be communicated regarding pathology that was not visible in the image/video clips provided.

Thank you for this referral. If the clinical or image interpretation does not parallel your findings or if I can be of any further assistance please contact me.

**Beth Johnson, DVM, DACVIM**  
info@sonopath.com