



PATIENT

Dusty Byrd

SPECIES

Canine

BREED

Labrador Retriever

SEX

Male

AGE

13 Years

WEIGHT

61.2 lbs

INTERPRETED BY

Beth Johnson, DVM
DACVIM

IMAGING PERFORMED BY

Dr. Casper

HOSPITAL NAME

Hometown Animal
Hospital (Florida)

REFERRING VET

Dr. Elizabeth
McMorran

INVOICE

74435

DATE

4/14/26

PRESENTING CLINICAL SIGNS

Senior screen. Hx of arthritis
Abnormal PE/Chem/CBC/UA Results: Senior panel pulled today. 06/2025 labs - NSF

ULTRASONOGRAPHIC EXAMINATION OF THE ABDOMEN

Urinary System

Urinary bladder is only mildly distended (empty). Visible contents are anechoic. Urinary bladder wall is unable to be fully assessed for pathology without further distension. No visible masses or definitive cystoliths are observed. The trigone and visible pelvic urethra are normal thickness with a smooth mucosal surface. In the face of urinary signs and/or suspected urinary bladder pathology, reassessment after complete filling is recommended.

Prostate is symmetrically enlarged (6.6 cm x 4.0 cm) with smooth margins that are well differentiated from surrounding tissue. Normal bilobed shape is maintained. Parenchyma is heterogenous with scattered hyperechoic foci present. No mineral or cysts are noted.

The right kidney is normal is size (5.4 cm), shape and echogenicity. It has smooth peripheral margination. There is a normal 1:3 cortex to medulla ratio with appropriate corticomedullary distinction. There is no evidence of pyelectasia, mineral or infarcts observed.

The left kidney is normal is size (5.9 cm), shape and echogenicity. It has smooth peripheral margination. There is a normal 1:3 cortex to medulla ratio with appropriate corticomedullary distinction. There is no evidence of pyelectasia, mineral or infarcts observed.

Adrenal Glands

The areas of the adrenal glands are examined without evident adrenal gland pathology.

Spleen

The spleen is subjectively normal in size with a normal smooth capsular contour. Parenchyma is appropriately finely textured and homogenous with normal echogenicity relative to surrounding tissue (hyperechoic to liver). No focal nodules or masses are observed. Splenic vasculature appears normal.

Liver

The liver is subjectively normal in size with normal smooth curvilinear peripheral contour. Parenchyma is appropriately hypoechoic to the spleen in echogenicity and appropriately mildly coarse and homogenous in echotexture. No focal lesions are observed. Visible vasculature and biliary tree appear normal without distension or congestion.

Gallbladder is moderately distended with anechoic bile as well as suspended and gravity dependent echogenic debris. The wall is smooth without visible thickening. There is no evidence of cystic or CBD dilation. There is no evidence of effusion or inflammation.

Gastrointestinal

The visible stomach wall is normal in thickness and layering. The lumen of the stomach is mildly distended with a small to moderate amount of echogenic non-shadowing luminal contents and gas consistent with normal ingesta. There is no evidence of obstruction, foreign material or infiltrative disease. Pyloric outflow tract appears patent.



PATIENT

Dusty Byrd

SPECIES

Canine

BREED

Labrador Retriever

SEX

Male

AGE

13 Years

WEIGHT

61.2 lbs

INTERPRETED BY

Beth Johnson, DVM
DACVIM

IMAGING PERFORMED BY

Dr. Casper

HOSPITAL NAME

Hometown Animal
Hospital (Florida)

REFERRING VET

Dr. Elizabeth
McMorran

INVOICE

74435

DATE

4/14/26

The visible small intestines are normal in wall thickness and layering. Small intestinal motility appears adequate (1-3 contractions per min). The lumen is mildly distended with echogenic non-shadowing luminal contents and gas consistent with normal ingesta/chyme. There is no evidence of obstruction, foreign material or infiltrative disease.

The visible colon is normal in wall thickness (< 0.2 cm) and layering. Contents are consistent with normal formed feces and gas.

Pancreas

The pancreas that is observed appears appropriately isoechoic to surrounding omental fat. Visible capsule is smooth and normal in contour. Visible pancreatic parenchyma is homogenous and unremarkable. There is no visible pancreatic duct dilation. There is no evidence of active peripancreatic inflammation.

Free Abdomen

There is no visible free peritoneal effusion noted in these images.

There is no apparent pathologic lymphadenopathy noted in these images.

One of the testicles contains an approximately 1.2 cm x 1.6 cm ovoid, homogeneous, hypo- to almost anechoic appearing density/nodule. A still image of the lesion is provided and labeled "left testicle", but in the videos the lesion is labeled "right testicle".

PRIMARY FINDINGS

- Moderate gallbladder debris - Cholecystic debris is of unknown clinical significance. It can be seen with biliary stasis from fasting or illness. Cholecystic debris is not necessarily related to hepatobiliary disease. Echogenic bile is most commonly an incidental finding in dogs and should be interpreted in combination with clinical signs such as nausea, inappetence, cranial abdominal discomfort and/or laboratory changes such as increased ALP and/or increased Tbili.
- Testicular lesion/nodule - Could represent either a benign or malignant process and can't be differentiated without tissue sampling.

SECONDARY FINDINGS

- Benign Prostatic Hyperplasia - Prostatic findings are most consistent with Benign Prostatic Hyperplasia (BPH) and hyperechoic foci consistent with increased vascularity and fibrosis often associated with BPH. Active prostatitis cannot be ruled out. Infiltrative neoplasia cannot be ruled out but is considered less likely.

INTERPRETATION OF THE FINDINGS & FURTHER RECOMMENDATIONS

Three view thoracic radiographs are recommended for further assessment of cardio-pulmonary status as well as to further evaluate for any evidence of metastatic disease, if not recently evaluated.

If elected, sampling of the testicular nodule or neuter could be considered.

Otherwise, in an asymptomatic patient there are no further recommendations for a largely unremarkable senior exam.



PATIENT

Dusty Byrd

SPECIES

Canine

BREED

Labrador Retriever

SEX

Male

AGE

13 Years

WEIGHT

61.2 lbs

INTERPRETED BY

Beth Johnson, DVM
DACVIM

IMAGING PERFORMED BY

Dr. Casper

HOSPITAL NAME

Hometown Animal Hospital
Hospital (Florida)

REFERRING VET

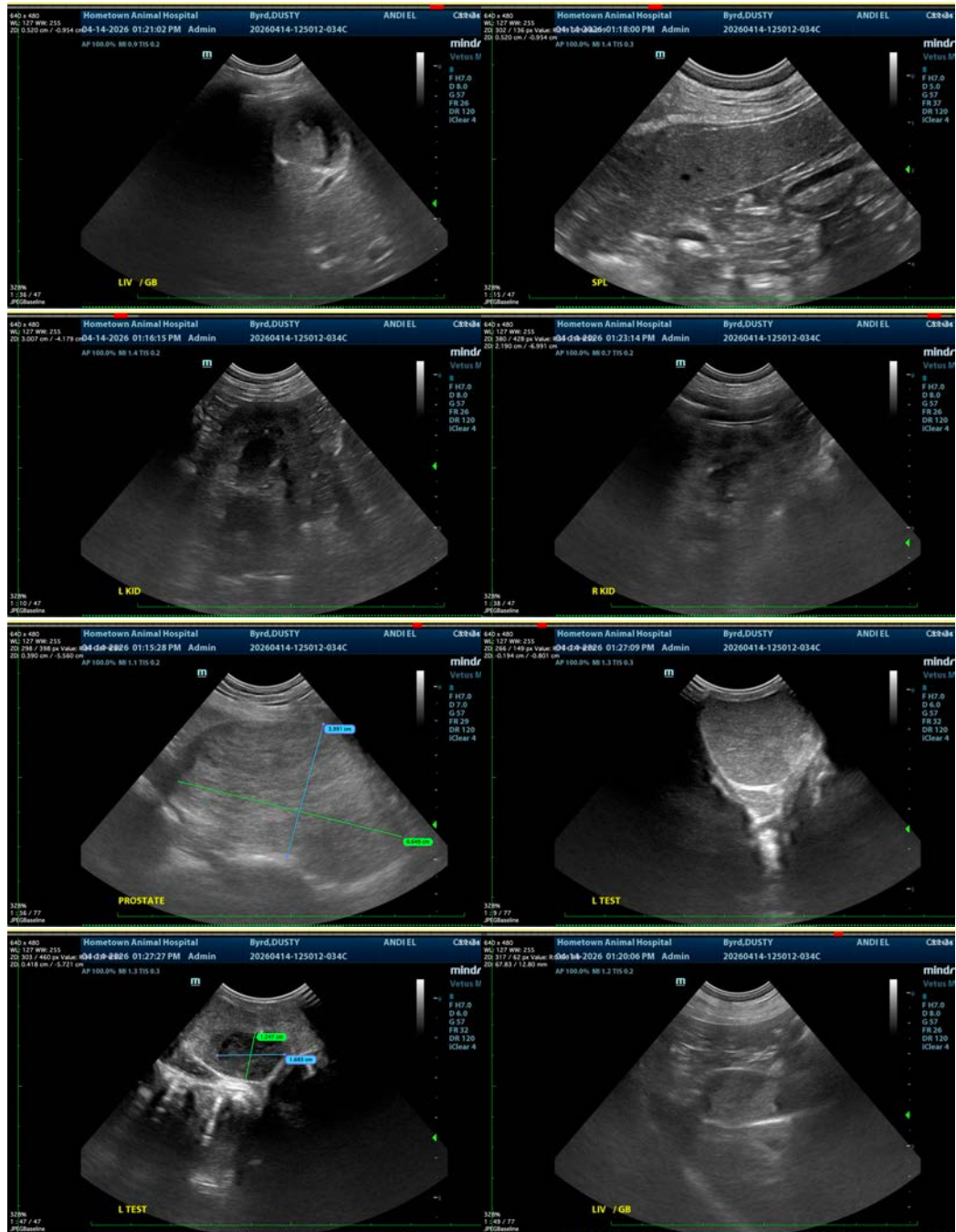
Dr. Elizabeth
McMorran

INVOICE

74435

DATE

4/14/26





PATIENT

Dusty Byrd

SPECIES

Canine

BREED

Labrador Retriever

SEX

Male

AGE

13 Years

WEIGHT

61.2 lbs

INTERPRETED BY

Beth Johnson, DVM
DACVIM

IMAGING PERFORMED BY

Dr. Casper

HOSPITAL NAME

Hometown Animal
Hospital (Florida)

REFERRING VET

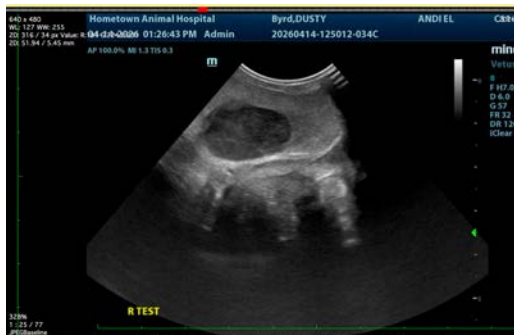Dr. Elizabeth
McMorran

INVOICE

74435

DATE

4/14/26



The information and recommendations provided are based on the images presented by the referring veterinarian/sonographer. No evaluation can be communicated regarding pathology that was not visible in the image/video clips provided.

Thank you for this referral. If the clinical or image interpretation does not parallel your findings or if I can be of any further assistance please contact me.

Beth Johnson, DVM, DACVIM
info@sonopath.com