



PATIENT

Baby Kavanaugh

SPECIES

Feline

BREED

DSH

SEX

Neutered Male

AGE

13 Years 9 Months

WEIGHT

16.4 lbs

INTERPRETED BY

Beth Johnson, DVM
DACVIM

IMAGING PERFORMED BY

Vincent Ravancho, CVT

HOSPITAL NAME

Denville Animal
Hospital

REFERRING VET

Dr. Reddy

INVOICE

74431

DATE

4/14/26

PRESENTING CLINICAL SIGNS

Losing weight, vomiting, controlled by clavamox. Finicky eating.

ULTRASONOGRAPHIC EXAMINATION OF THE ABDOMEN

Urinary System

The urinary bladder is adequately distended with anechoic contents. No masses, inflammatory changes, echogenic sediment or cystoliths are observed. The urinary bladder, trigone and visible pelvic urethra are normal in thickness with a smooth mucosal surface.

The right kidney is normal in size (4.7 cm), shape and echogenicity. It has smooth peripheral margination. There is a normal 1:3 cortex to medulla ratio with appropriate corticomedullary distinction. There is no evidence of pyelectasia, mineral or infarcts observed.

The left kidney is normal in size (4.1 cm), shape and echogenicity. It has smooth peripheral margination. There is a normal 1:3 cortex to medulla ratio with appropriate corticomedullary distinction. There is no evidence of pyelectasia, mineral or infarcts observed.

Adrenal Glands

The right adrenal gland is normal in size (0.60 cm), shape and overall architecture, echogenicity and echotexture. Visible surrounding vasculature appears normal.

The left adrenal gland is normal in size (0.50 cm), shape and overall architecture, echogenicity and echotexture. Visible surrounding vasculature appears normal.

Spleen

The spleen is subjectively normal in size with a normal smooth capsular contour. Parenchyma is appropriately finely textured and homogenous with normal echogenicity relative to surrounding tissue (hyperechoic to liver). No focal nodules or masses are observed. Splenic vasculature appears normal.

Liver

The liver is subjectively normal in size with normal smooth curvilinear peripheral contour. Parenchyma is appropriately hypoechoic to the spleen in echogenicity and appropriately mildly coarse and homogenous in echotexture, except for in the mid liver adjacent to the gallbladder where there is an approximately 3.5 cm x 3.9 cm, largely cystic, mildly hyperechoic density/mass. Visible vasculature and biliary tree appear normal without distension or congestion.

The gallbladder is non-distended in size. The wall is smooth without visible thickening. Luminal contents are primarily anechoic. There is no evidence of cystic or common bile duct dilation.

Gastrointestinal

The visible stomach wall is normal in thickness and layering. The lumen of the stomach is empty with no evidence of obstruction, foreign material or infiltrative disease. Pyloric outflow tract appears patent.

The visible small intestine demonstrates areas of mildly thick muscularis layer relative to mucosa (disruption of the normal 1:3 muscularis:mucosa ratio). Small intestinal submucosa is slightly irregular, thick and hyperechoic, without evident loss of layering appreciated. The lumen of the small intestine is empty with no evidence of obstruction or foreign material.



PATIENT

Baby Kavanaugh

The visible colon is normal in wall thickness (< 0.2 cm) and layering. Contents are consistent with normal formed feces and gas.

SPECIES

Feline

Pancreas

The pancreas that is observed appears appropriately isoechoic to surrounding omental fat. Visible capsule is smooth and normal in contour. Visible pancreatic parenchyma is homogenous and unremarkable. There is no visible pancreatic duct dilation. There is no evidence of active peripancreatic inflammation.

BREED

DSH

Free Abdomen

There is no visible free peritoneal effusion noted in these images.

SEX

Neutered Male

There is no apparent pathologic lymphadenopathy noted in these images.

AGE

13 Years 9 Months

ULTRASONOGRAPHIC FINDINGS

- Feline biliary cystadenoma – In a senior cat, this liver lesion is most consistent with a benign biliary cystadenoma. Malignancy cannot be ruled out but is considered less common. Interpret in combination with clinical signs, laboratory changes, etc.
- Very mild/subtle inflammatory bowel disease (IBD) pattern – Thick muscularis has been reported with infiltrative bowel disease including both benign inflammatory disease as well as infiltrative neoplasia such as lymphoma. No loss of layering or distinct characteristics of malignancy are present. Therefore, differentials cannot be further ranked without tissue sampling. *This change is very mild and could be in part normal patient variant in a senior cat.

WEIGHT

16.4 lbs

INTERPRETED BY

Beth Johnson, DVM
DACVIM

INTERPRETATION OF THE FINDINGS & FURTHER RECOMMENDATIONS

If not recently evaluated, a general metabolic health screen (CBC, chemistry panel with electrolytes and urinalysis) is recommended.

IMAGING PERFORMED BY

Vincent Ravancho, CVT

A T4 +/- free T4 are recommended.

HOSPITAL NAME

Denville Animal Hospital

Given the subtle bowel changes, a gastrointestinal malabsorption panel (including cobalamin, folate, TLI and PLI) to Texas A&M GI Laboratory is recommended for further evaluation of GI and pancreatic function.

REFERRING VET

Dr. Reddy

Three view thoracic radiographs are recommended for further assessment of cardio-pulmonary status as well as to further evaluate for any evidence of metastatic disease, if not recently evaluated.

Fine needle aspirates of the liver could be considered if patient's coagulation status is appropriate.

INVOICE

74431

Other than supportive/symptomatic medical management of clinical signs, further treatment recommendations are largely dependent on results of the above.

DATE

4/14/26



PATIENT

Baby Kavanaugh

SPECIES

Feline

BREED

DSH

SEX

Neutered Male

AGE

13 Years 9 Months

WEIGHT

16.4 lbs

INTERPRETED BY

Beth Johnson, DVM
DACVIM

IMAGING PERFORMED BY

Vincent Ravancho, CVT

HOSPITAL NAME

Denville Animal
Hospital

REFERRING VET

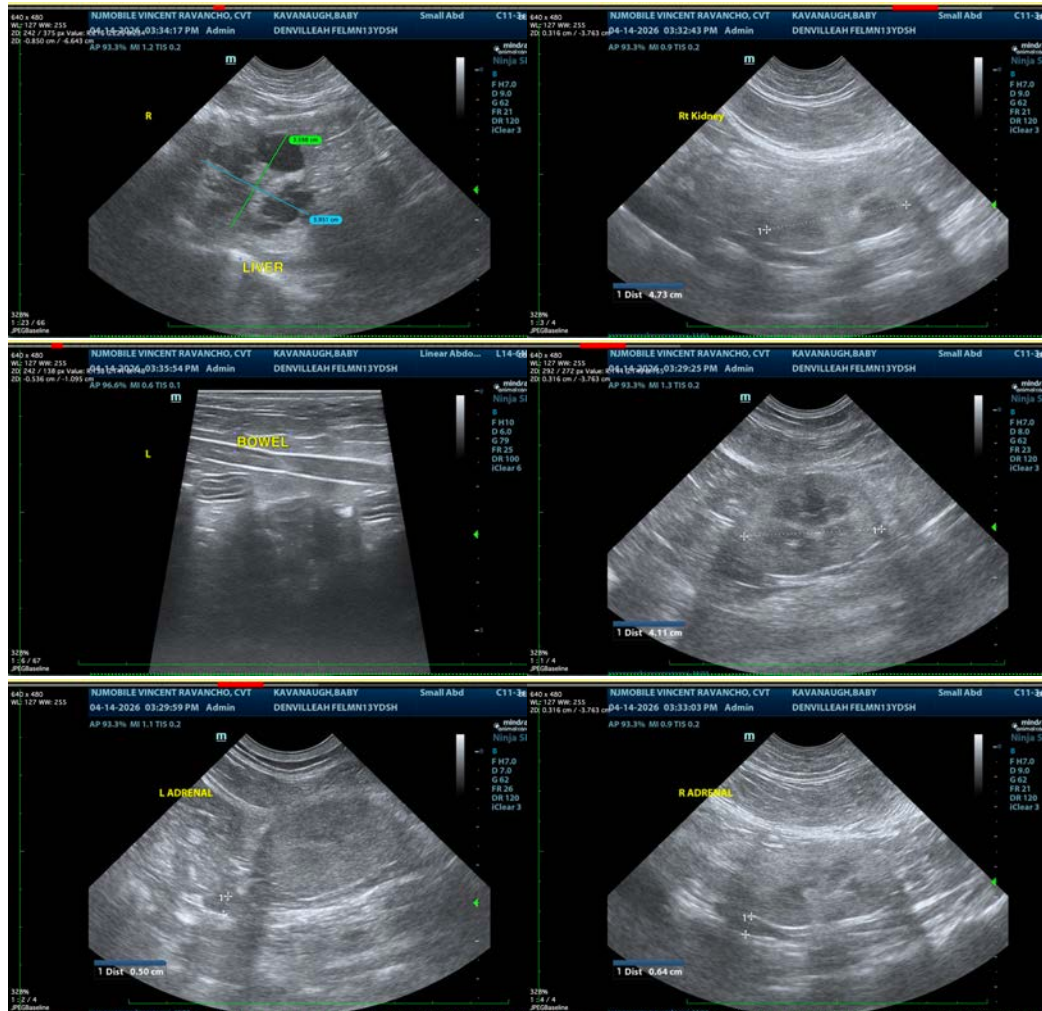
Dr. Reddy

INVOICE

74431

DATE

4/14/26



The information and recommendations provided are based on the images presented by the referring veterinarian/sonographer. No evaluation can be communicated regarding pathology that was not visible in the image/video clips provided.

Thank you for this referral. If the clinical or image interpretation does not parallel your findings or if I can be of any further assistance please contact me.

Beth Johnson, DVM, DACVIM
info@sonopath.com