

**PATIENT**

Daisy Ameloot

SPECIES

Canine

BREED

Pit Bull

SEX

Spayed Female

AGE

5 Years

WEIGHT

63.6 Pounds

INTERPRETED BYBeth Johnson, DVM
DACVIM**IMAGING PERFORMED BY**

Amy Mayhew, LVT

HOSPITAL NAME

SVS Imaging MI

REFERRING VET

Dr. Rivas

INVOICE

46662

DATE

4/13/23

PRESENTING CLINICAL SIGNS

Urinating in house, Hypothyroidism possible, Addison's due to long term steroids, pancreatitis, seborrhea, recent BW showed elevated blood glucose.

ULTRASONOGRAPHIC EXAMINATION OF THE ABDOMEN**Urinary System**

Urinary bladder is adequately distended. It has a normal uniform wall thickness. Contents include primarily anechoic fluid with occasional echogenic non-shadowing debris, most consistent with exfoliated cells, mucous and/or small blood clots. Both sterile inflammation as well as urinary tract infection can also present with echogenic debris. No masses or cystoliths are observed. The trigone and visible pelvic urethra are normal in thickness with a smooth mucosal surface.

The right kidney is normal in size (6.3 cm), shape and echogenicity. It has smooth peripheral margination. There is a normal 1:3 cortex to medulla ratio with appropriate corticomedullary distinction. There is no evidence of pyelectasia, mineral or infarcts observed.

The left kidney is normal in size (6.49 cm), shape and echogenicity. It has smooth peripheral margination. There is a normal 1:3 cortex to medulla ratio with appropriate corticomedullary distinction. There is no evidence of pyelectasia, mineral or infarcts observed.

Adrenal Glands

Adrenal glands are small (flattened contour). Corticomedullary structure is unremarkable. Visible surrounding vasculature appears normal. The left adrenal gland measured 0.40 cm at the cranial pole and 0.35 cm at the caudal pole. The right adrenal gland measured 0.39 cm at the cranial pole and 0.33 cm at the caudal pole.

Spleen

The spleen is subjectively normal in size with a normal smooth capsular contour. Parenchyma is appropriately finely textured and homogenous with normal echogenicity relative to surrounding tissue (hyperechoic to liver). No focal nodules or masses are observed. Splenic vasculature appears normal.

Liver

The liver is subjectively normal in size with normal smooth curvilinear peripheral contour. Parenchyma is appropriately hypoechoic to the spleen in echogenicity and appropriately mildly coarse and homogenous in echotexture. No focal lesions are observed. Visible vasculature and biliary tree appear normal without distension or congestion.

Gallbladder is moderately distended with anechoic bile as well as moderate suspended and gravity dependent echogenic debris. The wall is smooth without visible thickening. There is no evidence of cystic or CBD dilation. There is no evidence of effusion or inflammation.

Gastrointestinal

The visible stomach wall is normal in thickness and layering. The stomach is moderately distended with echogenic non-shadowing luminal contents and gas consistent with normal ingesta. There is no evidence of obstruction, foreign material or infiltrative disease. However, given the reported history of fasting, delayed gastric emptying could be considered. Soft (cloth) fluid absorbing foreign material is considered less likely but cannot be definitively ruled out. If clinical signs are consistent (vomiting, etc.), recommendations include supportive medical care, 24 hours fasting and re-image.

The visible small intestines are normal in wall thickness and layering (canine duodenum < 0.5 cm and feline duodenum < 0.4 cm; other < 0.3 cm). Small intestinal motility appears adequate (1-3 contractions

IMAGING PERFORMED BY

SVS Mobile Imaging MI 734-637-7711
svsimagingmi@gmail.com



PATIENT

Daisy Ameloot

SPECIES

Canine

BREED

Pit Bull

SEX

Spayed Female

AGE

5 Years

WEIGHT

63.6 Pounds

INTERPRETED BY

Beth Johnson, DVM
DACVIM

IMAGING PERFORMED BY

Amy Mayhew, LVT

HOSPITAL NAME

SVS Imaging MI

REFERRING VET

Dr. Rivas

INVOICE

46662

DATE

4/13/23

per min). The lumen of the small intestine is empty with no evidence of obstruction, foreign material or infiltrative disease.

The visible colon is normal in wall thickness (< 0.2 cm) and layering. Contents are consistent with normal formed feces and gas.

Pancreas

The pancreatic parenchyma is appropriately isoechoic to surrounding tissue. Visible capsule is smooth and normal in contour. There is no visible pancreatic duct dilation. There is no evidence of active peripancreatic inflammation.

Free Abdomen

There is no evidence of free peritoneal effusion noted in these images.

There is no apparent lymphadenopathy noted in these images.

ULTRASONOGRAPHIC FINDINGS

- Urinary bladder debris
- **Flat adrenal glands** – consistent with this patient's steroid history.
- **Moderate gallbladder debris** - Cholecystic debris is of unknown clinical significance. It can be seen with biliary stasis from fasting or illness. Cholecystic debris is not necessarily related to hepatobiliary disease. Echogenic bile is most commonly an incidental finding in dogs and should be interpreted in combination with clinical signs such as nausea, inappetence, cranial abdominal discomfort and/or laboratory changes such as increased ALP and/or increased Tbili.

INTERPRETATION OF THE FINDINGS & FURTHER RECOMMENDATIONS

Given this patient's reported new history of mild hyperglycemia and urinary accidents in the house, if not very recently evaluated, a urinalysis and, if indicated based on urinalysis results, urine culture are recommended. If protein is present in an otherwise quiet sediment, protein quantification with a urine protein to creatinine ration is recommended.

If possible, to maintain quality of life with this patient's reported dermatologic disease, tapering and ultimately discontinuing steroids is recommended to help better manage early or hopefully transient diabetes mellitus. In the meantime, very close monitoring of the blood glucoses is recommended to help determine when and if insulin therapy is necessary.

Given the combination of competing medical problems in this patient, consultation with a veterinary dermatologist for therapies other than steroids, as well as consultation with a veterinary internist for help managing diabetes in the face of steroids, etc. should be considered.

IMAGING PERFORMED BY

SVS Mobile Imaging MI 734 - 637 - 7711
svsimagingmi@gmail.com



PATIENT

Daisy Ameloot

SPECIES

Canine

BREED

Pit Bull

SEX

Spayed Female

AGE

5 Years

WEIGHT

63.6 Pounds

INTERPRETED BY

Beth Johnson, DVM
DACVIM

IMAGING PERFORMED BY

Amy Mayhew, LVT

HOSPITAL NAME

SVS Imaging MI

REFERRING VET

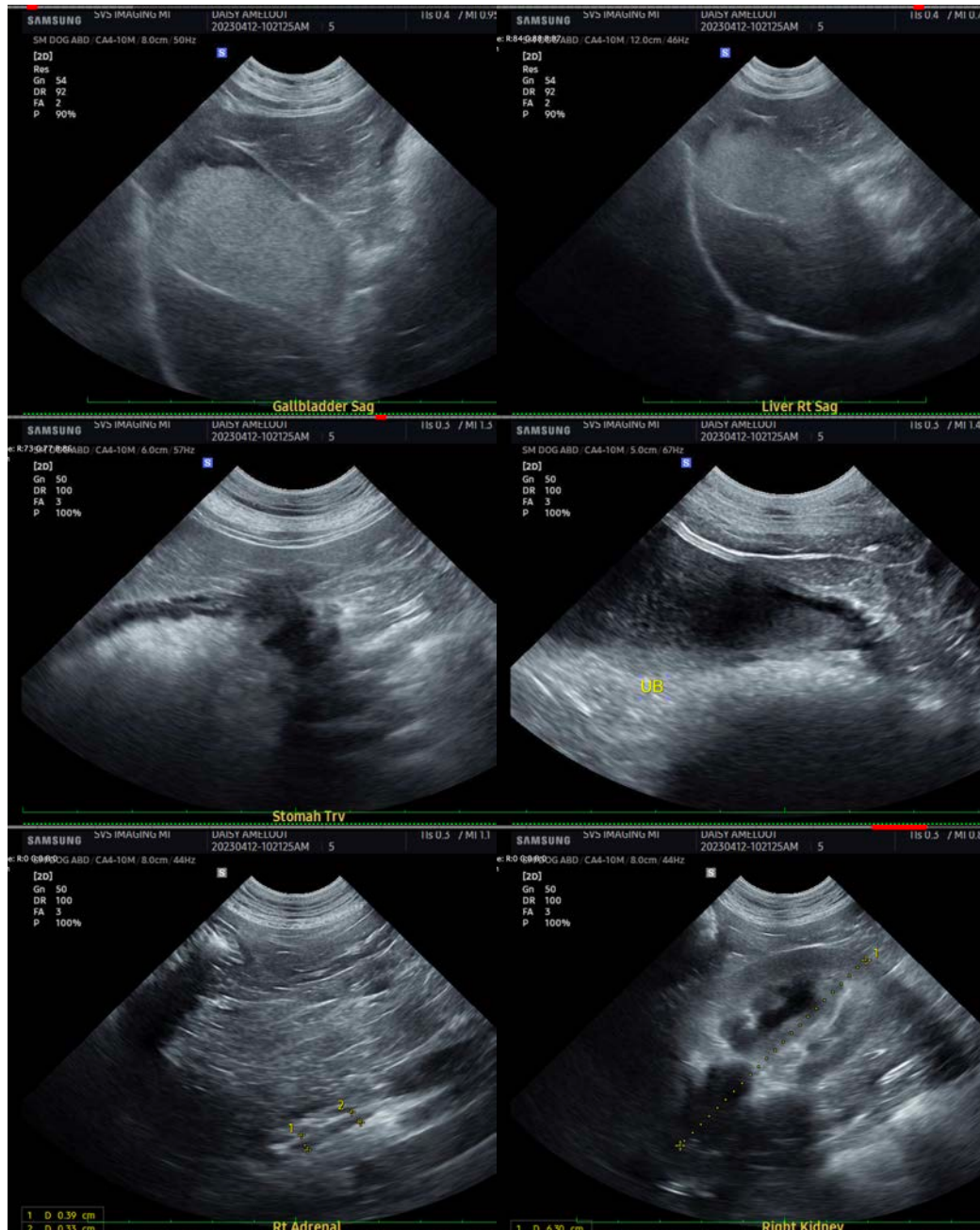
Dr. Rivas

INVOICE

46662

DATE

4/13/23



IMAGING PERFORMED BY

SVS Mobile Imaging MI 734 - 637 - 7711
svsimagingmi@gmail.com



PATIENT

Daisy Ameloot

SPECIES

Canine

BREED

Pit Bull

SEX

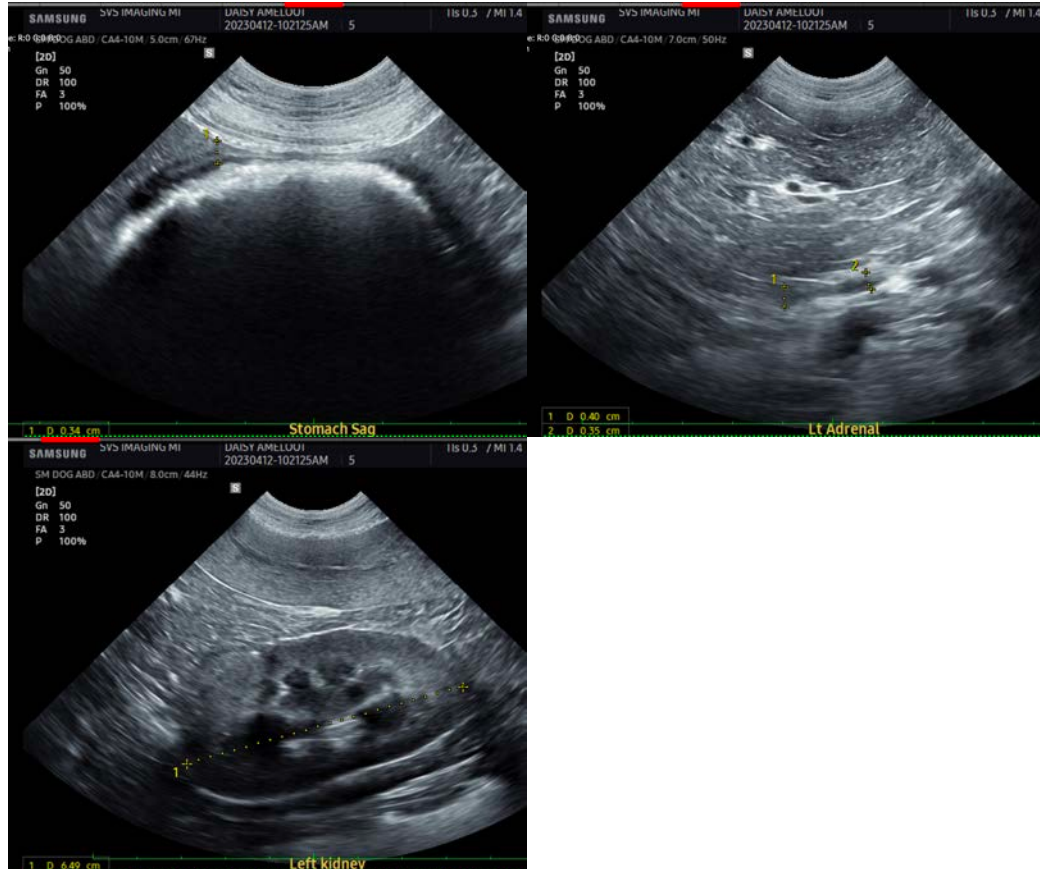
Spayed Female

AGE

5 Years

WEIGHT

63.6 Pounds



INTERPRETED BY

Beth Johnson, DVM
DACVIM

IMAGING PERFORMED BY

Amy Mayhew, LVT

HOSPITAL NAME

SVS Imaging MI

REFERRING VET

Dr. Rivas

INVOICE

46662

DATE

4/13/23

The information and recommendations provided are based on the images presented by the referring veterinarian/sonographer. No evaluation can be communicated regarding pathology that was not visible in the image/video clips provided.

Thank you for this referral. If the clinical or image interpretation does not parallel your findings or if I can be of any further assistance please contact me.

Beth Johnson, DVM, DACVIM
Beth.Johnson@sonopath.com