

**DATE PRESENTING CLINICAL SIGNS**

4/12/23

Pet presented for routine senior exam on 3/23/23. Owner raised concerns for pet's skin as well as some possible PU/PD. On PE periodontal disease was appreciated. A left sided renomegaly was

PATIENT

Lucy Wilhide

appreciated. Alopecia was noted on the dorsal tail region and medial aspect of both thighs as well as both axillas with mild erythema. Pet was vaccinated and given Cytopoint as well as senior bloodwork was completed. Bloodwork results listed below, abdominal US and Low dose dexamethasone suppression test recommended for pet

SPECIES

Canine

Current Medications: None.

Lab Results: 03/23/23: Snap 4DX: NEGATIVE X 4. CBC: Reticulocyte Hemoglobin: 24.4pg (24.5-31.8); Platelets: 677K/uL (143-448);

BREED

Boston Terrier

Chemistry: Albumin: 4.0g/dL (2.7-3.9); ALT: 328U/L (18-121); ALP: 4,344U/L (5-160); GGT: 69U/L (0-13). UA: USG: 1.006; Protein: 1+;

Date of Previous IntraPet Ultrasound: No previous.

Sedation: Not required to complete full diagnostic ultrasound.

Stat Report: Not requested.

Imaging Performed By: Rachel Brillhart, RDMS.

SEX

Spayed Female

ULTRASONOGRAPHIC EXAMINATION OF THE ABDOMEN**AGE**

4/29/10

Urinary System

The urinary bladder is moderately distended with anechoic contents. No masses, inflammatory changes, echogenic sediment or cystoliths are observed. The urinary bladder, trigone and visible pelvic urethra are normal in thickness with a smooth mucosal surface.

WEIGHT

25.6 Pounds

Kidneys are overall normal in size and shape with smooth peripheral margination. A normal 1:3 cortex to medulla ratio is maintained. The medulla and cortices are uniform in texture with some mild increased cortical echogenicity and mild loss of corticomedullary distinction, expected in this age patient. There is no evidence of mineral or infarcts observed. Pyelectasia noted bilaterally, 0.72 cm in the right kidney and 0.36 cm the left kidney (sagittal view measurements).

INTERPRETED BYBeth Johnson, DVM
DACVIM**HOSPITAL NAME**

Westminster VH

Adrenal Glands

Adrenal glands are plump/swollen in size. Normal shape and contour are maintained without evidence of capsular invasion. Some parenchymal heterogeneity is present without concerning capsular distortion. Visible surrounding vasculature appears normal. The right adrenal gland measures 3.0 cm long x 0.95 cm at the cranial pole and 0.95 cm at the caudal pole. The left adrenal gland measured 2.65 cm long x 0.81 cm at the cranial pole and 0.98 cm at the caudal pole.

REFERRING VET

Dr. Hall

Spleen

The spleen is subjectively normal in size with a normal smooth capsular contour. Parenchyma is appropriately finely textured and homogenous with normal echogenicity relative to surrounding tissue (hyperechoic to liver). No focal nodules or masses are observed. Splenic vasculature appears normal.

INVOICE

46627

Liver

Liver is subjectively enlarged with mildly irregular margins. Parenchyma is heterogenous characterized by multiple poorly defined hypoechoic nodules within otherwise hyperechoic liver parenchyma. Visible vasculature and biliary tree appear normal without distension or congestion.

Gallbladder is moderately distended with anechoic bile as well as mild suspended and gravity dependent echogenic debris. The wall is smooth without visible thickening. There is no evidence of cystic or CBD dilation. There is no evidence of effusion or inflammation.

Gastrointestinal

The stomach wall is normal in thickness (canine < 0.5 cm and feline < 0.4 cm) and layering. The lumen of the stomach is empty with no evidence of obstruction, foreign material or infiltrative disease. Pyloric outflow tract appears patent.

The visible small intestines are normal in wall thickness and layering (canine duodenum < 0.5 cm and feline duodenum < 0.4 cm; other < 0.3 cm). Small intestinal motility appears adequate (1-3 contractions per min). The lumen of the small intestine is empty with no evidence of obstruction, foreign material or infiltrative disease.

The visible colon is normal in wall thickness (< 0.2 cm) and layering. Contents are consistent with normal formed feces and gas.

Pancreas

The observed pancreas appears appropriately isoechoic to surrounding omental fat. The capsule is mildly irregular in shape. Parenchyma is mildly heterogenous and coarse. There is no visible pancreatic duct dilation. There is no evidence of active peripancreatic inflammation.

Free Abdomen

There is no evidence of free peritoneal effusion noted in these images.

There is no apparent lymphadenopathy noted in these images.

PRIMARY FINDINGS

- **Bilateral adrenomegaly** – consistent with adrenal hyperplasia secondary to pituitary dependent hyperadrenocorticism vs stress or normal variant. Interpret in combination with clinical signs of hyperadrenocorticism.
- **Heterogenous Liver** – These changes are most consistent with benign processes such as nodular hyperplasia, steroid (vacuolar) hepatopathy, extramedullary hematopoiesis or possibly chronic inflammatory disease and less commonly infiltrative round cell or metastatic neoplasia.
- **Mild gallbladder debris** - Cholecystic debris is of unknown clinical significance. It can be seen with biliary stasis from fasting or illness. Cholecystic debris is not necessarily related to hepatobiliary disease. Echogenic bile is most commonly an incidental finding in dogs and should be interpreted in combination with clinical signs such as nausea, inappetence, cranial abdominal discomfort and/or laboratory changes such as increased ALP and/or increased Tbili.

SECONDARY FINDINGS

- **Age related kidney changes with bilateral pyelectasia** – consistent with this patient's history of PU/PD, although infection/pyelonephritis can't be ruled out.
- **Pancreatic age-related remodeling** – Mild irregularities are consistent with benign age-related change. Low-grade smoldering chronic pancreatitis cannot be ruled out and should be suspected in the face of appropriate clinical signs.

INTERPRETATION OF THE FINDINGS & FURTHER RECOMMENDATIONS

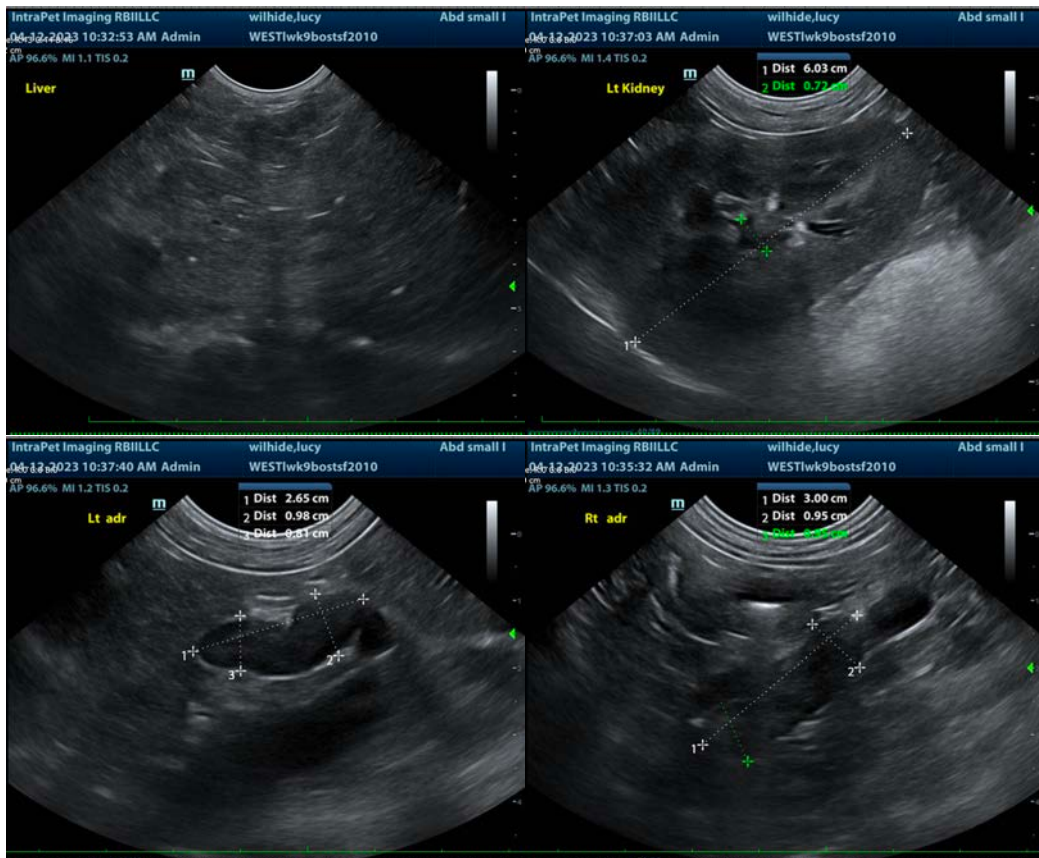
The described adrenal gland, liver and gallbladder changes are all suggestive of hyperadrenocorticism. Given the reported clinical signs also suggestive of hyperadrenocorticism, further testing is recommended:

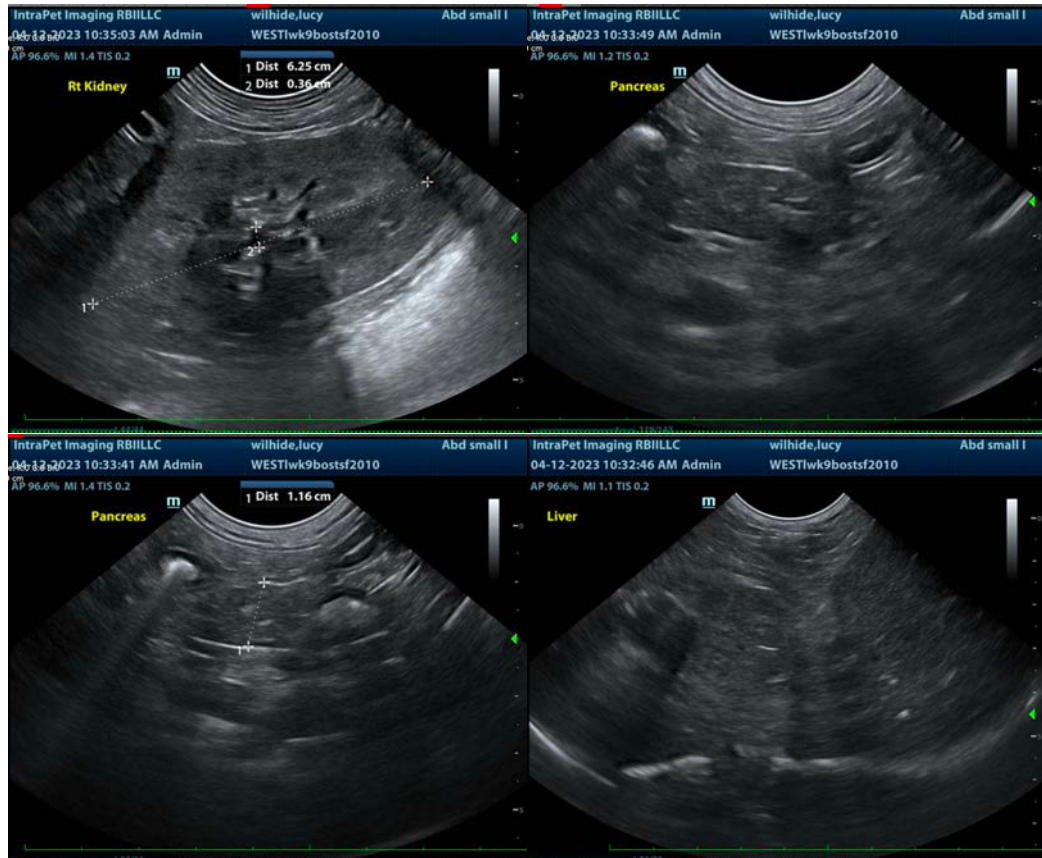
A LDDS test is warranted.

If a LDDS test has been evaluated with a normal result, investigation of possible atypical hyperadrenocorticism with a full ACTH stimulation adrenal panel to the University of Tennessee could be considered.

If not recently evaluated, blood pressure is recommended.

Additionally, if not recently evaluated, a urinalysis and, if indicated based on urinalysis results, urine culture is also recommended. If protein is present in an otherwise quiet sediment, protein quantification with a urine protein to creatinine ratio is recommended.





The information and recommendations provided are based on the images presented by the referring veterinarian/sonographer. No evaluation can be communicated regarding pathology that was not visible in the image/video clips provided.

Thank you for this referral. If the clinical or image interpretation does not parallel your findings or if I can be of any further assistance please contact me.

Beth Johnson, DVM, DACVIM
Beth.Johnson@sonopath.com