



**PATIENT**

Misty Cofield

**SPECIES**

Canine

**BREED**

Basset Hound X

**SEX**

Spayed Female

**AGE**

10 Years 5 Months

**WEIGHT**

67 Pounds

**INTERPRETED BY**

Beth Johnson, DVM  
DACVIM

**IMAGING PERFORMED BY**

Dr. Ashley Whitesell

**HOSPITAL NAME**

Dickson Animal Clinic

**REFERRING VET**

Dr. Ashley Whitesell

**INVOICE**

46554

**DATE**

**PRESENTING CLINICAL SIGNS**

Routine wellness bloodwork revealed high liver values  
Abnormal PE/Chem/CBC/UA Results: ALT 196; alk phos 3004;

**ULTRASONOGRAPHIC EXAMINATION OF THE ABDOMEN**

**Urinary System**

The urinary bladder is moderately distended with anechoic contents. No masses, inflammatory changes, echogenic sediment or cystoliths are observed. The urinary bladder, trigone and visible pelvic urethra are normal in thickness with a smooth mucosal surface.

The right kidney is normal in size (6.99 cm), shape and echogenicity. It has smooth peripheral margination. There is a normal 1:3 cortex to medulla ratio with appropriate corticomedullary distinction. There is no evidence of pyelectasia, mineral or infarcts observed.

The left kidney is normal in size (6.46 cm), shape and echogenicity. It has smooth peripheral margination. There is a normal 1:3 cortex to medulla ratio with appropriate corticomedullary distinction. There is no evidence of pyelectasia, mineral or infarcts observed.

**Adrenal Glands**

The area of the right adrenal gland is examined without evident pathology.

The left adrenal gland is normal in size (0.67 cm at the cranial pole and 0.68 cm at the caudal pole), shape and contour. Corticomedullary structure is unremarkable. Visible surrounding vasculature appears normal.

**Spleen**

Spleen is subjectively normal in size with a normal smooth capsular contour. Parenchyma is appropriately finely textured and homogenous with normal echogenicity relative to surrounding tissue (hyperechoic to liver). Multifocal well-demarcated hyperechoic homogenous nodules are noted. Splenic vasculature appears normal.

**Liver**

Liver is subjectively enlarged with mildly irregular margins. Parenchyma is heterogenous characterized by multiple poorly defined hypoechoic nodules within otherwise hyperechoic liver parenchyma. Additionally, there are multifocal discrete hyperechoic nodules throughout the liver parenchyma. Visible vasculature and biliary tree appear normal without distension or congestion.

The gallbladder is non-distended in size. The wall is smooth without visible thickening. Luminal contents are primarily anechoic. There is no evidence of cystic or common bile duct dilation.

**Gastrointestinal**

The visible stomach wall is normal in thickness and layering. The lumen of the stomach is mildly distended with echogenic non-shadowing luminal contents and gas consistent with normal ingesta. There is no evidence of obstruction, foreign material or infiltrative disease. Pyloric outflow tract appears patent.

The visible small intestines are normal in wall thickness and layering (canine duodenum < 0.5 cm and feline duodenum < 0.4 cm; other < 0.3 cm). Small intestinal motility appears adequate (1-3 contractions per min). The lumen of the small intestine is empty with no evidence of obstruction, foreign material or infiltrative disease.



**PATIENT**

Misty Cofield

The visible colon is normal in wall thickness (< 0.2 cm) and layering. Contents are consistent with normal formed feces and gas.

**SPECIES**

Canine

**Pancreas**

The pancreatic parenchyma is appropriately isoechoic to surrounding tissue. Visible capsule is smooth and normal in contour. There is no visible pancreatic duct dilation. There is no evidence of active peripancreatic inflammation.

**BREED**

Basset Hound X

**Free Abdomen**

There is no evidence of free peritoneal effusion noted in these images.

**SEX**

Spayed Female

There is no apparent lymphadenopathy noted in these images.

**AGE**

10 Years 5 Months

**ULTRASONOGRAPHIC FINDINGS**

- **Heterogenous Liver** – These changes are most consistent with benign processes such as nodular hyperplasia, steroid (vacuolar) hepatopathy, extramedullary hematopoiesis or possibly chronic inflammatory disease and less commonly infiltrative round cell or metastatic neoplasia.
- **Liver nodules** – Differentials for discrete liver nodules include primarily benign changes such as nodular hyperplasia, fibrosis of an old hematoma, granuloma, myelolipoma etc.; however, while considered less likely, primary hepatic neoplasia, infiltrative round cell neoplasia and metastatic disease can mimic benign lesions and cannot be definitively ruled out.
- **Hyperechoic splenic nodules** – most consistent with benign myelolipomas. Other differentials such as fibrosis or calcification caused by old hematomas or infarcts, chronic inflammation, granulomatous disease or metastatic disease cannot be ruled out, but are considered less likely.

**WEIGHT**

67 Pounds

**INTERPRETED BY**

Beth Johnson, DVM  
DACVIM

**INTERPRETATION OF THE FINDINGS & FURTHER RECOMMENDATIONS**

Differentials for increased ALP are vast and non-specific. Differentials include, but are not limited to, benign nodular hyperplasia which occurs in 70% of older dogs and often does not result in an abnormal ultrasound, reactive or idiopathic/vacuolar hepatopathy, cholestasis and/or hyperadrenocorticism as well as many chronic non-hepatobiliary diseases such as chronic infections/inflammation from dental disease, IBD, neoplasia, hyperlipidemia, hypothyroidism, chronic pancreatitis, chronic stress, etc.

**IMAGING PERFORMED BY**

Dr. Ashley Whitesell

There is no ultrasonographic evidence of cholestasis. Adrenocortical testing such as a low dose dexamethasone suppression test could be considered if clinical signs of hyperadrenocorticism are present. Ursodiol could be considered if gallbladder sludge is noted. A fine needle aspirate of the liver could be considered if patient's coagulation status is appropriate. Otherwise, recommendations include addressing any other concurrent disease and monitoring. If values are progressive, recheck imaging is recommended.

**HOSPITAL NAME**

Dickson Animal Clinic

**REFERRING VET**

Dr. Ashley Whitesell

**INVOICE**

46554

Given this patient's reported history, fasted triglyceride level is also recommended, in case idiopathic hypertriglyceridemia has contributed to a cholestatic hepatopathy, in which case options include a low-fat diet if tolerated as a starting point.

**DATE**



**PATIENT**

Misty Cofield

**SPECIES**

Canine

**BREED**

Basset Hound X

**SEX**

Spayed Female

**AGE**

10 Years 5 Months

**WEIGHT**

67 Pounds

**INTERPRETED BY**

Beth Johnson, DVM  
DACVIM

**IMAGING PERFORMED BY**

Dr. Ashley Whitesell

**HOSPITAL NAME**

Dickson Animal Clinic

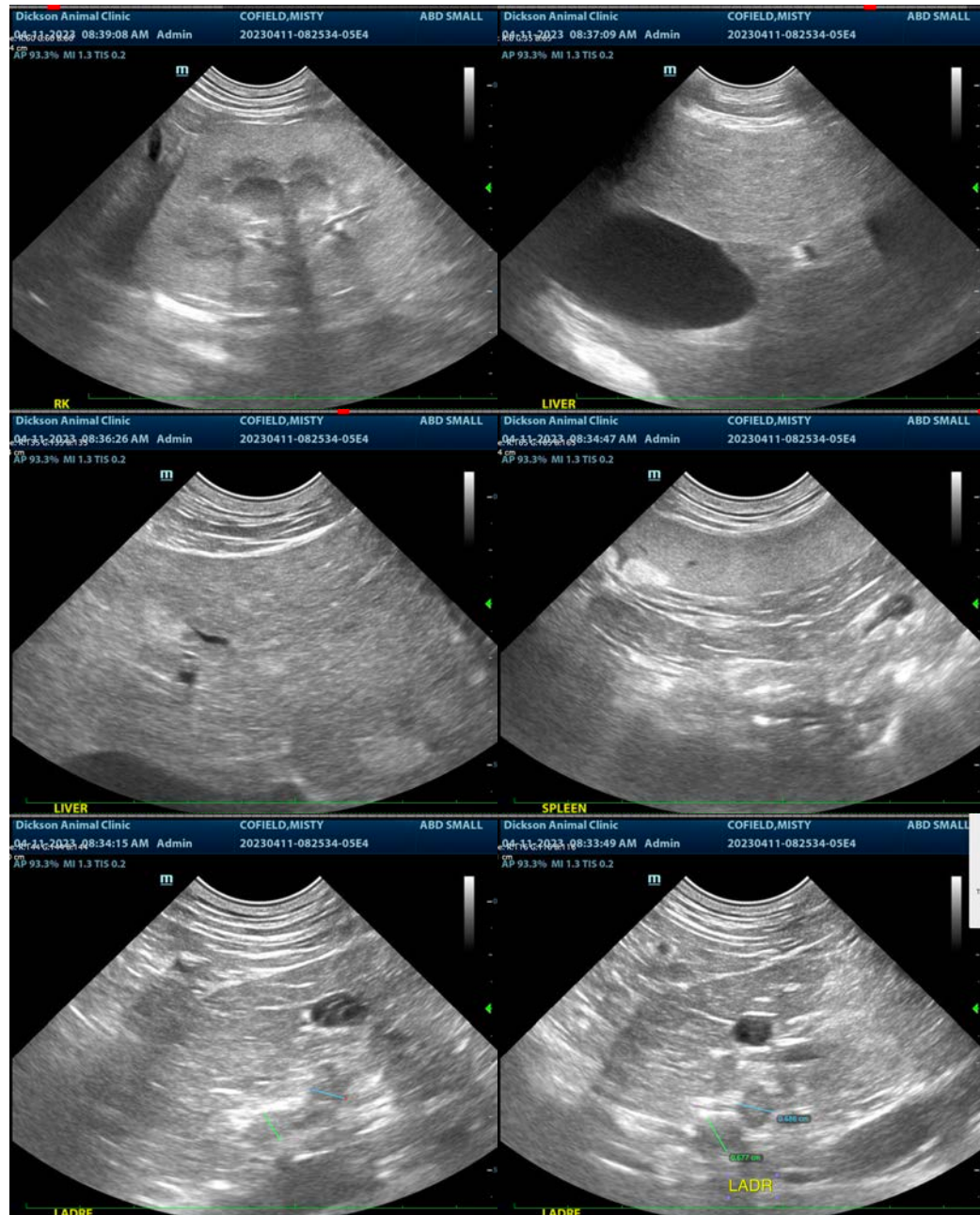
**REFERRING VET**

Dr. Ashley Whitesell

**INVOICE**

46554

**DATE**





**PATIENT**

Misty Cofield

**SPECIES**

Canine

**BREED**

Basset Hound X

**SEX**

Spayed Female

**AGE**

10 Years 5 Months

**WEIGHT**

67 Pounds

**INTERPRETED BY**

Beth Johnson, DVM  
DACVIM

**IMAGING  
PERFORMED BY**

Dr. Ashley Whitesell

**HOSPITAL NAME**

Dickson Animal Clinic

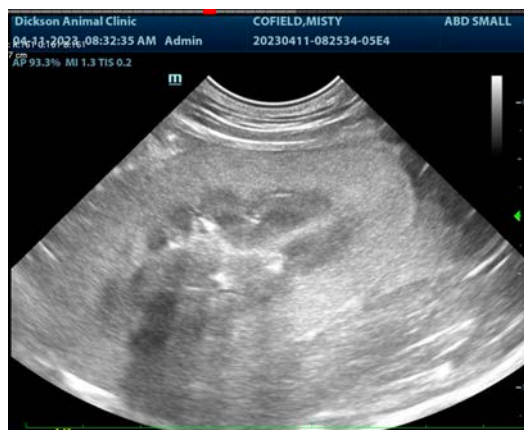**REFERRING VET**

Dr. Ashley Whitesell

**INVOICE**

46554

**DATE**



The information and recommendations provided are based on the images presented by the referring veterinarian/sonographer. No evaluation can be communicated regarding pathology that was not visible in the image/video clips provided.

Thank you for this referral. If the clinical or image interpretation does not parallel your findings or if I can be of any further assistance please contact me.

**Beth Johnson, DVM, DACVIM**  
Beth.Johnson@sonopath.com