

**DATE PRESENTING CLINICAL SIGNS**

4/10/23

History: Frequent, urgent urination with pronounced stranguria for several months. Mild improvement on antibiotics but never resolved. Last urine culture grew only contaminant. On radiographs, bladder does not appear to be emptying fully when P urinates.

PATIENT

Penny Scherger

Current Medications: Enrofloxacin, discontinued 4/5.

Lab Results: UA: Mildly increased WBC; markedly increased epithelial cells; no bacteria seen.

SPECIES

Date of Previous IntraPet Ultrasound: No previous.

Canine

Sedation: Not required to complete full diagnostic ultrasound.

BREED

Stat Report: Not requested.

Imaging Performed By: Stephanie Warga RDCS, RVT.

Dachshund Mix

ULTRASONOGRAPHIC EXAMINATION OF THE ABDOMEN**SEX****Urinary System**

Spayed Female

Urinary bladder is adequately distended with primarily anechoic contents combined with some echogenic suspended debris. There is a heterogenous, vascular, mineralized mass occluding the trigone and extending approximately 4.0 cm into the proximal urethra. No distinct cystoliths are observed.

AGE

2/1/13

Left kidney is normal in size (5.41 cm), shape and echogenicity. It has smooth peripheral margination. There is a normal 1:3 cortex to medulla ratio with appropriate corticomedullary distinction. There is no evidence of mineral or infarcts observed. Pyelectasia is present, measuring 0.62 cm in the transverse view.

WEIGHT

Hydroureters are appreciated to the level of the urinary bladder.

21.6 Pounds

A thin rim of right renal cortex is the only tissue present, surrounding a markedly fluid dilated right renal pelvis/collecting system. Narrow bands of hyperechoic tissue extend from the capsule towards the hilus. The right kidney measures 6.34 cm. Hydroureters are appreciated to the level of the urinary bladder.

INTERPRETED BY**Adrenal Glands**Beth Johnson, DVM
DACVIM

Left adrenal gland is normal in size (1.55 cm long x 0.5 cm at cranial pole and 0.51 cm at caudal pole), shape and overall architecture, echogenicity and echotexture. Visible surrounding vasculature appears normal.

HOSPITAL NAME

Right adrenal gland is normal in size (1.82 cm long x 0.6 cm at cranial pole and 0.5 cm at caudal pole), shape and overall architecture, echogenicity and echotexture. Visible surrounding vasculature appears normal.

Bay Country VH

Spleen**REFERRING VET**

Spleen is subjectively normal in size with a normal smooth capsular contour. Parenchyma is appropriately finely textured and homogenous with normal echogenicity relative to surrounding tissue (hyperechoic to liver). No focal nodules or masses are observed. Splenic vasculature appears normal.

Dr. McLean

Liver**INVOICE**

Liver is subjectively normal in size with normal smooth curvilinear peripheral contour. Parenchyma is appropriately hypoechoic to the spleen in echogenicity and appropriately mildly coarse and homogenous in echotexture. No focal lesions are observed. Visible vasculature and biliary tree appear normal without distension or congestion.

21933

Gallbladder is non-distended in size. The wall is smooth without visible thickening. Luminal contents are primarily anechoic. There is no evidence of cystic or common bile duct dilation.

Gastrointestinal

The visible stomach wall is normal in thickness and layering. The lumen of the stomach is mildly distended with very echogenic reverberation artifact from intraluminal gas. There is no evidence of obstruction, foreign material or infiltrative disease; however, complete visualization of far wall is partially inhibited by gas. Pyloric outflow tract appears patent.

The visible small intestines are normal in wall thickness and layering. Small intestinal motility appears adequate (1-3 contractions per min). The lumen of the small intestine is empty with no evidence of obstruction, foreign material or infiltrative disease.

The visible colon is normal in wall thickness and layering. Contents are consistent with normal formed feces and gas.

Pancreas

The observed pancreas appears appropriately isoechoic to surrounding omental fat. Visible capsule is smooth and normal in contour. Visible pancreatic parenchyma is homogenous and unremarkable. There is no visible pancreatic duct dilation. There is no evidence of active peripancreatic inflammation.

Free Abdomen

There is no evidence of peritoneal effusion. The sublumbar lymph nodes are enlarged with swollen irregular capsular contour and loss of normal length to width ratio (rounded in shape). Nodes are hypoechoic with loss of normal parenchymal detail.

ULTRASONOGRAPHIC FINDINGS

- Urinary bladder mass – Urinary bladder wall/proximal urethra changes are most concerning for infiltrative neoplasia such as transitional cell carcinoma vs other. Benign inflammatory disease (cystitis) cannot be ruled out but is considered less likely given the location and appearance of the tissue.
- Aggressive sublumbar lymph nodes – most consistent with infiltrative round cell or metastatic neoplasia. A benign aggressive inflammatory response cannot be ruled out without tissue sampling +/- culture.
- Bilateral hydroureters, right hydronephrosis and left pyelectasia are concerning for obstruction, likely caused by the mass. Secondary infection/pyelonephritis cannot be definitively ruled out.

INTERPRETATION OF THE FINDINGS & FURTHER RECOMMENDATIONS

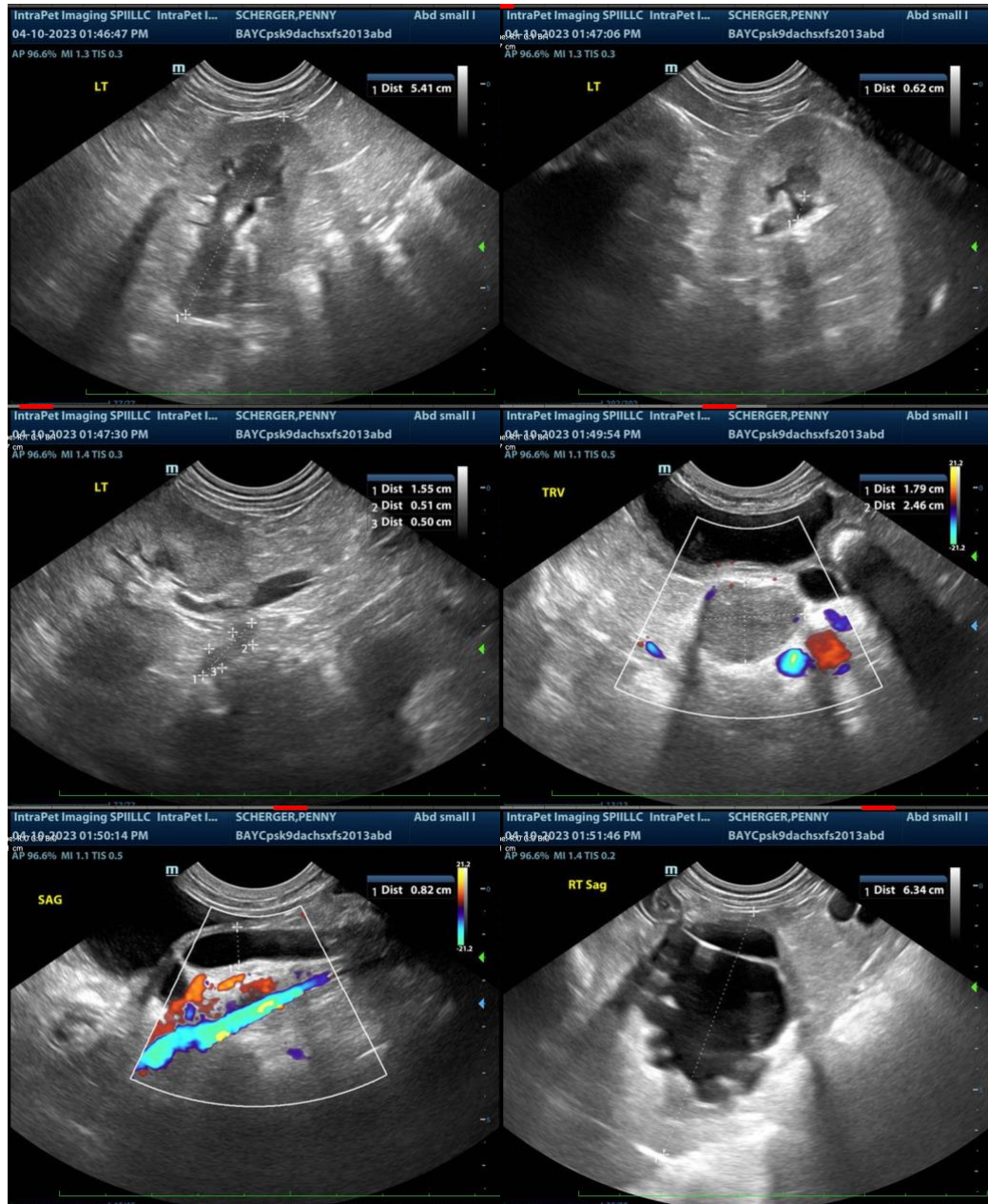
Given the location of the mass described above, surgical excision is likely not a treatment option. Therefore, recommendations include:

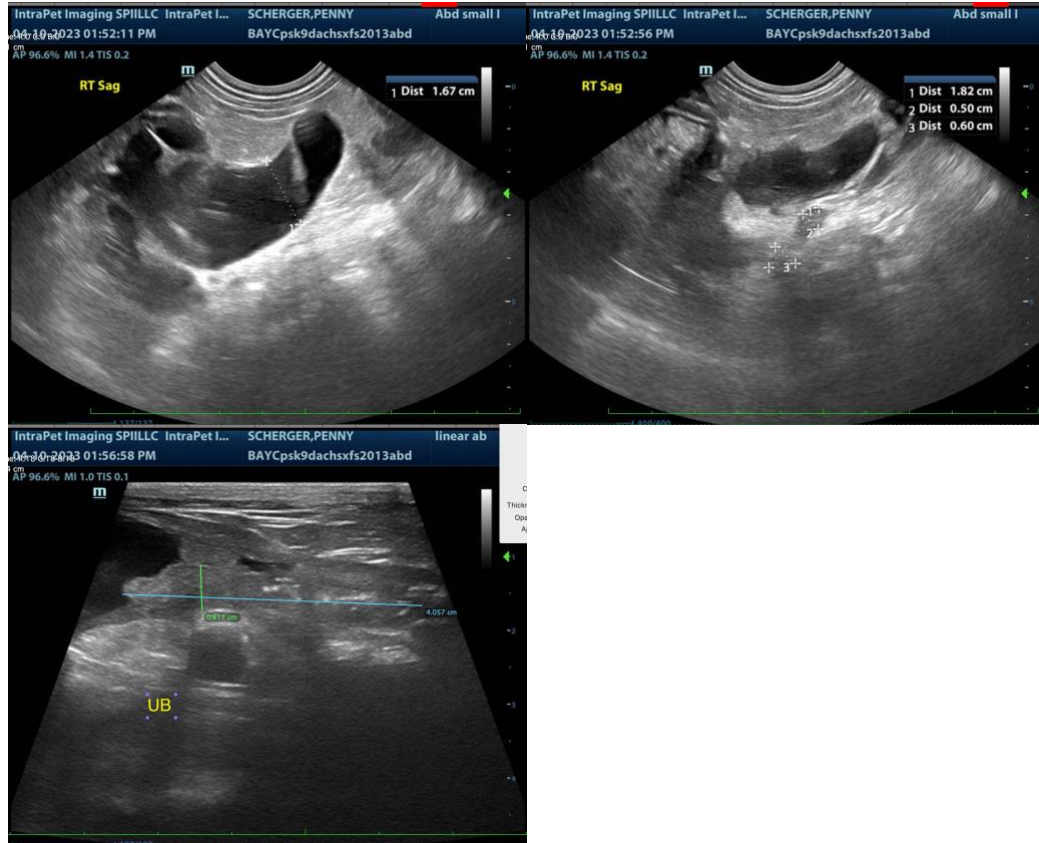
Urinalysis and urine culture, if indicated based on urinalysis results, are recommended. Submission of urine to look for BRAF gene mutation, which is associated with urinary bladder/prostate cancer, could be considered. Other diagnostic options include traumatic catheterization, fine needle aspirate (with small risk of tumor seeding/trailing) or cystoscopy for further sampling. In the meantime, empirical therapy with a broad-spectrum antibiotic (or ideally an antibiotic based on culture and sensitivity results) as well as an anti-inflammatory (unless otherwise contraindicated based on patient co-morbidities) may begin to help alleviate clinical signs.

Three view thoracic radiographs are recommended for further assessment of cardio-pulmonary status as well as to further evaluate for any evidence of metastatic disease, if not recently evaluated.

Pending results, as is reportedly already in place, antibiotic therapy based on culture and sensitivity results, as well as anti-inflammatory therapy may help begin alleviating clinical signs.

Additionally, consultation with a veterinary oncologist should be considered.





The information and recommendations provided are based on the images presented by the referring veterinarian. No evaluation can be communicated regarding pathology that was not visible in the image/video clips provided.

Thank you for this referral. If the clinical or image interpretation does not parallel your findings or if I can be of any further assistance please contact me.

Beth Johnson, DVM DACVIM
Beth.Johnson@SonoPath.com