

**DATE PRESENTING CLINICAL SIGNS**

4/10/23

History: Increased liver enzymes, mineralized density in the area of the spleen noted on x-rays. No symptoms was here for a routine dental cleaning.

PATIENT

Harper Zebron

Current Medications: None listed.

Lab Results: See attached.

Radiographs: Small mineralized area in the L cranial abdomen overlying the opacity of the spleen.

SPECIES

Canine

Date of Previous IntraPet Ultrasound: No previous.

Sedation: Not required to complete full diagnostic ultrasound.

Stat Report: Not requested.

BREED

Welsch Corgi

Imaging Performed By: Stephanie Warga RDCS, RVT.

ULTRASONOGRAPHIC EXAMINATION OF THE ABDOMEN**SEX**

Spayed Female

Urinary System

Urinary bladder is adequately distended with anechoic contents. No masses, inflammatory changes, echogenic sediment or cystoliths are observed. The urinary bladder, trigone and visible pelvic urethra are normal in thickness with a smooth mucosal surface.

AGE

2/2/16

Left kidney is normal is size (5.0 cm), shape and echogenicity. It has smooth peripheral margination. There is a normal 1:3 cortex to medulla ratio with appropriate corticomedullary distinction. There is no evidence of pyelectasia, mineral or infarcts observed.

WEIGHT

30.5 Pounds

Right kidney is normal is size (5.6 cm), shape and echogenicity. It has smooth peripheral margination. There is a normal 1:3 cortex to medulla ratio with appropriate corticomedullary distinction. There is no evidence of pyelectasia, mineral or infarcts observed.

INTERPRETED BYBeth Johnson, DVM
DACVIM**Adrenal Glands**

Left adrenal gland is normal in size (2.13 cm long x 0.44 cm at cranial pole and 0.47 cm at caudal pole), shape and overall architecture, echogenicity and echotexture. Visible surrounding vasculature appears normal.

HOSPITAL NAME

Bayside AMC

Right adrenal gland is normal in size (2.15 cm long x 0.46 cm at cranial pole and 0.48 cm at caudal pole), shape and overall architecture, echogenicity and echotexture. Visible surrounding vasculature appears normal.

REFERRING VET

Dr. DeLozier

Spleen

Spleen is subjectively normal in size with a normal smooth capsular contour. Parenchyma is appropriately finely textured and homogenous with normal echogenicity relative to surrounding tissue (hyperechoic to liver). No focal nodules or masses are observed. Splenic vasculature appears normal.

INVOICE

21939

Liver

Liver is subjectively normal in size with normal smooth curvilinear peripheral contour. Parenchyma is appropriately hypoechoic to the spleen in echogenicity and appropriately mildly coarse and homogenous in echotexture. No focal lesions are observed. Visible vasculature and biliary tree appear normal without distension or congestion.

Gallbladder is non-distended in size. The wall is smooth without visible thickening. Luminal contents are primarily anechoic. There is no evidence of cystic or common bile duct dilation.

Gastrointestinal

The visible stomach wall is normal in thickness and layering. The lumen of the stomach is empty with no evidence of obstruction, foreign material or infiltrative disease. Pyloric outflow tract appears patent.

The visible small intestines are normal in wall thickness and layering. Small intestinal motility appears adequate (1-3 contractions per min). The lumen of the small intestine is empty with no evidence of obstruction, foreign material or infiltrative disease.

The visible colon is normal in wall thickness and layering. Contents are consistent with normal formed feces and gas.

Pancreas

The observed pancreas appears appropriately isoechoic to surrounding omental fat. Visible capsule is smooth and normal in contour. Visible pancreatic parenchyma is homogenous and unremarkable. There is no visible pancreatic duct dilation. There is no evidence of active peripancreatic inflammation.

Free Abdomen

There is no evidence of peritoneal effusion. There is no apparent lymphadenopathy.

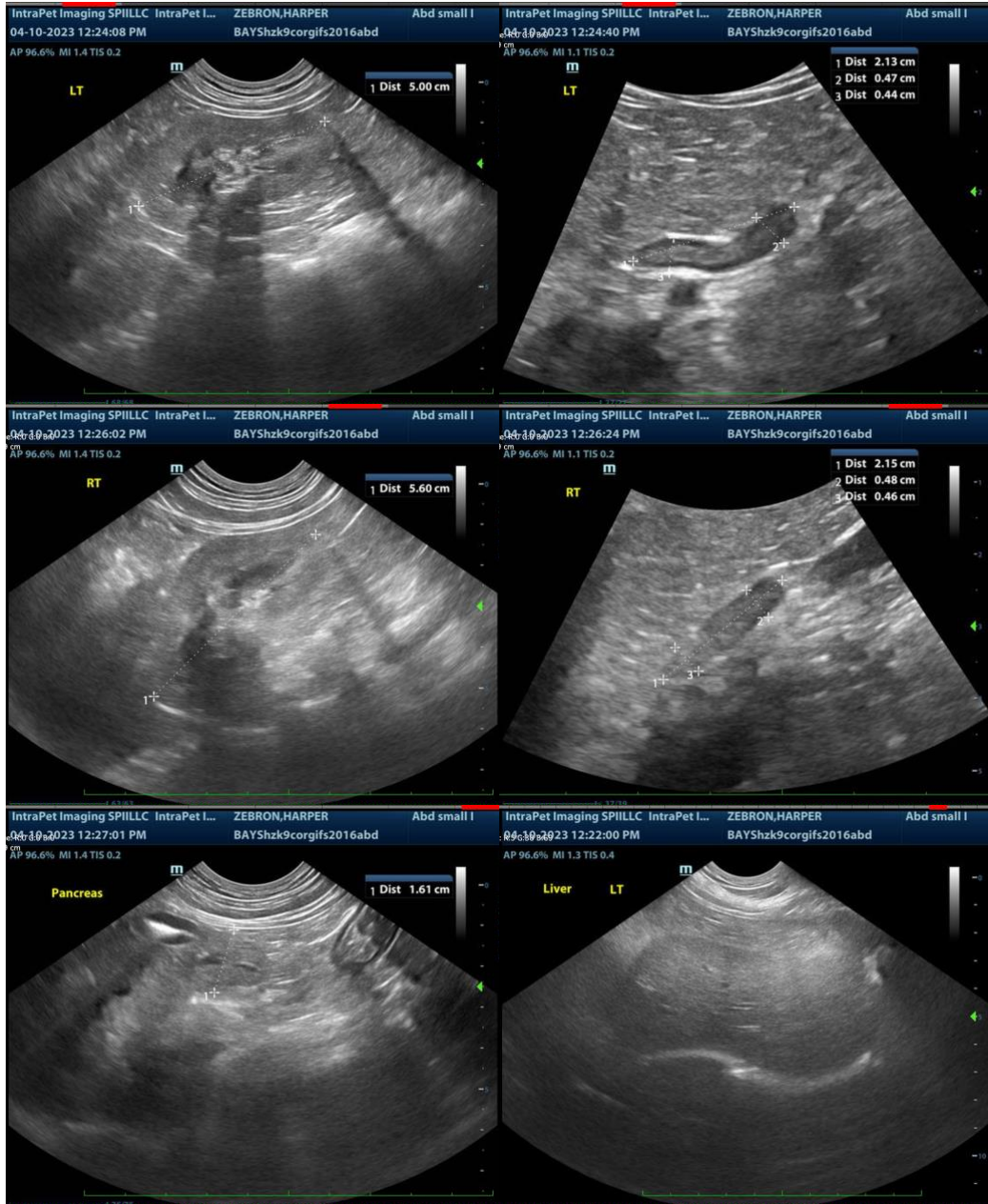
ULTRASONOGRAPHIC FINDINGS

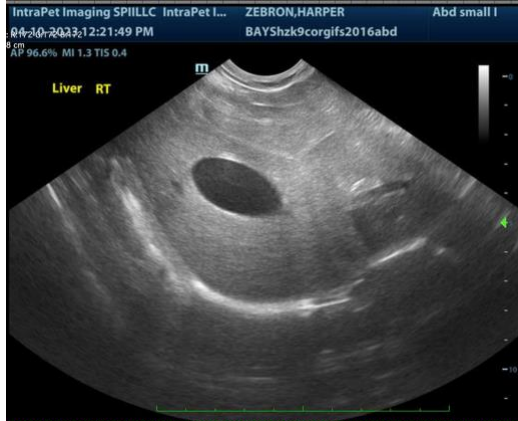- This is a relatively unremarkable/normal abdomen
- An obvious cause for the reported increased liver enzymes is not identified in these images. Microscopic disease such as Leptospirosis, bacterial cholangiohepatitis, chronic active hepatitis, copper-associated hepatotoxicity, other hepatotoxicity, infiltrative neoplasia (considered unlikely), etc. cannot be definitively ruled out.

INTERPRETATION OF THE FINDINGS & FURTHER RECOMMENDATIONS

Depending on the degree or severity of dental disease, dental disease alone can result in mild increases in ALT. Having said that, there are no definitive ultrasonographic contraindications to proceeding with this patient's planned dental procedure, and if so, monitoring of liver enzymes for either improvement vs progression following the procedure to be considered.

Alternatively, if a more definitive work up of the liver is desired prior to the dental cleaning, recommendations include an "antigen search" for sources of reactive hepatopathy (including testing for Leptospirosis), followed by a course of empirical antibiotics and hepatic nutraceuticals, with monitoring of ALT for improvement. If improvement is noted, antibiotics should be continued until liver enzymes either normalize or plateau (recheck every 2-3 weeks); however, if improvement is not noted and/or enzyme increase progresses, antibiotics should not be continued long term and sampling, beginning with a FNA of the liver if patient's coagulation status is appropriate or progressing to a liver biopsy (including copper level assessment) may ultimately be warranted.





The information and recommendations provided are based on the images presented by the referring veterinarian. No evaluation can be communicated regarding pathology that was not visible in the image/video clips provided.

Thank you for this referral. If the clinical or image interpretation does not parallel your findings or if I can be of any further assistance please contact me.

Beth Johnson, DVM DACVIM
Beth.Johnson@SonoPath.com