SonoPath
Clinical Sonography & Telecytology

EDUCATIONAL TELECONSULTATION SERVICES™

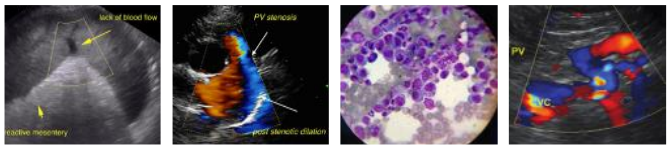

SonoPath.com
1-800-838-4268 info@sonopath.com

PATIENT

August Blatteneerger

SPECIES

Canine

BREED

Jack Russel Terrier

SEX

Spayed Female

AGE

10

WEIGHT

32.8

INTERPRETED BY

Beth Johnson, DVM DACVIM

IMAGING PERFORMED BY

Adrianne Waffle

HOSPITAL NAME

Torch Lake VC

REFERRING VET

Adrianne Waffle

INVOICE

21940

DATE

4/10/23

PRESENTING CLINICAL SIGNS

History: Presented for recheck ultrasound (initial one performed elsewhere) and as per owner, the gallbladder was "dark and hazy." She was started on ursodiol 250 mg PO SID. She is also on proin.

Abnormal PE/Chem/CBC/UA Results: Blood work performed at RDVM CBC - unremarkable T bili - 1.5 - patient is not icteric and no elevation of liver values USG - 1.016

ULTRASONOGRAPHIC EXAMINATION OF THE ABDOMEN

Urinary System

Urinary bladder is adequately distended with anechoic contents. No masses, inflammatory changes, echogenic sediment or cystoliths are observed. The urinary bladder, trigone and visible pelvic urethra are normal in thickness with a smooth mucosal surface.

Left kidney is normal in size (4.84 cm), shape and echogenicity. It has smooth peripheral margination. There is a normal 1:3 cortex to medulla ratio with appropriate corticomedullary distinction. There is no evidence of pyelectasia, mineral or infarcts observed.

Right kidney is normal in size (4.6 cm), shape and echogenicity. It has smooth peripheral margination. There is a normal 1:3 cortex to medulla ratio with appropriate corticomedullary distinction. There is no evidence of pyelectasia, mineral or infarcts observed.

Adrenal Glands

Left adrenal gland is normal in size (0.57 cm at cranial pole and 0.69 cm at caudal pole), shape and overall architecture, echogenicity and echotexture. Visible surrounding vasculature appears normal.

Right adrenal gland is normal in size (2.46 cm long x 0.52 cm at cranial pole and 0.32 cm at caudal pole), shape and overall architecture, echogenicity and echotexture. Visible surrounding vasculature appears normal.

Spleen

Spleen is generally normal in size and shape with a smooth capsular contour. Parenchyma is diffusely nodular in appearance characterized by small discrete hypoechoic nodules. Splenic vasculature appears normal.

Liver

Liver is subjectively normal in size with normal smooth curvilinear peripheral contour. Parenchyma is appropriately hypoechoic to the spleen in echogenicity and appropriately mildly coarse and homogenous in echotexture. No focal lesions are observed. Visible vasculature and biliary tree appear normal without distension or congestion.

Gallbladder is non-distended in size. The wall is smooth without visible thickening. Luminal contents are primarily anechoic. There is a small focal echogenic density consistent with a small amount of mucus or debris adhered to the wall vs potentially, a small benign polyp. There is no evidence of obstruction. There is no evidence of cystic or common bile duct dilation.

Gastrointestinal

The visible stomach wall is normal in thickness and layering. The lumen of the stomach is empty with no evidence of obstruction, foreign material or infiltrative disease. Pyloric outflow tract appears patent.

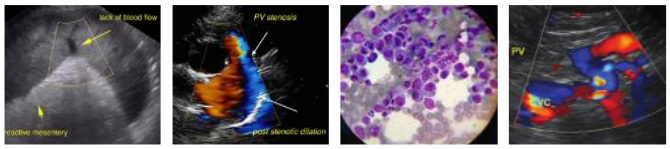

SonoPath.com
1-800-838-4268 info@sonopath.com

PATIENT

August Blatteneerger

SPECIES

Canine

BREED

Jack Russel Terrier

SEX

Spayed Female

AGE

10

WEIGHT

32.8

INTERPRETED BY

Beth Johnson, DVM DACVIM

IMAGING PERFORMED BY

Adrianne Waffle

HOSPITAL NAME

Torch Lake VC

REFERRING VET

Adrianne Waffle

INVOICE

21940

DATE

4/10/23

The visible small intestines are normal in wall thickness and layering. Small intestinal motility appears adequate (1-3 contractions per min). The lumen of the small intestine is empty with no evidence of obstruction, foreign material or infiltrative disease.

The visible colon is normal in wall thickness and layering. Contents are consistent with normal formed feces and gas.

Pancreas

The observed pancreas appears appropriately isoechoic to surrounding omental fat. Visible capsule is smooth and normal in contour. Visible pancreatic parenchyma is homogenous and unremarkable. There is no visible pancreatic duct dilation. There is no evidence of active peripancreatic inflammation.

Free Abdomen

There is no evidence of peritoneal effusion. There is no apparent lymphadenopathy.

ULTRASONOGRAPHIC FINDINGS

- The gallbladder contains a very small amount of adhered mucus, or potentially, a small benign polyp, but is otherwise unremarkable in appearance.
- Splenic micronodular hyperplasia – This nodular change is often associated with benign aging nodular hyperplasia. Infiltrative neoplasia, however, including both early hemangiosarcoma as well as round cell neoplasia cannot be ruled out.

INTERPRETATION OF THE FINDINGS & FURTHER RECOMMENDATIONS

Further recommendations for this patient are largely dependent on history and clinical signs. There is not an ultrasonographically obvious explanation for the patients mildly increased total bilirubin, and first recommendations are to rule out/sample hemolysis and confirm that total bilirubin actually is persistently increased. If it is, further testing could include testing for leptospirosis, and potentially, a fine needle aspirate of the spleen +/- liver, if patients coagulation status is appropriate.

If this patient is clinically well, however, and bilirubin is not increased, then based on this ultrasound, no immediate further recommendations are indicated.

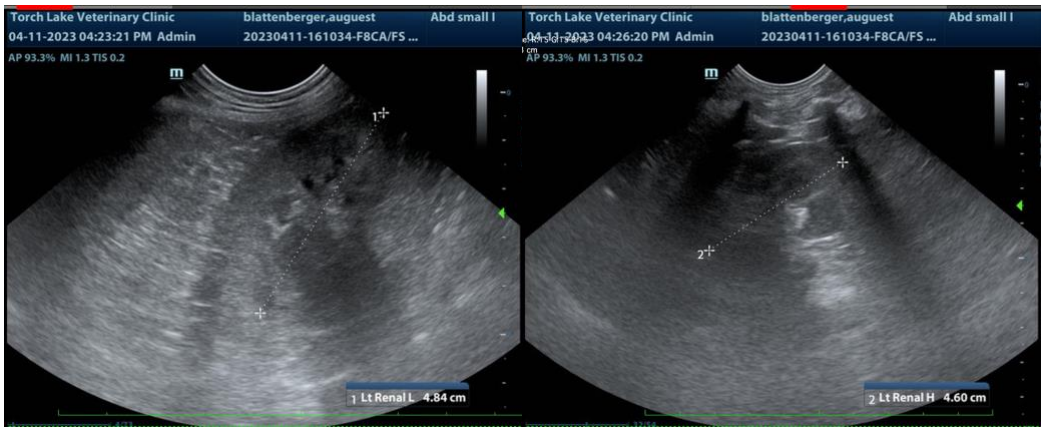

SonoPath
Clinical Sonography & Telecytology

EDUCATIONAL TELECONSULTATION SERVICES™

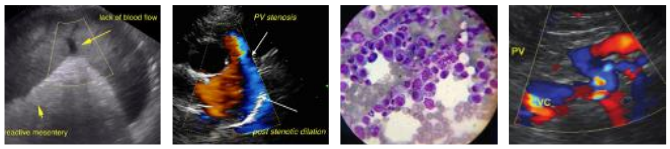

SonoPath.com
1-800-838-4268 info@sonopath.com

PATIENT

August Blatteneerger

SPECIES

Canine

BREED

Jack Russel Terrier

SEX

Spayed Female

AGE

10

WEIGHT

32.8

INTERPRETED BY

Beth Johnson, DVM DACVIM

IMAGING PERFORMED BY

Adrianne Waffle

HOSPITAL NAME

Torch Lake VC

REFERRING VET

Adrianne Waffle

INVOICE

21940

DATE

4/10/23

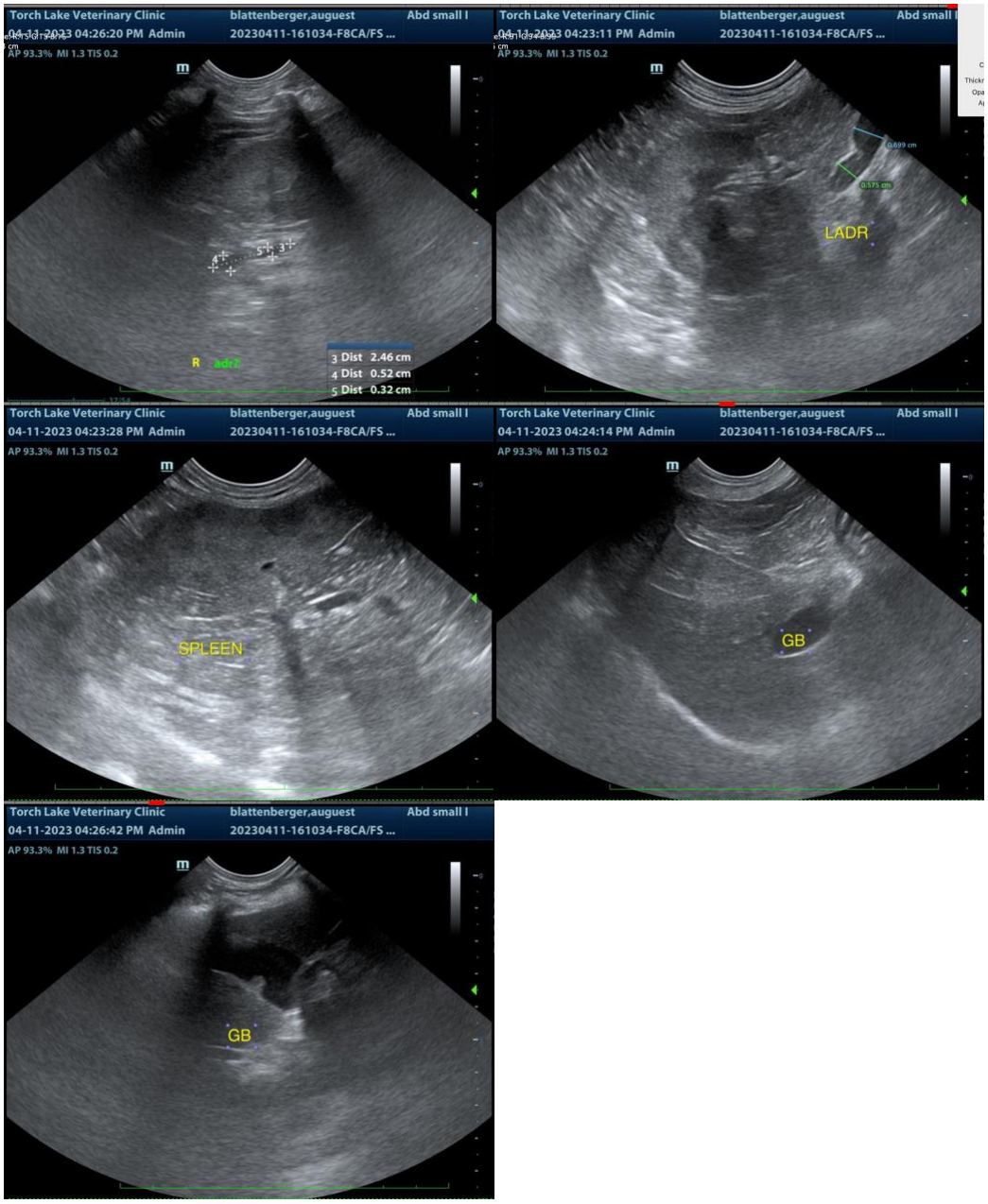

The information and recommendations provided are based on the images presented by the referring veterinarian. No evaluation can be communicated regarding pathology that was not visible in the image/video clips provided.

Thank you for this referral. If the clinical or image interpretation does not parallel your findings or if I can be of any further assistance please contact me.

Beth Johnson, DVM DACVIM

Beth.Johnson@SonoPath.com