



## PATIENT

Nevada Lashmar

## SPECIES

Canine

## BREED

Labrador Retriever

## SEX

Female

## AGE

9 years

## WEIGHT

32 kg

## INTERPRETED BY

Beth Johnson, DVM  
DACVIM

## IMAGING PERFORMED BY

Dr. Gira

## HOSPITAL NAME

Fish Creek 24  
Emergency

## REFERRING VET

Dr. Lindsay Ackert

## INVOICE

11593

## DATE

4/1/2026

## PRESENTING CLINICAL SIGNS

Nevada is a 9-year-old female intact Labrador Retriever presenting as a transfer from Elizabeth Street veterinary clinic. She was initially seen there on Friday, March 27th, for lethargy and poor appetite for a few days. The owner noted a yellow tinge to her skin and that she was not drinking. At that time, no vomiting or diarrhea was reported, but her abdomen appeared distended.

Abnormal PE/Chem/CBC/UA Results: In house diagnostics: - WBC: 24.56 x10<sup>9</sup>/L (H) - Neutrophils: 20.75 x10<sup>9</sup>/L (H) - Monocytes: 2.26 x10<sup>9</sup>/L (H) - Eosinophils: 0.03 x10<sup>9</sup>/L (L) - Platelets: 121 K/ $\mu$ L (L) - BUN: 1.9 mmol/L (L) - Calcium: 1.88 mmol/L (L) - Chloride: 108 mmol/L (L) - ALT: 2999 U/L (H) - ALP: 1797 U/L (H) - GGT: 12 U/L (H) - Bilirubin: 81  $\mu$ mol/L (H) - Cholesterol: 11.88 mmol/L (H)

## ULTRASONOGRAPHIC EXAMINATION OF THE ABDOMEN

### Urinary System

Urinary bladder is only mildly distended. Visible contents are anechoic. Urinary bladder wall is unable to be fully assessed for pathology without further distension. No visible masses or definitive cystoliths are observed. The trigone and visible pelvic urethra are normal thickness with a smooth mucosal surface. In the face of urinary signs and/or suspected urinary bladder pathology, reassessment after complete filling is recommended.

The right kidney is normal is size (7.97 cm), shape and echogenicity. It has smooth peripheral margination. There is a normal 1:3 cortex to medulla ratio with appropriate corticomedullary distinction. There is no evidence of pyelectasia, mineral or infarcts observed.

The left kidney is normal is size (7.86 cm), shape and echogenicity. It has smooth peripheral margination. There is a normal 1:3 cortex to medulla ratio with appropriate corticomedullary distinction. There is no evidence of pyelectasia, mineral or infarcts observed.

### Adrenal Glands

The right adrenal gland is plump/swollen in size measuring 0.83 cm at the cranial pole and 0.84 cm at the caudal pole. Normal shape and contour are maintained without evidence of capsular invasion. Corticomedullary structure is unremarkable. Visible surrounding vasculature appears normal.

The left adrenal gland is mildly plump/swollen, primarily at the caudal pole which measures 1.5 cm in size and the cranial pole is normal in size measuring 0.59 cm in size. Normal shape and contour are maintained without evidence of capsular invasion. Corticomedullary structure is unremarkable. Visible surrounding vasculature appears normal.

### Spleen

The spleen is subjectively normal in size with a normal smooth capsular contour. Parenchyma is appropriately finely textured and homogenous with normal echogenicity relative to surrounding tissue (hyperechoic to liver). No focal nodules or masses are observed. Splenic vasculature appears normal.

### Liver

Liver is normal to subjectively small in size with markedly undulating or scalloped capsular contour or margins. Patchy ill-defined areas of increased echogenicity are present with reduced visualization of vessels. The parenchyma is so diffusely scalloped and coarse, that in some areas it has an almost



## PATIENT

Nevada Lashmar

## SPECIES

Canine

## BREED

Labrador Retriever

## SEX

Female

## AGE

9 years

## WEIGHT

32 kg

## INTERPRETED BY

Beth Johnson, DVM  
DACVIM

## IMAGING PERFORMED BY

Dr. Gira

## HOSPITAL NAME

Fish Creek 24  
Emergency

## REFERRING VET

Dr. Lindsay Ackert

## INVOICE

11593

## DATE

4/1/2026

nodular or “moth eaten” appearance. Visible vasculature and biliary tree appear normal without distension or congestion.

The gallbladder is non-distended in size. The gallbladder wall is thick and edematous characterized by an intramural hypo to anechoic rim or “double rim effect or halo sign”. Luminal contents are primarily anechoic. There is no evidence of cystic or common bile duct dilation.

### Gastrointestinal

The visible stomach wall is normal in thickness and layering. The lumen of the stomach is mildly distended with echogenic non-shadowing luminal contents and gas consistent with normal ingesta. There is no evidence of obstruction or foreign material noted. Pyloric outflow tract appears patent.

The visible small intestines are normal in wall thickness and layering. Small intestinal motility appears adequate (1-3 contractions per min). The lumen of the small intestine is mildly distended with echogenic non-shadowing luminal contents and gas consistent with normal ingesta. There is no evidence of obstruction or foreign material noted.

The visible colon is normal in wall thickness (< 0.2 cm) and layering. Contents are consistent with normal formed feces and gas.

### Pancreas

The area of the pancreas contains irregular hyperechoic pancreatic remodeling.

### Free Abdomen

There is a mild amount of anechoic free fluid and diffusely enhanced hyperechoic mesentery, and fat is noted throughout these images.

Mesenteric and medial iliac lymph nodes are prominent in size with swollen capsular contour. Normal elongated shape (length to width ratio) is maintained. There is no loss of parenchymal detail.

## ULTRASONOGRAPHIC FINDINGS

- The liver changes/pattern is most concerning for chronic end stage hepatitis with fibrosis and/or early cirrhosis. These changes can occasionally be seen with resolved past inflammatory episodes and should therefore be interpreted in combination with clinical signs and/or associated lab changes including bile acids in patient's where total bilirubin is not increased. Given the almost nodular appearance in some views, infiltrative neoplasia can't be definitively ruled out but is considered less likely.
- Gallbladder “halo sign” – GB wall edema is a non-specific change and can be seen with any underlying etiology (ie vasculitis, hypoalbuminemia, CHF, other) that results in edema, as well as immune-mediated disease, anaphylactic shock, other. Cholecystitis cannot be ruled out.
- Hyperechoic pancreas – This finding is suggestive of pancreatic fibrosis, possibly secondary to chronic pancreatitis. A TLI is recommended to rule out exocrine pancreatic insufficiency (EPI), especially if clinical signs (weight loss, diarrhea, etc.) are present.
- Mild free fluid is of unknown origin. Differentials (unless already ruled out) could include increased hydrostatic pressure (cardiac disease and/or vascular or lymph blockage), decreased



**PATIENT**

Nevada Lashmar

**SPECIES**

Canine

**BREED**

Labrador Retriever

**SEX**

Female

**AGE**

9 years

**WEIGHT**

32 kg

**INTERPRETED BY**

Beth Johnson, DVM  
DACVIM

**IMAGING PERFORMED BY**

Dr. Gira

**HOSPITAL NAME**

Fish Creek 24  
Emergency

**REFERRING VET**

Dr. Lindsay Ackert

**INVOICE**

11593

**DATE**

4/1/2026

oncotic pressure (low albumin), vasculitis, paraneoplastic fluid, rupture/leakage of/from an organ (GI, GB, UB, other), blood (hemoabdomen), other.

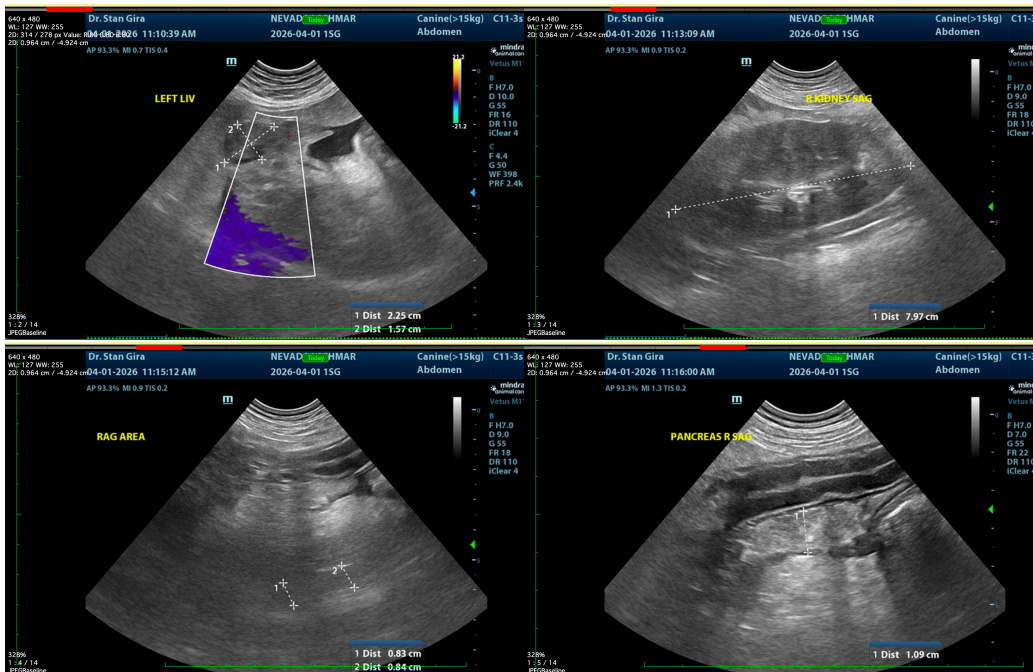
- Very mildly reactive mesenteric and medial iliac lymph nodes – infiltrative neoplastic disease cannot be ruled out but is considered less likely.
- Mild bilateral adrenomegaly – In a patient diagnosed with hyperadrenocorticism, this finding is most consistent with adrenal hyperplasia secondary to pituitary dependent hyperadrenocorticism. This finding can also be seen with stress and/or normal patient variant. Interpret in combination with clinical signs of hyperadrenocorticism and/or other adrenal disease.

**INTERPRETATION OF THE FINDINGS & FURTHER RECOMMENDATIONS**

Comprehensive infectious disease evaluation including testing for leptospirosis could be considered.

Ultimately, however, liver sampling is recommended for a definitive diagnosis and therefore to further guide medical management. If or when coagulation status can be altered and is appropriate, fine needle aspirates could be considered to further rule out infiltrative neoplasia, access inflammatory cell type, etc. but ultimately, especially given patient's signalment, a liver biopsy being sure to include copper level assessment, is likely indicated.

Other than supportive/symptomatic medical management of clinical signs, further treatment recommendations are largely dependent on results of the above.





**PATIENT**

Nevada Lashmar

**SPECIES**

Canine

**BREED**

Labrador Retriever

**SEX**

Female

**AGE**

9 years

**WEIGHT**

32 kg

**INTERPRETED BY**

Beth Johnson, DVM  
DACVIM

**IMAGING PERFORMED BY**

Dr. Gira

**HOSPITAL NAME**

Fish Creek 24  
Emergency

**REFERRING VET**

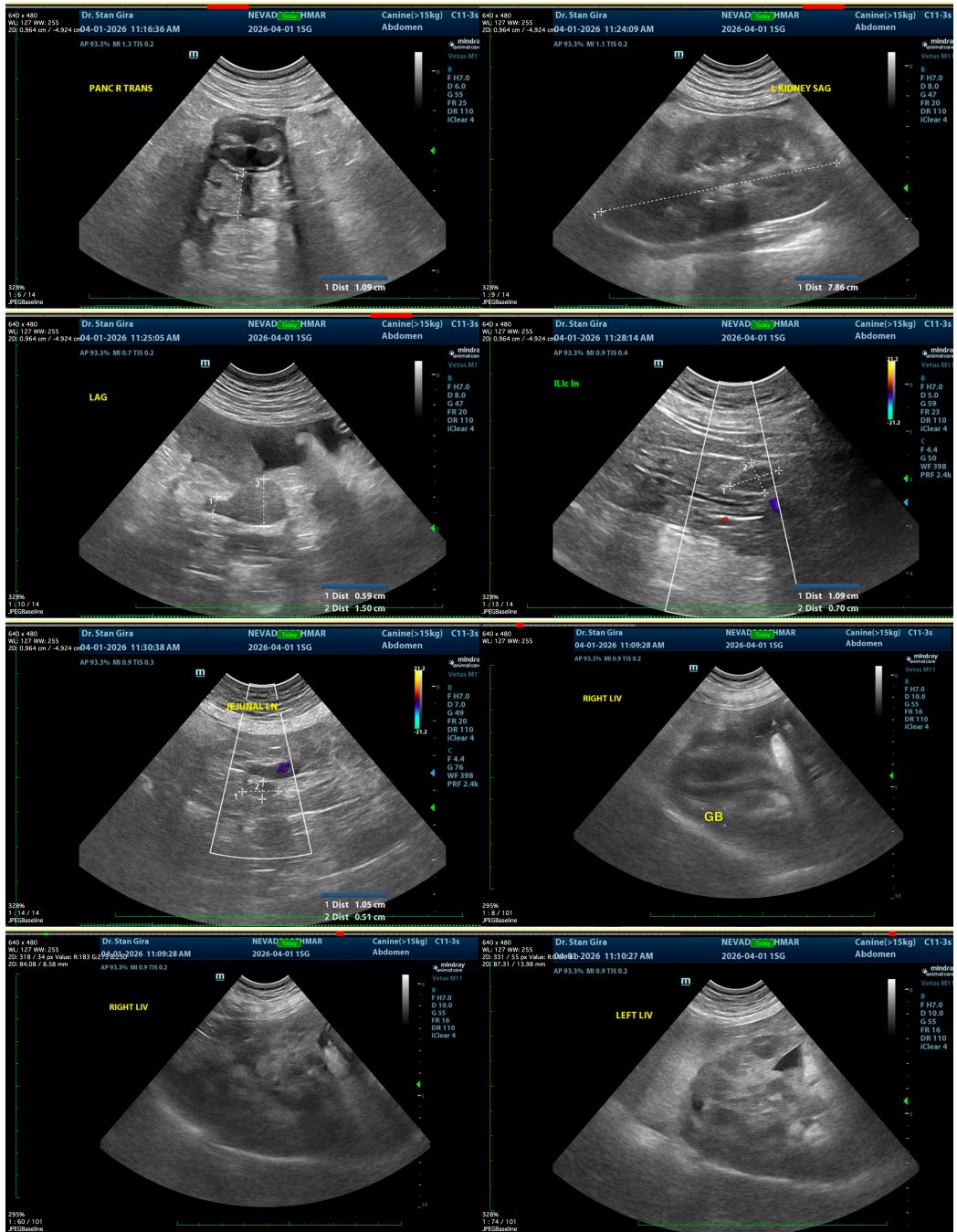
Dr. Lindsay Ackert

**INVOICE**

11593

**DATE**

4/1/2026





## PATIENT

Nevada Lashmar

## SPECIES

Canine

## BREED

Labrador Retriever

## SEX

Female

## AGE

9 years

## WEIGHT

32 kg

## INTERPRETED BY

Beth Johnson, DVM  
DACVIM

## IMAGING PERFORMED BY

Dr. Gira

## HOSPITAL NAME

Fish Creek 24  
Emergency

## REFERRING VET

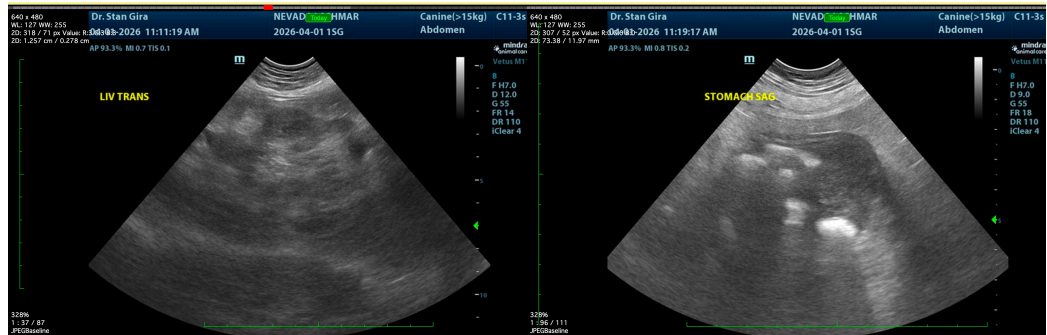
Dr. Lindsay Ackert

## INVOICE

11593

## DATE

4/1/2026



The information and recommendations provided are based on the images presented by the referring veterinarian/sonographer. No evaluation can be communicated regarding pathology that was not visible in the image/video clips provided.

Thank you for this referral. If the clinical or image interpretation does not parallel your findings or if I can be of any further assistance please contact me.

Beth Johnson, DVM, DACVIM  
info@sonopath.com