



## PATIENT

Linkin Barlow

## SPECIES

Canine

## BREED

Shih Tzu

## SEX

Neutered Male

## AGE

8.5 Years

## WEIGHT

18.2 lbs

## INTERPRETED BY

Beth Johnson, DVM  
DACVIM

## IMAGING PERFORMED BY

Jack Reese

## HOSPITAL NAME

Willow Run Veterinary  
Clinic

## REFERRING VET

Molly Arnold, DVM

## INVOICE

74150

## DATE

4/1/26

## PRESENTING CLINICAL SIGNS

Patient presented for decreased appetite and weight loss at time of annual exam. Patient previously very food motivated, but now intermittently skipping meals; down 3 lbs from last year. No vomiting or diarrhea. Previously diagnosed heart murmur – asymptomatic.

Abnormal PE/Chem/CBC/UA Results: ALP 330 (5-160) No other abnormalities on complete CBC/Chemistry

## ULTRASONOGRAPHIC EXAMINATION OF THE ABDOMEN

### *Urinary System*

The urinary bladder is adequately distended with anechoic contents. No masses, inflammatory changes, echogenic sediment or cystoliths are observed. The urinary bladder, trigone and visible pelvic urethra are normal in thickness with a smooth mucosal surface.

Prostate is normal in size, echotexture and echogenicity for a neutered male.

Kidneys are overall normal in size and shape with smooth peripheral margination. A normal 1:3 cortex to medulla ratio is maintained. The medulla and cortices are uniform in texture with some mild increased cortical echogenicity and mild loss of corticomedullary distinction, expected in this age patient. There is no evidence of pyelectasia, mineral or infarcts observed. Left kidney measures 4.2 cm. Right kidney measures 4.2 cm.

### *Adrenal Glands*

The right adrenal gland is normal in size (0.90 cm at cranial pole and 0.55 cm at caudal pole), shape and overall architecture, echogenicity and echotexture. Visible surrounding vasculature appears normal.

The left adrenal gland is normal in size (0.36 cm at cranial pole and 0.55 cm at caudal pole), shape and overall architecture, echogenicity and echotexture. Visible surrounding vasculature appears normal.

### *Spleen*

The spleen is subjectively normal in size with a normal smooth capsular contour. Parenchyma is appropriately finely textured and homogenous with normal echogenicity relative to surrounding tissue (hyperechoic to liver). No focal nodules or masses are observed. Splenic vasculature appears normal.

### *Liver*

Liver is subjectively enlarged with mildly irregular margins. Parenchyma is mildly heterogenous characterized by multiple poorly defined hypoechoic nodules within otherwise hyperechoic liver parenchyma. Visible vasculature and biliary tree appear normal without distension or congestion.

Gallbladder is moderately distended with anechoic bile as well as suspended and gravity dependent echogenic debris. The wall is smooth without visible thickening. There is no evidence of cystic or CBD dilation. There is no evidence of effusion or inflammation.

### *Gastrointestinal*

The visible stomach wall is normal in thickness and layering. The lumen of the stomach is empty with no evidence of obstruction, foreign material or infiltrative disease. Pyloric outflow tract appears patent.



**PATIENT**

Linkin Barlow

**SPECIES**

Canine

**BREED**

Shih Tzu

**SEX**

Neutered Male

**AGE**

8.5 Years

**WEIGHT**

18.2 lbs

**INTERPRETED BY**

Beth Johnson, DVM  
DACVIM

**IMAGING PERFORMED BY**

Jack Reese

**HOSPITAL NAME**

Willow Run Veterinary  
Clinic

**REFERRING VET**

Molly Arnold, DVM

**INVOICE**

74150

**DATE**

4/1/26

The visible small intestines are normal in wall thickness and layering. Small intestinal motility appears adequate (1-3 contractions per min). The lumen is mildly distended with echogenic non-shadowing luminal contents and gas consistent with normal ingesta/chyme. There is no evidence of obstruction, foreign material or infiltrative disease.

The visible colon is normal in wall thickness (< 0.2 cm) and layering. Contents are consistent with normal formed feces and gas.

***Pancreas***

Pancreas is prominent (enlarged) in size and mildly irregular in shape with a slightly undulating contour. Parenchyma is coarse in echotexture and heterogenous to hypoechoic in echogenicity.

***Free Abdomen***

There is no visible free peritoneal effusion noted in these images.

There is no apparent pathologic lymphadenopathy noted in these images.

**PRIMARY FINDINGS**

- Mildly heterogenous liver – These changes are most consistent with benign processes such as nodular hyperplasia, steroid (vacuolar) hepatopathy, extramedullary hematopoiesis or possibly chronic inflammatory disease and less commonly infiltrative round cell or metastatic neoplasia.
- Moderate gallbladder debris - Cholecystic debris is of unknown clinical significance. It can be seen with biliary stasis from fasting or illness. Cholecystic debris is not necessarily related to hepatobiliary disease. Echogenic bile is most commonly an incidental finding in dogs and should be interpreted in combination with clinical signs such as nausea, inappetence, cranial abdominal discomfort and/or laboratory changes such as increased ALP and/or increased Tbili.
- Chronic low-grade smoldering pancreatitis as a possible contributing cause to decreased appetite can't be ruled out.

**SECONDARY FINDINGS**

- Mild to moderate age related kidney changes.

**INTERPRETATION OF THE FINDINGS & FURTHER RECOMMENDATIONS**

A gastrointestinal malabsorption panel (including cobalamin, folate, TLI and PLI) to Texas A&M GI Laboratory is recommended for further evaluation of GI and pancreatic function.

A baseline cortisol is recommended. If baseline cortisol is less than 2, a full ACTH stimulation test is recommended to rule out hypoadrenocorticism.

Also, further evaluation for possible pain (dental, orthopedic, other), upper respiratory disease or oropharyngeal disease, cardiac disease and/or neurologic disease vs other as possible causes for decreased appetite and/or unintentional weight loss is also recommended.

In the meantime, supportive/symptomatic medical management of possible subclinical or low grade nausea could be considered in the form of antiemetics, gastroprotectants, as well as an appetite stimulant while monitoring for improvement.



**PATIENT**

Linkin Barlow

**SPECIES**

Canine

**BREED**

Shih Tzu

**SEX**

Neutered Male

**AGE**

8.5 Years

**WEIGHT**

18.2 lbs

**INTERPRETED BY**

Beth Johnson, DVM  
DACVIM

**IMAGING PERFORMED BY**

Jack Reese

**HOSPITAL NAME**

Willow Run Veterinary  
Clinic

**REFERRING VET**

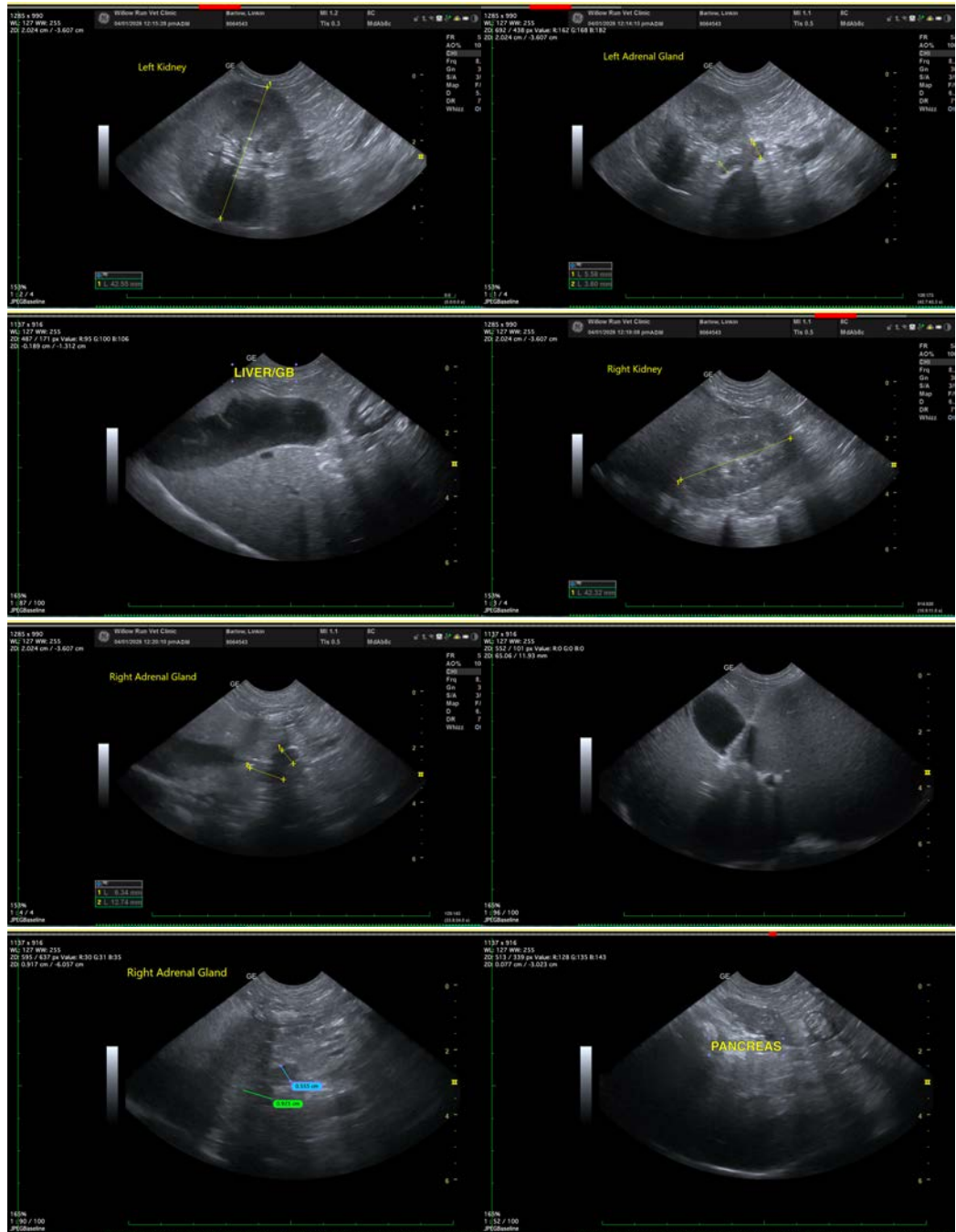
Molly Arnold, DVM

**INVOICE**

74150

**DATE**

4/1/26





## PATIENT

Linkin Barlow

## SPECIES

Canine

## BREED

Shih Tzu

## SEX

Neutered Male

## AGE

8.5 Years

## WEIGHT

18.2 lbs

## INTERPRETED BY

Beth Johnson, DVM  
DACVIM

## IMAGING PERFORMED BY

Jack Reese

## HOSPITAL NAME

Willow Run Veterinary  
Clinic

## REFERRING VET

Molly Arnold, DVM

## INVOICE

74150

## DATE

4/1/26

The information and recommendations provided are based on the images presented by the referring veterinarian/sonographer. No evaluation can be communicated regarding pathology that was not visible in the image/video clips provided.

Thank you for this referral. If the clinical or image interpretation does not parallel your findings or if I can be of any further assistance please contact me.

**Beth Johnson, DVM, DACVIM**  
info@sonopath.com