


**IMAGING PERFORMED BY**

SVS Mobile Imaging MI 734-637-7711  
svsimagingmi@gmail.com

**PATIENT**

Sweetie Belle Stewart

**SPECIES**

Canine

**BREED**

Shih Tzu

**SEX**

Spayed Female

**AGE**

8 Years

**WEIGHT**

7.4 Pounds

**INTERPRETED BY**

Beth Johnson, DVM  
DACVIM

**IMAGING PERFORMED BY**

Amy Mayhew, LVT

**HOSPITAL NAME**

SVS Imaging Michigan

**REFERRING VET**

Mittens Animal  
Hospital

**INVOICE**

36671

**DATE**

4/1/22

**PRESENTING CLINICAL SIGNS**

Recurrent hematuria since January 2022. Initially patient was treated for suspect bladder infection on 01/25/2022 with clavamox for 14 day duration.

Abnormal PE/Chem/CBC/UA Results: Recheck in-house UA on 02/12/2022 showed improvement but still mildly increased RBC and WBC in sediment. Urine culture performed on that sample isolated low level growth of Staph pseudointermedius susceptible to clavamox. A repeat 10 day course of clavamox was prescribed. Follow-up UA on 03/22/2022 revealed markedly increased RBC and WBC in sediment in greater numbers than initial sample. Abdominal radiographs were taken and revealed a minimally distended urinary bladder with a small amount of amorphous mineral opacity within the caudal aspect of the urinary bladder, in the region of the bladder neck.

**ULTRASONOGRAPHIC EXAMINATION OF THE ABDOMEN****Urinary System**

The urinary bladder is moderately distended with anechoic contents. There is a 0.5 cm broad-based, hyperechoic, amorphous density that extends 1.0 cm into the lumen of the bladder from the trigone. The density is heterogenous in both echotexture and echogenicity. Beyond the density in the proximal urethra, is mineral debris.

The right kidney is normal in size (3.28 cm), shape and echogenicity. It has smooth peripheral margination. There is a normal 1:3 cortex to medulla ratio with appropriate corticomedullary distinction. There is no evidence of pyelectasia or infarcts observed. Non-obstructive areas of mineralization/nephroliths are noted, primarily in the diverticular of the kidney.

The left kidney is normal in size (2.98 cm), shape and echogenicity. It has smooth peripheral margination. There is a normal 1:3 cortex to medulla ratio with appropriate corticomedullary distinction. There is no evidence of pyelectasia or infarcts observed. Non-obstructive areas of mineralization/nephroliths are noted, primarily in the diverticular of the kidney.

**Adrenal Glands**

The right adrenal gland is normal in size (0.41 cm at the cranial pole and 0.38 cm at the caudal pole), shape and contour. Corticomedullary structure is unremarkable. Visible surrounding vasculature appears normal.

The left adrenal gland is normal in size (0.33 cm at the cranial pole and 0.39 cm at the caudal pole), shape and contour. Corticomedullary structure is unremarkable. Visible surrounding vasculature appears normal.

**Spleen**

The spleen is subjectively normal in size with a normal smooth capsular contour. Parenchyma is appropriately finely textured and homogenous with normal echogenicity relative to surrounding tissue (hyperechoic to liver). No focal nodules or masses are observed. Splenic vasculature appears normal.


**Liver**

The liver is subjectively normal in size with normal smooth curvilinear peripheral contour. Parenchyma is appropriately hypoechoic to the spleen in echogenicity and appropriately mildly coarse and homogenous in echotexture. No focal lesions are observed. Visible vasculature and biliary tree appear normal without distension or congestion.

GB is moderately distended with anechoic bile and gravity dependent echogenic sediment. The wall is smooth without visible thickening. There is no evidence of cystic or CBD dilation. There is no evidence of effusion or inflammation.

## IMAGING PERFORMED BY

SVS Mobile Imaging MI 734-637-7711  
svsimagingmi@gmail.com



### PATIENT

Sweetie Belle Stewart

### SPECIES

Canine

### BREED

Shih Tzu

### SEX

Spayed Female

### AGE

8 Years

### WEIGHT

7.4 Pounds

### INTERPRETED BY

Beth Johnson, DVM  
DACVIM

### IMAGING PERFORMED BY

Amy Mayhew, LVT

### HOSPITAL NAME

SVS Imaging Michigan

### REFERRING VET

Mittens Animal  
Hospital

### INVOICE

36671

### DATE

4/1/22

### *Gastrointestinal*

The stomach wall is normal in thickness (canine < 0.5 cm and feline < 0.4 cm) and layering. The lumen of the stomach is mildly distended with echogenic non-shadowing luminal contents and gas consistent with normal ingesta. There is no evidence of obstruction, foreign material or infiltrative disease. Pyloric outflow tract appears patent.

The visible small intestines are normal in wall thickness and layering (canine duodenum < 0.5 cm and feline duodenum < 0.4 cm; other < 0.3 cm). Small intestinal motility appears adequate (1-3 contractions per min). The lumen of the small intestine is empty with no evidence of obstruction, foreign material or infiltrative disease.

The visible colon is normal in wall thickness (< 0.2 cm) and layering. Contents are consistent with normal formed feces and gas.

### *Pancreas*

The pancreatic parenchyma is appropriately isoechoic to surrounding tissue. Visible capsule is smooth and normal in contour. There is no visible pancreatic duct dilation. There is no evidence of active peripancreatic inflammation.

### *Free Abdomen*

There is no evidence of peritoneal effusion. There is no apparent lymphadenopathy.

### PRIMARY FINDINGS

- Amorphous, echogenic density in the trigone of the bladder – concerning for tissue with both inflammatory tissue/accumulated debris as well as infiltrative neoplasia being on the list of differentials. Mineral foci are around the density and distal to the density in the proximal urethra.

### SECONDARY FINDINGS

- Non-obstructive nephrolithiasis
- Gallbladder debris - Cholecystic debris is of unknown clinical significance. It can be seen with biliary stasis from fasting or illness. Cholecystic debris is not necessarily related to hepatobiliary disease. Echogenic bile is most commonly an incidental finding in dogs and should be interpreted in combination with clinical signs such as nausea, inappetence, cranial abdominal discomfort and/or laboratory changes such as increased ALP and/or increased Tbili.

### INTERPRETATION OF THE FINDINGS & FURTHER RECOMMENDATIONS

Recommendations include submission of urine to look for BRAF gene mutation, which is associated with urinary bladder cancer. If BRAF is negative, recommendations include continued management of infection and mineral debris, suspected to be struvite given the concurrent presence of infection.

Management recommendations include a struvite dissolution diet such as Hills S/D or Purina UR or Royal Canin Urinary SO combined with antibiotics while monitoring urinalysis for a pH <7 and imaging for evidence of resolution of the mineral debris. If management of the infection and attempted mineral dissolution is not successful based on follow up imaging, and BRAF is not suggestive of urinary bladder neoplasia, and the debris remains present, a fine needle aspirate of the area could also be considered with a small risk of tumor seeding/trailing if neoplasia is in fact present despite a negative BRAF.

IMAGING PERFORMED BY

SVS Mobile Imaging MI 734-637-7711  
svsimagingmi@gmail.com



**PATIENT**

Sweetie Belle Stewart

**SPECIES**

Canine

**BREED**

Shih Tzu

**SEX**

Spayed Female

**AGE**

8 Years

**WEIGHT**

7.4 Pounds

**INTERPRETED BY**

Beth Johnson, DVM  
DACVIM

**IMAGING PERFORMED BY**

Amy Mayhew, LVT

**HOSPITAL NAME**

SVS Imaging Michigan

**REFERRING VET**

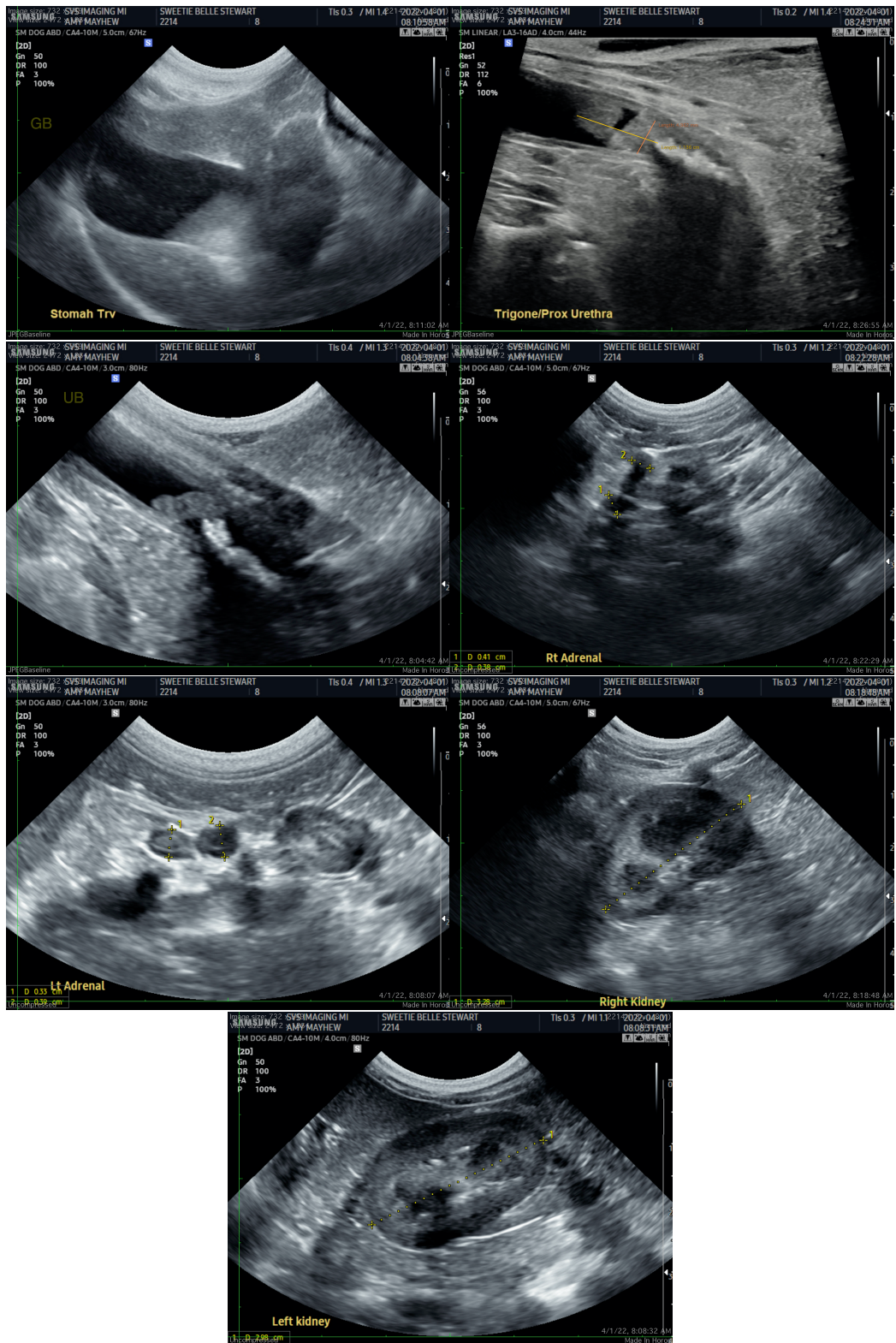
Mittens Animal  
Hospital

**INVOICE**

36671

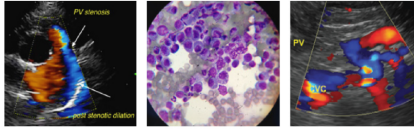
**DATE**

4/1/22



**IMAGING PERFORMED BY**

SVS Mobile Imaging MI 734 - 637 - 7711  
svsimagingmi@gmail.com



EDUCATIONAL TELECONSULTATION SERVICES™  
1-800-838-4268 info@sonopath.com SonoPath.com

**PATIENT**

Sweetie Belle Stewart

The information and recommendations provided are based on the images presented by the referring veterinarian/sonographer. No evaluation can be communicated regarding pathology that was not visible in the image/video clips provided.

**SPECIES**

Canine

Thank you for this referral. If the clinical or image interpretation does not parallel your findings or if I can be of any further assistance please contact me.

**Beth Johnson, DVM, DACVIM**  
Beth.Johnson@sonopath.com

**BREED**

Shih Tzu

**SEX**

Spayed Female

**AGE**

8 Years

**WEIGHT**

7.4 Pounds

**INTERPRETED BY**

Beth Johnson, DVM  
DACVIM

**IMAGING PERFORMED BY**

Amy Mayhew, LVT

**HOSPITAL NAME**

SVS Imaging Michigan

**REFERRING VET**

Mittens Animal  
Hospital

**INVOICE**

36671

**DATE**

4/1/22