



## PATIENT

Rusko Lancaster

## SPECIES

Canine

## BREED

Terrier Mix

## SEX

M

## AGE

13Y

## WEIGHT

22lbs

## INTERPRETED BY

Beth Johnson, DVM,  
DACVIM (SAIM)

## IMAGING PERFORMED BY

Julia Bakker, DVM

## HOSPITAL NAME

Orange Blossom  
Veterinary Imaging

## REFERRING VET

Ashley Sorice, DVM

## INVOICE

74105

## DATE

3-9-26

## PRESENTING CLINICAL SIGNS

- Abdominal radiographs show prostatomegaly, recommended AUS with FNA
- Patient can urinate but seems to strain to defecate

## ULTRASONOGRAPHIC EXAMINATION OF THE ABDOMEN

### *Urinary System*

The urinary bladder is adequately distended with anechoic contents. No masses, inflammatory changes, echogenic sediment or cystoliths are observed. The urinary bladder, trigone and visible pelvic urethra are normal in thickness with a smooth mucosal surface.

Prostate is symmetrically enlarged (3.6 cm wide sagittal view) with smooth margins that are well differentiated from surrounding tissue. Normal bilobed shape is maintained. Parenchyma is diffusely hyperechoic. Several small anechoic cysts are noted. No mineral is noted.

The right kidney is normal is size (5.04 cm), shape and echogenicity. It has smooth peripheral margination. There is a normal 1:3 cortex to medulla ratio with appropriate corticomedullary distinction. There is no evidence of pyelectasia, mineral or infarcts observed.

The left kidney is normal is size (4.93 cm), shape and echogenicity. It has smooth peripheral margination. There is a normal 1:3 cortex to medulla ratio with appropriate corticomedullary distinction. There is no evidence of pyelectasia, mineral or infarcts observed.

### *Adrenal Glands*

The left adrenal gland is normal in size (0.47 cm at cranial pole and 0.83 cm at caudal pole), shape and overall architecture, echogenicity and echotexture. Visible surrounding vasculature appears normal.

The right adrenal gland is difficult to fully visualize/isolate for measurement.

### *Spleen*

The spleen is subjectively normal in size with a normal smooth capsular contour. Parenchyma is appropriately finely textured and homogenous with normal echogenicity relative to surrounding tissue (hyperechoic to liver). No focal nodules or masses are observed. Splenic vasculature appears normal.

### *Liver*

The liver is subjectively normal in size with normal smooth curvilinear peripheral contour. Parenchyma is appropriately hypoechoic to the spleen in echogenicity and appropriately mildly coarse and homogenous in echotexture. No focal lesions are observed. Visible vasculature and biliary tree appear normal without distension or congestion.

The gallbladder is non-distended in size. The wall is smooth without visible thickening. Luminal contents are primarily anechoic. There is no evidence of cystic or common bile duct dilation.

### *Gastrointestinal*

The visible stomach wall is normal in thickness and layering. The lumen of the stomach is empty with no evidence of obstruction, foreign material or infiltrative disease. Pyloric outflow tract appears patent.



## PATIENT

Rusko Lancaster

## SPECIES

Canine

## BREED

Terrier Mix

## SEX

M

## AGE

13Y

## WEIGHT

22lbs

## INTERPRETED BY

Beth Johnson, DVM,  
DACVIM (SAIM)

## IMAGING PERFORMED BY

Julia Bakker, DVM

## HOSPITAL NAME

Orange Blossom  
Veterinary Imaging

## REFERRING VET

Ashley Sorice, DVM

## INVOICE

74105

## DATE

3-9-26

The visible small intestines are normal in wall thickness and layering. Small intestinal motility appears adequate (1-3 contractions per min). The lumen of the small intestine is empty with no evidence of obstruction, foreign material or infiltrative disease.

The visible colon is normal in wall thickness (< 0.2 cm) and layering. Contents are consistent with normal formed feces and gas.

### ***Pancreas***

The pancreas that is observed appears appropriately isoechoic to surrounding omental fat. Visible capsule is smooth and normal in contour. Visible pancreatic parenchyma is homogenous and unremarkable. There is no visible pancreatic duct dilation. There is no evidence of active peripancreatic inflammation.

### ***Free Abdomen***

There is no visible free peritoneal effusion noted in these images.

There is no apparent pathologic lymphadenopathy noted in these images.

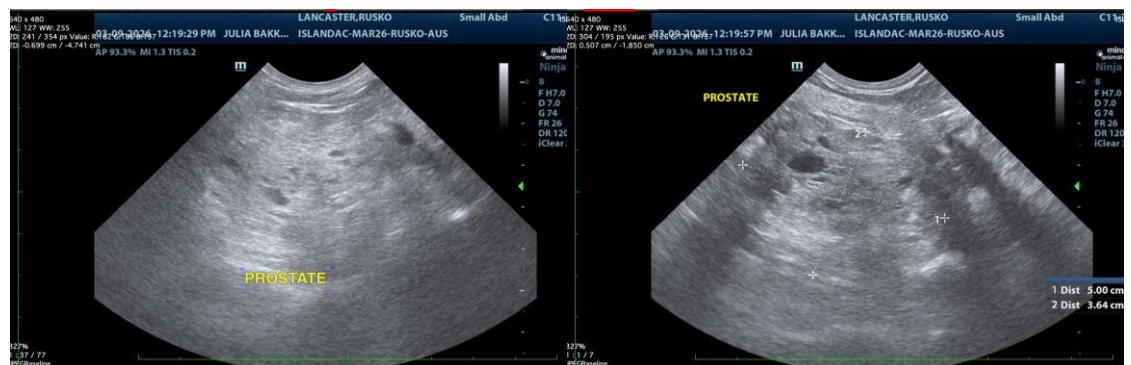
## ULTRASONOGRAPHIC FINDINGS

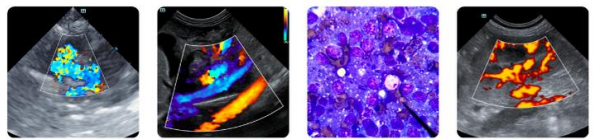
- Benign Prostatic Hyperplasia with cysts – Prostatic findings are most consistent with Benign Prostatic Hyperplasia (BPH) and concurrent benign prostatic cysts. Active prostatitis cannot be ruled out. Infiltrative neoplasia cannot be ruled out but is considered less likely.

## INTERPRETATION OF THE FINDINGS & FURTHER RECOMMENDATIONS

The appearance of the prostate trends in appearance toward benign. Having said that, if further evaluation for possible prostatic disease is warranted or elected based on clinical suspicion, urinalysis and, if indicated based on urinalysis results, urine culture is recommended. If protein is present in an otherwise quiet sediment, protein quantification with a urine protein to creatinine ration is recommended.

Submission of urine to look BRAF gene mutation could be considered or ultimately, FNA of the prostate could be considered if patient's coagulation status is appropriate. Having said that, patient's reported straining to defecate may be secondary to etiologies unrelated to the prostatomegaly, especially with normal urination and should be interpreted in combination with whether or not patient appears clinically constipated vs straining with diarrhea, etc.





## PATIENT

Rusko Lancaster

## SPECIES

Canine

## BREED

Terrier Mix

## SEX

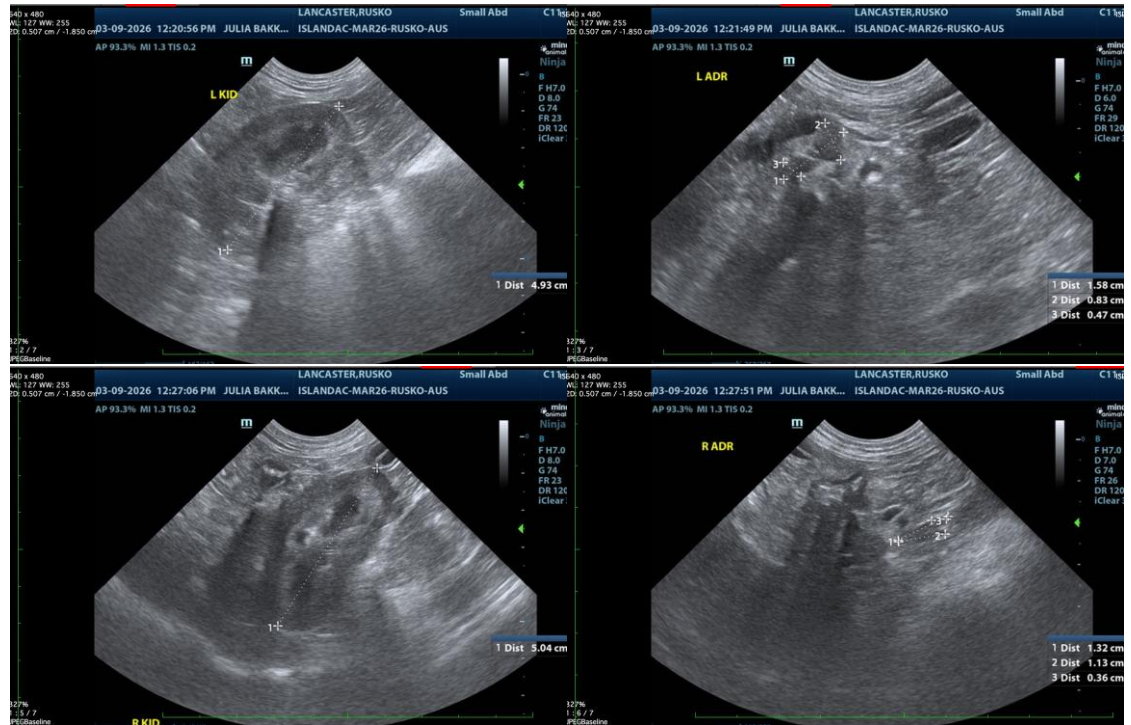
M

## AGE

13Y

## WEIGHT

22lbs



## INTERPRETED BY

Beth Johnson, DVM,  
DACVIM (SAIM)

## IMAGING PERFORMED BY

Julia Bakker, DVM

## HOSPITAL NAME

Orange Blossom  
Veterinary Imaging

## REFERRING VET

Ashley Sorice, DVM

## INVOICE

74105

## DATE

3-9-26

The information and recommendations provided are based on the images presented by the referring veterinarian/sonographer. No evaluation can be communicated regarding pathology that was not visible in the image/video clips provided.

Thank you for this referral. If the clinical or image interpretation does not parallel your findings or if I can be of any further assistance please contact me.

**Beth Johnson, DVM, DACVIM**  
info@sonopath.com