



PATIENT

Brutus Moore

SPECIES

Canine

BREED

Labrador Retriever

SEX

MN

AGE

6Y

WEIGHT

90lbs

INTERPRETED BY

Beth Johnson, DVM,
DACVIM (SAIM)

IMAGING PERFORMED BY

Julia Bakker, DVM

HOSPITAL NAME

Orange Blossom
Veterinary Imaging

REFERRING VET

Ashley Sorice, DVM

INVOICE

74103

DATE

3-9-26

PRESENTING CLINICAL SIGNS

- Owner mentioned drinking more, urinating more, panting more, more lethargic, thinks he may be gaining weight - previous BW indicated elevated liver values along with low SG - concern for stress/anxiety causing an increase in cortisol or early onset of cushings. Symptoms have been going on for about month

Abnormal PE/Chem/CBC/UA Results: USG 1.025

ULTRASONOGRAPHIC EXAMINATION OF THE ABDOMEN

Urinary System

The urinary bladder is adequately distended with anechoic contents. No masses, inflammatory changes, echogenic sediment or cystoliths are observed. The urinary bladder, trigone and visible pelvic urethra are normal in thickness with a smooth mucosal surface.

Prostate is normal in size, echotexture and echogenicity for a neutered male.

The right kidney is normal is size (6.49 cm), shape and echogenicity. It has smooth peripheral margination. There is a normal 1:3 cortex to medulla ratio with appropriate corticomedullary distinction. A hyperechoic band parallel to the corticomedullary border is present. There is no evidence of pyelectasia, mineral or infarcts observed.

The left kidney is normal is size (6.27 cm), shape and echogenicity. It has smooth peripheral margination. There is a normal 1:3 cortex to medulla ratio with appropriate corticomedullary distinction. A hyperechoic band parallel to the corticomedullary border is present. There is no evidence of pyelectasia, mineral or infarcts observed.

Adrenal Glands

The adrenal glands were unable to be visualized in the video clips, so these descriptions are based on the provided measured still images in which case the cranial pole of the left adrenal gland measured mildly plump at 1.2 cm. Otherwise, the adrenal glands are normal with the caudal pole of the left adrenal gland measuring 0.6 cm.

The right adrenal gland is normal in size (0.61 cm at cranial pole and 0.93 cm at caudal pole), shape and overall architecture, echogenicity and echotexture. Visible surrounding vasculature appears normal.

Spleen

The spleen is subjectively normal in size with a normal smooth capsular contour. Parenchyma is appropriately finely textured and homogenous with normal echogenicity relative to surrounding tissue (hyperechoic to liver). No focal nodules or masses are observed. Splenic vasculature appears normal.

Liver

The liver is subjectively normal in size with normal smooth curvilinear peripheral contour. Parenchyma is appropriately hypoechoic to the spleen in echogenicity and appropriately mildly coarse and homogenous in echotexture. No focal lesions are observed. Visible vasculature and biliary tree appear normal without distension or congestion.



PATIENT

Brutus Moore

The gallbladder is non-distended in size. The wall is smooth without visible thickening. Luminal contents are primarily anechoic. There is no evidence of cystic or common bile duct dilation.

Gastrointestinal

SPECIES

Canine

The visible stomach wall is normal in thickness and layering. The lumen of the stomach is mildly distended with very echogenic reverberation artifact from intraluminal gas. There is no evidence of obstruction, foreign material or infiltrative disease; however, complete visualization of far wall is partially inhibited by gas. Pyloric outflow tract appears patent.

BREED

Labrador Retriever

The visible small intestines are normal in wall thickness and layering. Small intestinal motility appears adequate (1-3 contractions per min). The lumen of the small intestine is empty with no evidence of obstruction, foreign material or infiltrative disease.

SEX

MN

The visible colon is normal in wall thickness (< 0.2 cm) and layering. Contents are consistent with normal formed feces and gas.

AGE

6Y

Pancreas

The pancreas that is observed appears appropriately isoechoic to surrounding omental fat. Visible capsule is smooth and normal in contour. Visible pancreatic parenchyma is homogenous and unremarkable. There is no visible pancreatic duct dilation. There is no evidence of active peripancreatic inflammation.

WEIGHT

90lbs

Free Abdomen

There is no visible free peritoneal effusion noted in these images.

There is no apparent pathologic lymphadenopathy noted in these images.

INTERPRETED BY

Beth Johnson, DVM,
DACVIM (SAIM)

ULTRASONOGRAPHIC FINDINGS

IMAGING PERFORMED BY

Julia Bakker, DVM

- Bilateral medullary rim sign - This finding is of unknown clinical significance and can be a normal variant, often idiopathic. Medullary rim sign can be present with renal disease including lymphoma, hypercalcemic nephropathy, Leptospirosis, tubular disease, other and should be interpreted in combination with other more specific indications of kidney disease such as isosthenuria, proteinuria, azotemia, etc. This is a common incidental finding in patients with diabetes mellitus.
- The adrenal glands are difficult to fully assess as described above but the left adrenal gland may be mildly plump primarily at the cranial pole.

HOSPITAL NAME

Orange Blossom
Veterinary Imaging

INTERPRETATION OF THE FINDINGS & FURTHER RECOMMENDATIONS

REFERRING VET

Ashley Sorice, DVM

Differentials for PU/PD are vast and include, but are not limited to:

INVOICE

74103

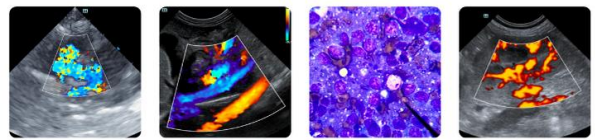
Primary polyuria caused by chronic kidney disease, pyelonephritis, liver disease, diabetes mellitus, hyperthyroidism, hypercalcemia, hyperadrenocorticism, hypoadrenocorticism, E.coli infections ie) pyometra in females, polycythemia, central diabetes insipidus or primary nephrogenic diabetes insipidus.

DATE

3-9-26

Primary polydipsia caused by psychogenic polydipsia, fever, pain, or central nervous system disease.

Most causes of PU/PD can be diagnosed with a comprehensive history and physical exam, a first AM urine specific gravity to see if urine concentration is possible (as most animals naturally consume less



PATIENT

Brutus Moore

water overnight) followed by a comprehensive CBC, serum chemistry panel, electrolytes, and urinalysis.

SPECIES

Canine

If not, next step(s) may include a urine culture, low dose dexamethasone suppression test, T4, bile acids, Leptospirosis testing and/or an empirical course of antibiotics.

BREED

Labrador Retriever

If a diagnosis is still not obtained, a more advanced work-up is indicated and consultation with an internist may be warranted.

SEX

MN

If not recently evaluated, a blood pressure is recommended.

AGE

6Y

WEIGHT

90lbs

INTERPRETED BY

Beth Johnson, DVM,
DACVIM (SAIM)

IMAGING PERFORMED BY

Julia Bakker, DVM

HOSPITAL NAME

Orange Blossom
Veterinary Imaging

REFERRING VET

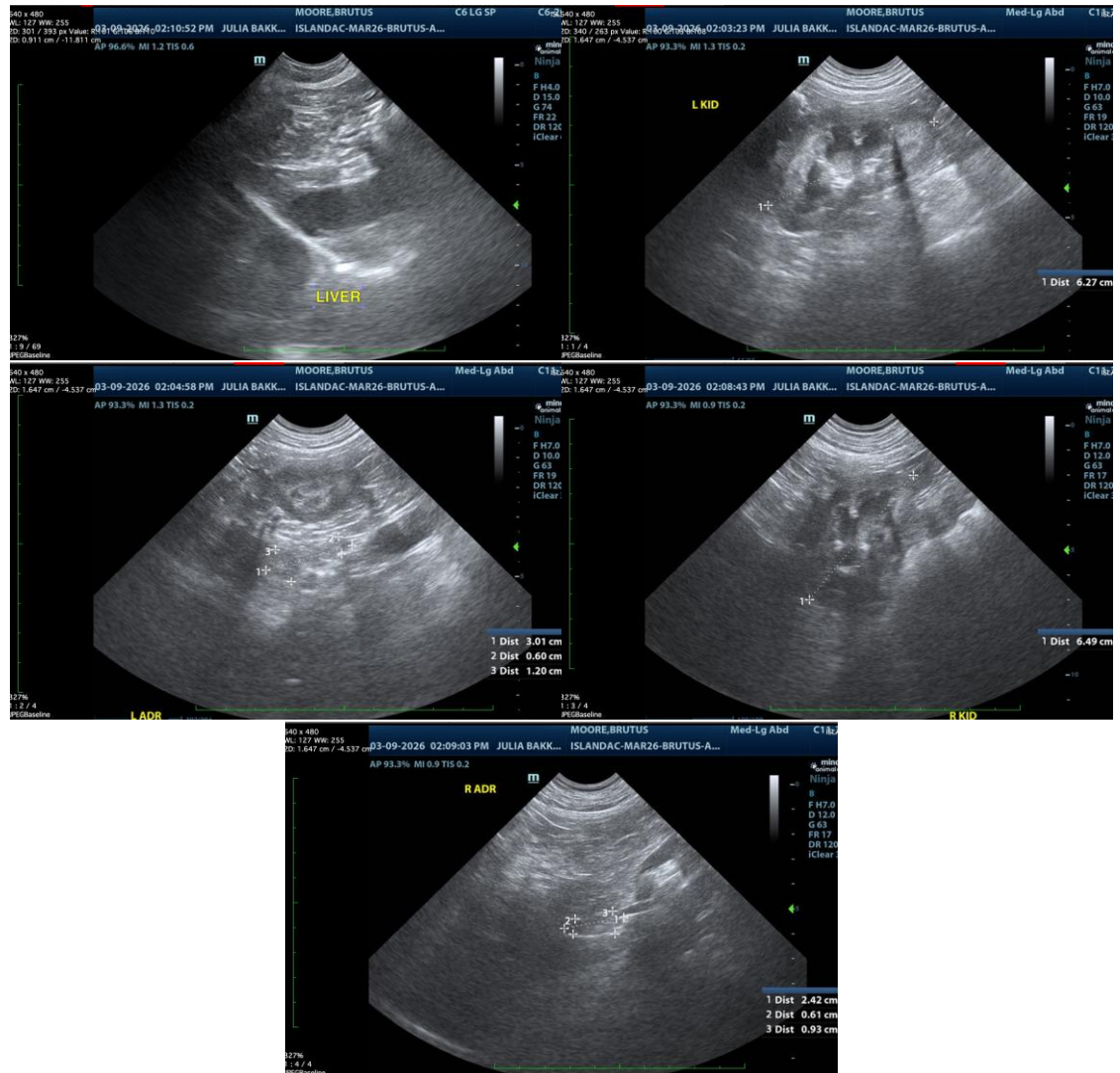
Ashley Sorice, DVM

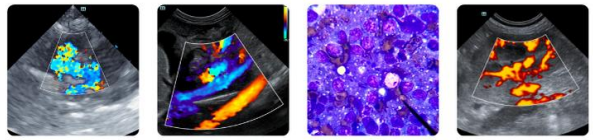
INVOICE

74103

DATE

3-9-26





PATIENT

Brutus Moore

SPECIES

Canine

BREED

Labrador Retriever

SEX

MN

AGE

6Y

WEIGHT

90lbs

INTERPRETED BY

Beth Johnson, DVM,
DACVIM (SAIM)

IMAGING PERFORMED BY

Julia Bakker, DVM

HOSPITAL NAME

Orange Blossom
Veterinary Imaging

REFERRING VET

Ashley Sorice, DVM

INVOICE

74103

DATE

3-9-26

The information and recommendations provided are based on the images presented by the referring veterinarian/sonographer. No evaluation can be communicated regarding pathology that was not visible in the image/video clips provided.

Thank you for this referral. If the clinical or image interpretation does not parallel your findings or if I can be of any further assistance please contact me.

Beth Johnson, DVM, DACVIM

info@sonopath.com