



DATE

03/09/26

PATIENT

Autumn Jackson

SPECIES

Feline

BREED

DSH

SEX

Spayed Female

AGE

04/28/2011

WEIGHT

5.27 pounds

INTERPRETED BY

Beth Johnson, DVM
DACVIM

HOSPITAL NAME

Banfield Columbia

REFERRING VET

Dr. Landon

INVOICE

14166

PRESENTING CLINICAL SIGNS

Patient History: 2/10/26: P has been not eating, having diarrhea, and vomiting since January 28 intermittently. O is unsure of when vomiting is occurring. Feces looks like clear mucous. PE BAR BCS 7/9 mm pink, moist. CRT < 2 sec. Oral & Nasal Observations: recession 108; moderate tartar and gingivitis throughout, cardiac auscultation grade 3/6 left systolic murmur, abdominal palp nsf, skin nsf. MS- mild plantigrade stance
Recommend switching to hydrolyzed diet previously prescribed, will give Will reevaluate based on response to therapy

Current Medications: Cerenia and Mirataz to help with appetite and proviable to help with diarrhea.
Labwork Results: Labwork not attached, reported as: 2/10/26: cbc/chem/lytes- nsf, thyroid- normal SDMA - normal. Radiographs: normal thorax and abdomen with signs of IVDD
Date of Previous IntraPet Ultrasound: No previous.
Sedation: Not required to complete full diagnostic ultrasound.
Stat Report: Not requested.
Imaging Performed by: Stephanie Warga RDCS, RVT.

ULTRASONOGRAPHIC EXAMINATION OF THE ABDOMEN

Urinary System

Urinary bladder is adequately distended. It has a normal uniform wall thickness. Contents include primarily anechoic fluid with occasional echogenic non-shadowing debris, most consistent with incidental suspended lipid in a cat, possibly combined with exfoliated cells, mucous and/or small blood clots. Both sterile inflammation as well as urinary tract infection can also present with echogenic debris. No masses or definitive cystoliths are observed. The trigone and visible pelvic urethra are normal in thickness with a smooth mucosal surface.

Left kidney is normal in size (3.24 cm), shape and echogenicity. It has smooth peripheral margination. There is a normal 1:3 cortex to medulla ratio with appropriate corticomedullary distinction. There is no evidence of pyelectasia, mineral or infarcts observed.

Right kidney is normal in size (3.71 cm), shape and echogenicity. It has smooth peripheral margination. There is a normal 1:3 cortex to medulla ratio with appropriate corticomedullary distinction. There is no evidence of pyelectasia, mineral or infarcts observed.

Adrenal Glands

Left adrenal gland is normal in size (0.35 cm at cranial pole and 0.46 cm at caudal pole), shape and overall architecture, echogenicity and echotexture. Visible surrounding vasculature appears normal.

Right adrenal gland is normal in size (X cm at cranial pole and X cm at caudal pole), shape and overall architecture, echogenicity and echotexture. Visible surrounding vasculature appears normal.

Spleen

Spleen is subjectively normal in size with a normal smooth capsular contour. Parenchyma is appropriately finely textured and homogenous with normal echogenicity relative to surrounding tissue (hyperechoic to

liver). Splenic vasculature appears normal. A subtle 0.40 cm x 0.60 cm nondisruptive hypo- to anechoic nodule in the mid spleen was present.

Liver

Liver is subjectively normal in size with normal smooth curvilinear peripheral contour. Parenchyma is appropriately hypoechoic to the spleen in echogenicity and appropriately mildly coarse and homogenous in echotexture. No focal lesions are observed. Visible vasculature and biliary tree appear normal without distension or congestion.

Gallbladder is non-distended in size. The wall is smooth without visible thickening. Luminal contents are primarily anechoic. There is no evidence of cystic or common bile duct dilation.

Gastrointestinal

The visible stomach wall is normal in thickness and layering. The lumen of the stomach is empty with no evidence of obstruction, foreign material or infiltrative disease. Pyloric outflow tract appears patent.

The visible small intestine demonstrates areas of moderate to severely thick muscularis layer relative to mucosa (disruption of the normal 1:3 muscularis:mucosa ratio). Small intestinal submucosa is slightly irregular, thick and hyperechoic, without evident loss of layering appreciated. The lumen of the small intestine is empty with no evidence of obstruction or foreign material.

The visible colon is normal in wall thickness (< 0.2 cm) and layering. Contents are consistent with normal formed feces and gas.

Pancreas

Pancreas is prominent in size with swollen irregular contour. Parenchyma is heterogenous characterized by hyperechoic tissue remodeling intermixed with ill-defined hypoechoic nodules. There is no visible pancreatic duct dilation. There is no evidence of active peripancreatic inflammation. Specifically, the most distinct discrete nodule measured 0.90 cm in size in the mid left limb.

Free Abdomen

There is no visible free peritoneal effusion noted in these images.

There is no apparent pathologic lymphadenopathy noted in these images.

ULTRASONOGRAPHIC FINDINGS

- Suspect pancreatic nodular hyperplasia- Infiltrative neoplasia cannot be ruled out but is considered less likely. Low-grade smoldering chronic pancreatitis cannot be ruled out and should be suspected in the face of appropriate clinical signs.
- Hypo- to anechoic splenic nodule- likely represents a benign lesion such as a cyst, hematoma, nodular hyperplasia, extramedullary hematopoiesis, etc., however while considered less likely, infiltrative neoplasia can mimic benign lesions and cannot be ruled out.
- Moderate inflammatory bowel disease pattern- Thick muscularis has been reported with infiltrative bowel disease including both benign inflammatory disease as well as infiltrative neoplasia such as

lymphoma. No loss of layering or distinct characteristics of malignancy are present. Therefore, differentials cannot be further ranked without tissue sampling.

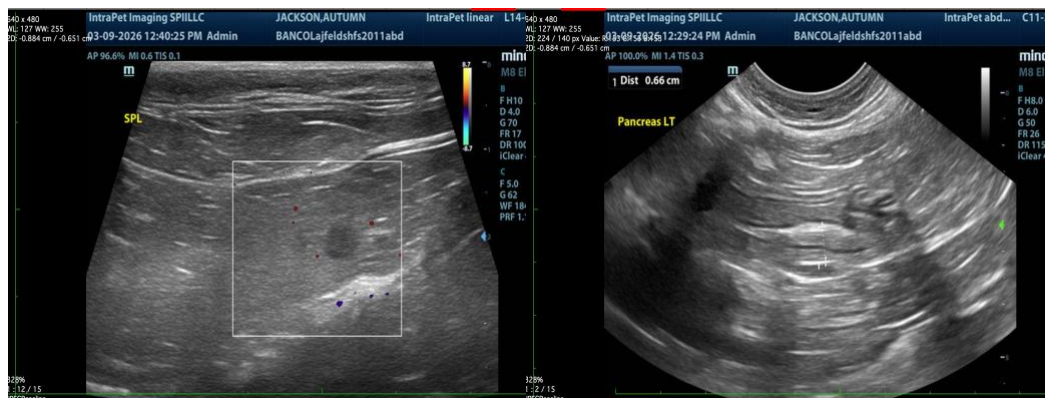
- A mild amount of echogenic urinary bladder debris.

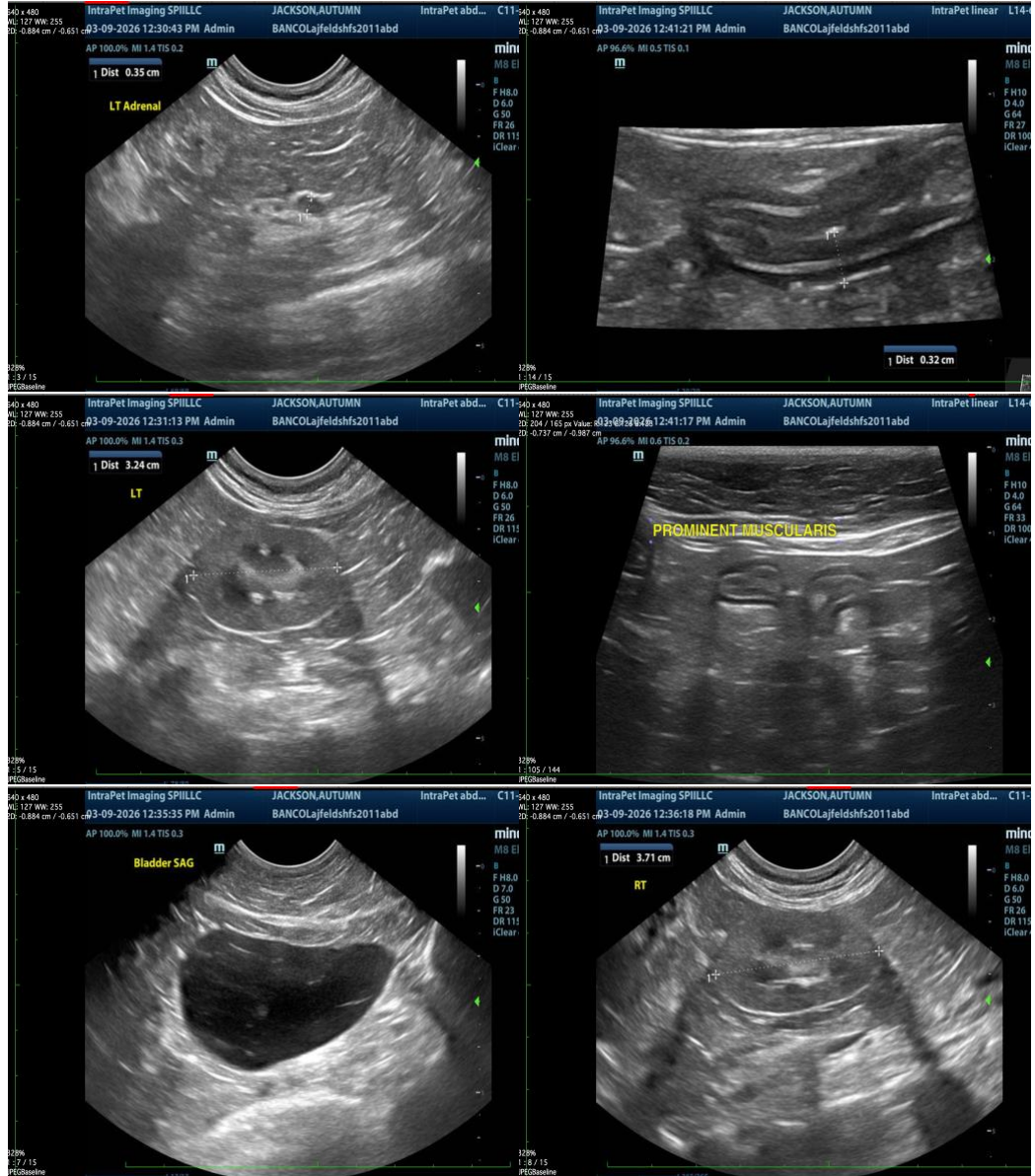
INTERPRETATION OF THE FINDINGS & FURTHER RECOMMENDATIONS

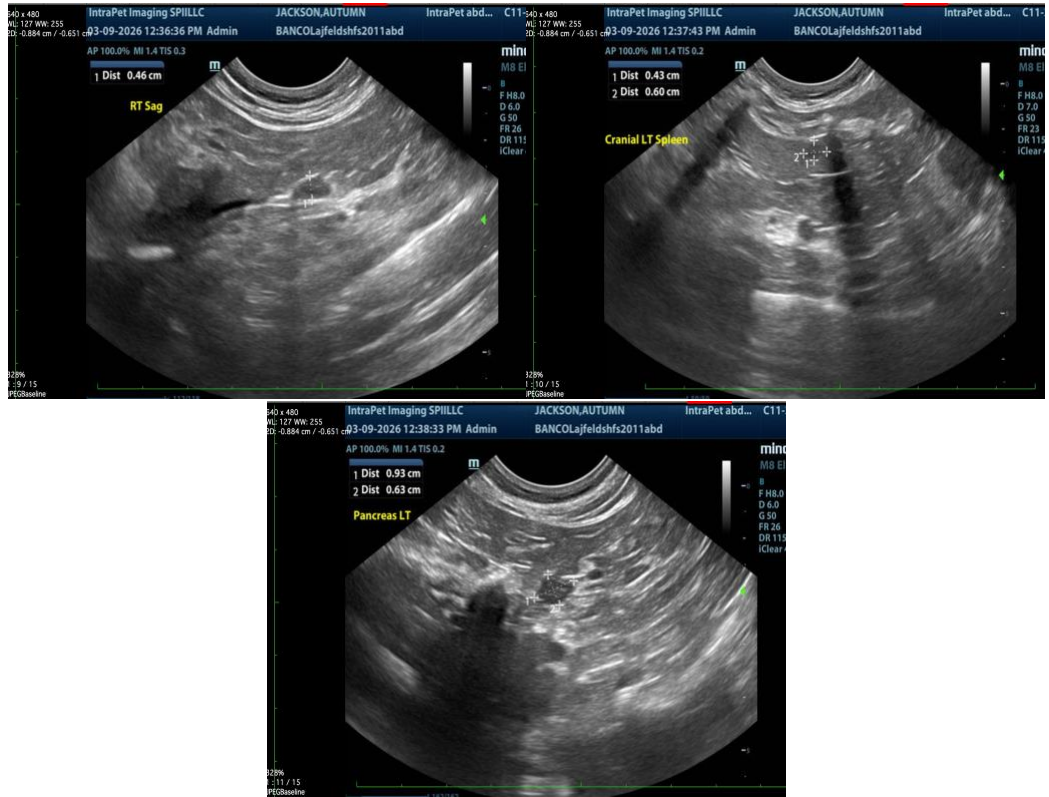
Three view thoracic radiographs are recommended for further assessment of cardio-pulmonary status as well as to further evaluate for any evidence of metastatic disease, if not recently evaluated.

Ideally, if they could safely be reached, fine needle aspirates of the left limb pancreatic nodule and the splenic nodule can be considered if patient's coagulation status is appropriate. Having said that, they may be too small to be reached as both, especially the splenic nodule, are small in size.

- A gastrointestinal malabsorption panel (including cobalamin, folate, TLI and PLI) to Texas A&M GI Laboratory is recommended for further evaluation of GI and pancreatic function.
- Ideally, biopsies of the GI tract, being sure to include ileum, if possible, are recommended to definitively diagnose and therefore manage the infiltrative bowel disease.
- If biopsies cannot be obtained, empirical therapies could include a probiotic (if diarrhea is present, such as visbiome or proviable), empirical deworming with a 5-day course of Panacur and, if tolerated, a transition in diet, based on trial-and-error response, beginning with a hydrolyzed protein diet. Some patients respond to one brand/version of a hydrolyzed protein diet better than another brand, so several trials may be required.
- Additional considerations could include cobalamin supplementation (unless cobalamin level is evaluated and supplementation is not warranted) and prednisolone (if not contraindicated based on patient contraindications, co-morbidities, etc.).







The information and recommendations provided are based on the images presented by the referring veterinarian/sonographer. No evaluation can be communicated regarding pathology that was not visible in the image/video clips provided.

Thank you for this referral. If the clinical or image interpretation does not parallel your findings or if I can be of any further assistance, please contact me.

Beth Johnson, DVM DACVIM

info@sonopath.com