



PATIENT

Tyson Firrincili

SPECIES

Canine

BREED

Lab X

SEX

Neutered Male

AGE

11 Years

WEIGHT

N/A

INTERPRETED BY

Beth Johnson, DVM
DACVIM

IMAGING PERFORMED BY

Diane McFadden

HOSPITAL NAME

AH of Roxbury

REFERRING VET

Dr. Elia

INVOICE

45816

DATE

3/9/23

PRESENTING CLINICAL SIGNS

Recheck ultrasound from Dec 2022. 3 months post right kidney removal.

ULTRASONOGRAPHIC EXAMINATION OF THE ABDOMEN

Urinary System

The urinary bladder is moderately distended with anechoic contents. No masses, inflammatory changes, echogenic sediment or cystoliths are observed. The urinary bladder, trigone and visible pelvic urethra are normal in thickness with a smooth mucosal surface.

Prostate is normal in size, echotexture and echogenicity for a neutered male.

The right kidney has been previously removed.

The left kidney is normal in size (7.49 cm), shape and echogenicity. It has smooth peripheral margination. There is a normal 1:3 cortex to medulla ratio with appropriate corticomedullary distinction. There is no evidence of pyelectasia, mineral or infarcts observed.

Adrenal Glands

The right adrenal gland is normal in size (2.2 cm long x 1.53 cm at the cranial pole and 0.50 cm at the caudal pole), shape and contour. Corticomedullary structure is unremarkable. Visible surrounding vasculature appears normal.

The left adrenal gland is normal in size (2.43 cm long x 0.52 cm at the cranial pole and 0.55 cm at the caudal pole), shape and contour. Corticomedullary structure is unremarkable. Visible surrounding vasculature appears normal.

Spleen

The spleen is subjectively normal in size with a normal smooth capsular contour. Parenchyma is appropriately finely textured and homogenous with normal echogenicity relative to surrounding tissue (hyperechoic to liver). A 1.3 cm x 0.86 cm hypo- to anechoic non-capsule disrupting noduld is noted near the tail of the spleen. Splenic vasculature appears normal.

Liver

The liver is subjectively normal in size with normal smooth curvilinear peripheral contour. Parenchyma is appropriately hypoechoic to the spleen in echogenicity and appropriately mildly coarse and homogenous in echotexture. No focal lesions are observed. Visible vasculature and biliary tree appear normal without distension or congestion.

The gallbladder is non-distended in size. The wall is smooth without visible thickening. Luminal contents are primarily anechoic. There is no evidence of cystic or common bile duct dilation.

Gastrointestinal

The visible stomach wall is normal in thickness and layering. The lumen of the stomach is mildly distended with echogenic non-shadowing luminal contents and gas consistent with normal ingesta. There is no evidence of obstruction, foreign material or infiltrative disease. Pyloric outflow tract appears patent.

The visible small intestines are normal in wall thickness and layering (canine duodenum < 0.5 cm and feline duodenum < 0.4 cm; other < 0.3 cm). Small intestinal motility appears adequate (1-3 contractions per min). The lumen of the small intestine is empty with no evidence of obstruction, foreign material or infiltrative disease.



PATIENT

Tyson Firrincili

The visible colon is normal in wall thickness (< 0.2 cm) and layering. Contents are consistent with normal formed feces and gas.

SPECIES

Canine

Pancreas

The pancreatic parenchyma is appropriately isoechoic to surrounding tissue. Visible capsule is smooth and normal in contour. There is no visible pancreatic duct dilation. There is no evidence of active peripancreatic inflammation.

BREED

Lab X

Free Abdomen

There is no evidence of free peritoneal effusion noted in these images.

SEX

Neutered Male

There is no apparent lymphadenopathy noted in these images.

AGE

11 Years

There is no evidence of heart base or pericardial pathology noted in these images at this time. If cardiac function evaluation is desired a full echocardiogram is recommended.

WEIGHT

N/A

ULTRASONOGRAPHIC FINDINGS

- **Hypo to anechoic splenic nodule** – likely represents a benign lesion such as a cyst, hematoma, nodular hyperplasia, extramedullary hematopoiesis, etc., however while considered less likely, infiltrative neoplasia can mimic benign lesions, and cannot be ruled out. The nodule appears static to the previous ultrasound.
- This patient's right kidney has been removed.

INTERPRETED BY

Beth Johnson, DVM
DACVIM

INTERPRETATION OF THE FINDINGS & FURTHER RECOMMENDATIONS

Recommendations depend on what the histologic diagnosis of the removed kidney was, and if malignant, then follow up recommendations should be based on consultation with a veterinary oncologist. There is no evidence of visible intraabdominal metastatic disease present at this time.

IMAGING PERFORMED BY

Diane McFadden

HOSPITAL NAME

AH of Roxbury

REFERRING VET

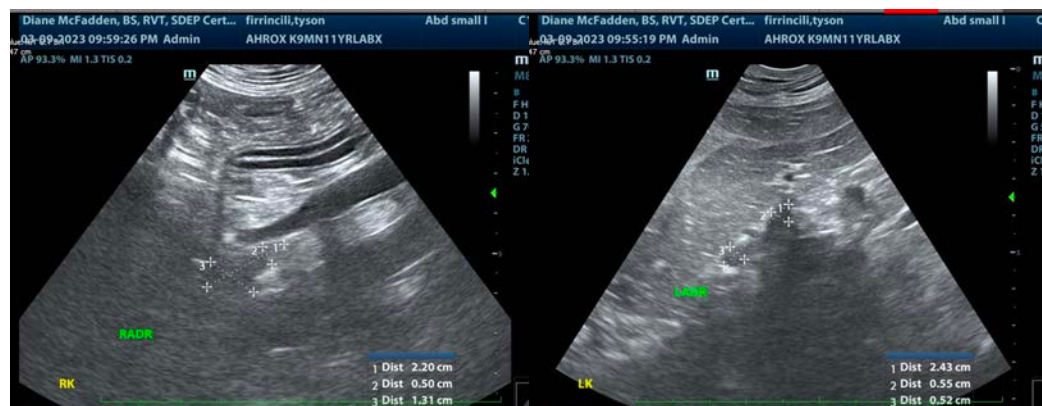
Dr. Elia

INVOICE

45816

DATE

3/9/23





PATIENT

Tyson Firrincili

SPECIES

Canine

BREED

Lab X

SEX

Neutered Male

AGE

11 Years

WEIGHT

N/A

INTERPRETED BY

Beth Johnson, DVM
DACVIM

IMAGING PERFORMED BY

Diane McFadden

HOSPITAL NAME

AH of Roxbury

REFERRING VET

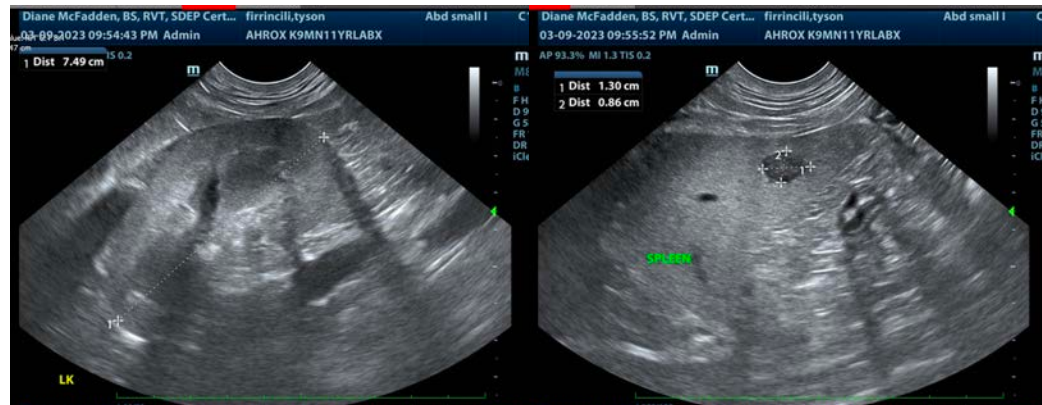
Dr. Elia

INVOICE

45816

DATE

3/9/23



The information and recommendations provided are based on the images presented by the referring veterinarian/sonographer. No evaluation can be communicated regarding pathology that was not visible in the image/video clips provided.

Thank you for this referral. If the clinical or image interpretation does not parallel your findings or if I can be of any further assistance please contact me.

Beth Johnson, DVM, DACVIM
Beth.Johnson@sonopath.com