

**DATE PRESENTING CLINICAL SIGNS**

3/9/23

History of weight loss and decreased appetite, intermittent loose stools. dx hyperthyroid 10/2022, still in the process of getting regulated, but thickened intestines on u/s so concern for comorbidities causing weight loss and changes in appetite, does have severe dental disease

PATIENT

Sophie Brocato

Current Medications: Methimazole transdermal 7.5 mg in AM 5 mg in PM

Lab Results: Most recent labs in Nov 2022 showed hyperglobulinemia, neutrophilia and monocytosis, T4 at 8.8.

SPECIES

Feline

Date of Previous IntraPet Ultrasound: No previous.

Sedation: Not required to complete full diagnostic ultrasound.

BREED

DSH

Stat Report: Not requested.

Imaging Performed By:

SEX

Spayed Female

ULTRASONOGRAPHIC EXAMINATION OF THE ABDOMEN**Urinary System**

Urinary bladder is adequately distended with anechoic contents. No masses, inflammatory changes, echogenic sediment or cystoliths are observed. The urinary bladder, trigone and visible pelvic urethra are normal in thickness with a smooth mucosal surface.

AGE

5/12/11

Kidneys are overall normal in size and shape with smooth peripheral margination. A normal 1:3 cortex to medulla ratio is maintained. The medulla and cortices are uniform in texture with some mild increased cortical echogenicity and mild loss of corticomedullary distinction, expected in this age patient. There is no evidence of pyelectasia, mineral or infarcts observed. The left kidney measures 3.71 cm. The right kidney measures 4.07 cm.

WEIGHT

7.6 Pounds

INTERPRETED BY

Beth Johnson, DVM

DACVIM

Adrenal Glands

Left adrenal gland is normal in size (0.42 cm), shape and overall architecture, echogenicity and echotexture. Visible surrounding vasculature appears normal.

Right adrenal gland is normal in size (0.49 cm), shape and overall architecture, echogenicity and echotexture. Visible surrounding vasculature appears normal.

HOSPITAL NAME

Everhart VH

Spleen

Spleen is subjectively normal in size with a normal smooth capsular contour. Parenchyma is appropriately finely textured and homogenous with normal echogenicity relative to surrounding tissue (hyperechoic to liver). No focal nodules or masses are observed. Splenic vasculature appears normal.

REFERRING VET

Dr. Hess

Liver

Liver is subjectively normal in size with normal smooth curvilinear peripheral contour. Parenchyma is appropriately hypoechoic to the spleen in echogenicity and appropriately mildly coarse and homogenous in echotexture. In the right caudal liver, a 0.8 cm round, primarily hyperechoic, partially cystic nodule is noted. Visible vasculature and biliary tree appear normal without distension or congestion.

INVOICE

21538

Gallbladder is moderately distended with anechoic bile as well as mild suspended and gravity dependent echogenic debris. The wall is smooth without visible thickening. There is no evidence of cystic or CBD dilation. There is no evidence of effusion or inflammation.

Gastrointestinal

The visible stomach wall is normal in thickness and layering. The lumen of the stomach is mildly distended with echogenic non-shadowing luminal contents and gas consistent with normal ingesta. There is no evidence of obstruction, foreign material or infiltrative disease. Pyloric outflow tract appears patent. The visible small intestines are normal in wall thickness and layering. Small intestinal motility appears adequate (1-3 contractions per min). The lumen of the small intestine is mildly distended with echogenic non-shadowing luminal contents and gas consistent with normal ingesta. There is no evidence of obstruction, foreign material or infiltrative disease.

The visible colon is normal in wall thickness and layering. Contents are consistent with normal formed feces and gas.

Pancreas

Pancreas is prominent (enlarged) in size, hypoechoic to surrounding tissue and has a mildly irregular undulating contour. Parenchyma is coarse with mixed echogenic remodeling noted. Pancreatic duct dilation is noted.

Free Abdomen

There is no evidence of peritoneal effusion. The mesenteric lymph nodes are prominent in size with swollen capsular contour. Normal elongated shape (length to width ratio) is maintained. There is no loss of parenchymal detail.

ULTRASONOGRAPHIC FINDINGS

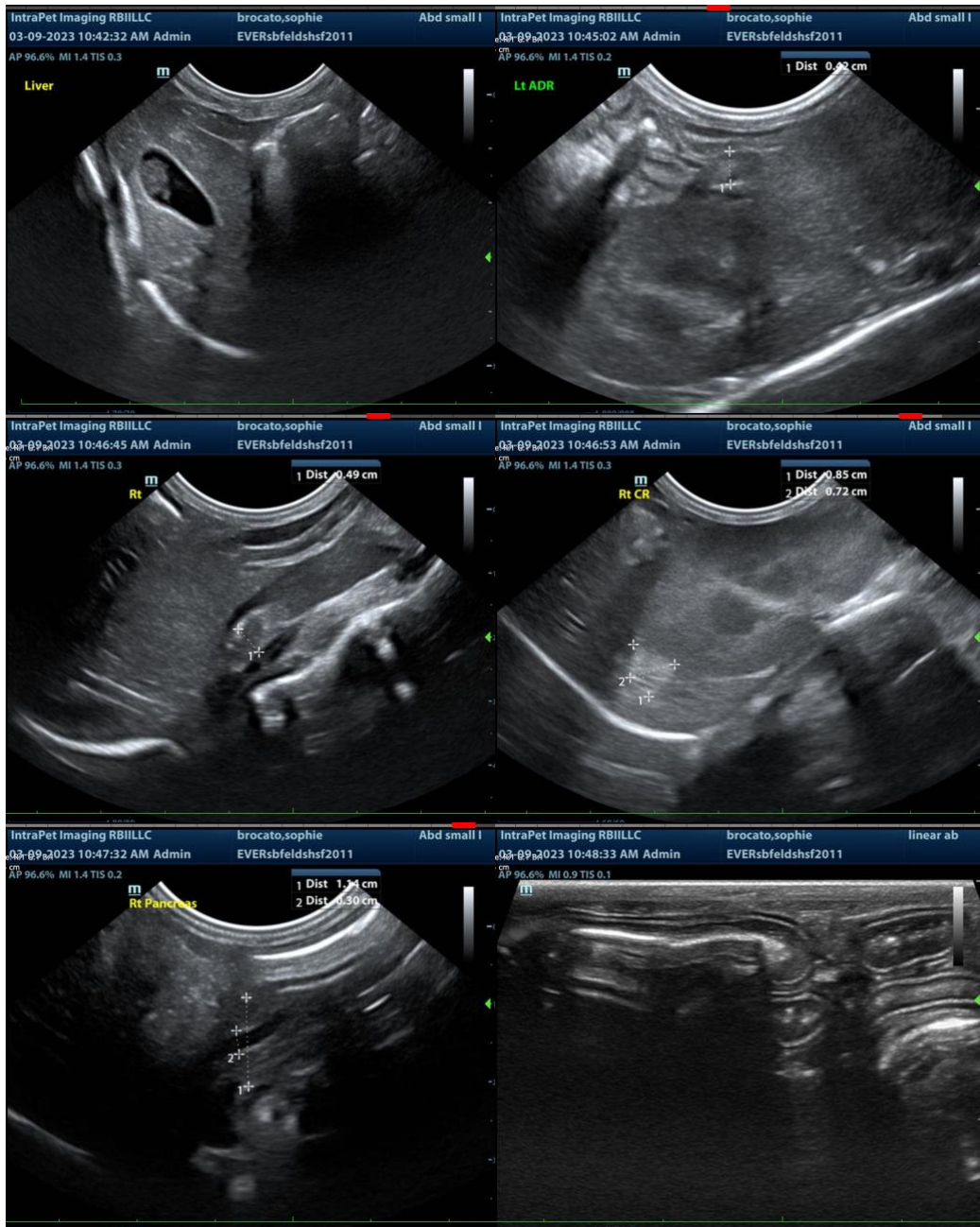
- Feline biliary cystadenoma – In a senior cat, this liver lesion is most consistent with a benign biliary cystadenoma. Malignancy cannot be ruled out but is considered less likely given lack of clinical signs and/or laboratory changes.
- Chronic active pancreatitis
- Mild gallbladder debris – Cholecystic debris is of unknown clinical significance. It can be seen with biliary stasis from fasting or illness, however, it can also be associated with hepatobiliary disease in cats and should be interpreted in combination with clinical signs such as nausea, inappetence, cranial abdominal discomfort and/or laboratory changes such as increased ALP and/or increased Tbili.
- Age-related kidney changes
- Reactive mesenteric lymph nodes – infiltrative neoplastic disease cannot be ruled out but is considered less likely.

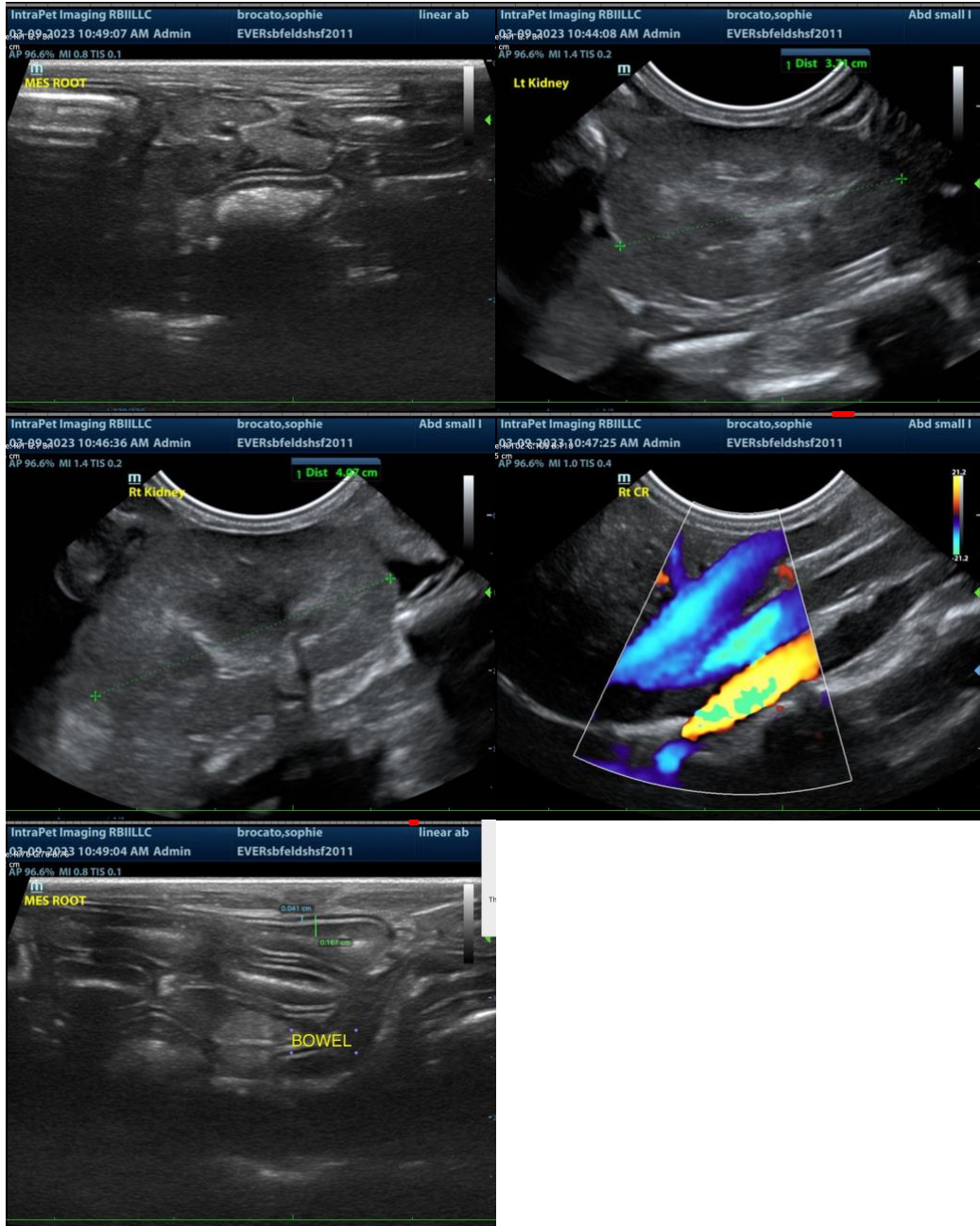
INTERPRETATION OF THE FINDINGS & FURTHER RECOMMENDATIONS

There is no significant ultrasonographically visible evidence of gastrointestinal disease in these images at this time. Having said that, maldigestive and malabsorptive conditions can be present with very little to no ultrasound change, therefore a gastrointestinal malabsorption panel (including cobalamin, folate, TLI and PLI) to Texas A&M GI Laboratory is recommended for further evaluation of GI and pancreatic function.

In this patient, a larger concern is the hyperthyroidism, as this patient is reportedly receiving a moderate to high dose of Methimazole with a still significantly increased T4. Therefore, recommendations include checking compliance of topical Methimazole administration, and if compliance is good, and patient is believed to adequately be receiving treatment, then further evaluation for potentially more aggressive or even malignant hyperthyroidism should be considered. In which case, a fine needle aspirate of the thyroid

gland could be considered, if patients coagulation status is appropriate, and/or a CT scan to evaluate for ectopic thyroid tissue, etc., prior to potentially, ultimately considering wither surgery or i131 therapy.





The information and recommendations provided are based on the images presented by the referring veterinarian. No evaluation can be communicated regarding pathology that was not visible in the image/video clips provided.

Thank you for this referral. If the clinical or image interpretation does not parallel your findings or if I can be of any further assistance please contact me.

Beth Johnson, DVM DACVIM
Beth.Johnson@SonoPath.com