

**DATE PRESENTING CLINICAL SIGNS**

3/9/23

PATIENT

Sarah Bear Miller

History: Presented in Jan 2023 for urinary accidents, appeared to be incontinence. PU/PD noted as well as weight loss. Now presents for some improvement in amt of urine voided but still some leaking and polydipsia still present. Lump on LH tarsus that has grown per owner. Some weight gain since last appt (used to be around 52#, then dropped to 45# around jan 2023, now 47# as of march 2023). Heavy tartar on teeth. Otherwise nsf on exam

SPECIES

Canine

Current Medications: Currently on incurin 1mg q48hr

Lab Results: Superchem/cbc/ua/t4 (jan 2023): usg 1.008 with quiet sediment. bg 94 (march 2023). UA/culture pending as of march 1 2023

BREED

Chow Chow

first am usg - o to collect

Date of Previous IntraPet Ultrasound: No previous.

Sedation: IV Torb.

Stat Report: Not requested.

SEX

Spayed Female

Imaging Performed By: Rachel Brillhart, RDMS.

ULTRASONOGRAPHIC EXAMINATION OF THE ABDOMEN**AGE**

12/12/09

Urinary System

Urinary bladder is adequately distended with anechoic contents. No masses, inflammatory changes, echogenic sediment or cystoliths are observed. The urinary bladder, trigone and visible pelvic urethra are normal in thickness with a smooth mucosal surface.

WEIGHT

47.2 Pounds

Left kidney is normal is size (5.38 cm), shape and echogenicity. It has smooth peripheral margination. There is a normal 1:3 cortex to medulla ratio with appropriate corticomedullary distinction. There is no evidence of pyelectasia, mineral or infarcts observed.

INTERPRETED BYBeth Johnson, DVM
DACVIM

Right kidney is normal is size (5.15 cm), shape and echogenicity. It has smooth peripheral margination. There is a normal 1:3 cortex to medulla ratio with appropriate corticomedullary distinction. There is no evidence of pyelectasia, mineral or infarcts observed.

HOSPITAL NAME

Everhart VH

Adrenal Glands

Left adrenal gland is normal in size (2.56 cm long x 0.61 cm at cranial pole and 0.85 cm at caudal pole), shape and overall architecture, echogenicity and echotexture. Visible surrounding vasculature appears normal.

REFERRING VET

Dr. Betta

Right adrenal gland is normal in size (2.89 cm long x 0.93 cm at cranial pole and 0.76 cm at caudal pole), shape and overall architecture, echogenicity and echotexture. Visible surrounding vasculature appears normal. A hyperechoic nodule is noted in the cranial pole of the right adrenal gland. Nodule does not disrupt normal shape and/or architecture.

INVOICE

21537

Spleen

Spleen is subjectively normal in size with a normal smooth capsular contour. Parenchyma is appropriately finely textured and homogenous with normal echogenicity relative to surrounding tissue (hyperechoic to liver). No focal nodules or masses are observed. Splenic vasculature appears normal.

Liver

Liver is subjectively enlarged with mildly irregular margins. Parenchyma is heterogenous characterized by multiple poorly defined hypoechoic nodules within otherwise hyperechoic liver parenchyma. Visible vasculature and biliary tree appear normal without distension or congestion.

Gallbladder is non-distended in size. The wall is smooth without visible thickening. Luminal contents are primarily anechoic. There is no evidence of cystic or common bile duct dilation.

Gastrointestinal

The visible stomach wall is diffusely thick, measuring up to 0.78 cm thick with intact layering but a disproportionately thick muscularis layer relative to the mucosa. The lumen of the stomach is empty with no evidence of obstruction, foreign material or infiltrative disease. Pyloric outflow tract appears patent.

The visible small intestine demonstrates areas of thick muscularis layer relative to mucosa (disruption of the normal 1:3 muscularis:mucosa ratio). Small intestinal submucosa is slightly irregular, thick and hyperechoic, without evident loss of layering appreciated. The lumen of the small intestine is empty with no evidence of obstruction or foreign material.

The visible colon is normal in wall thickness and layering. Contents are consistent with normal formed feces and gas.

Pancreas

The observed pancreas appears appropriately isoechoic to surrounding omental fat. Visible capsule is smooth and normal in contour. Visible pancreatic parenchyma is homogenous and unremarkable. There is no visible pancreatic duct dilation. There is no evidence of active peripancreatic inflammation.

Free Abdomen

There is no evidence of peritoneal effusion. The mesenteric lymph nodes are prominent in size with swollen capsular contour. Normal elongated shape (length to width ratio) is maintained. There is no loss of parenchymal detail.

A subjectively prominent uterine stump is noted.

ULTRASONOGRAPHIC FINDINGS

- Inflammatory bowel disease (IBD) pattern affecting the stomach and the small bowel diffusely – Thick muscularis has been reported with infiltrative bowel disease including both benign inflammatory disease as well as infiltrative neoplasia such as lymphoma. No aggressive lymphadenopathy, loss of layering, etc. is noted to make lymphoma more probable, but lymphoma cannot be definitively ruled out without tissue sampling.
- Heterogenous Liver – These changes are most consistent with benign processes such as nodular hyperplasia, steroid (vacuolar) hepatopathy, extramedullary hematopoiesis or possibly chronic inflammatory disease and less commonly infiltrative round cell or metastatic neoplasia.
- Reactive mesenteric lymph nodes – infiltrative neoplastic disease cannot be ruled out but is considered less likely.
- Right adrenal cranial pole hyperechoic adrenal nodule – Differentials include primary adrenal cortical adenoma or adenocarcinoma, pheochromocytoma, myelolipoma, adrenal hyperplasia secondary to pituitary disease or metastatic disease. Ultrasound alone cannot differentiate between functional and non-functional nodules and/or between benign and malignant disease.

Small nodules without other evidence of abdominal disease (to suggest metastatic disease) and/or clinical signs (to suggest adrenal disease) are most often incidental and should be monitored.

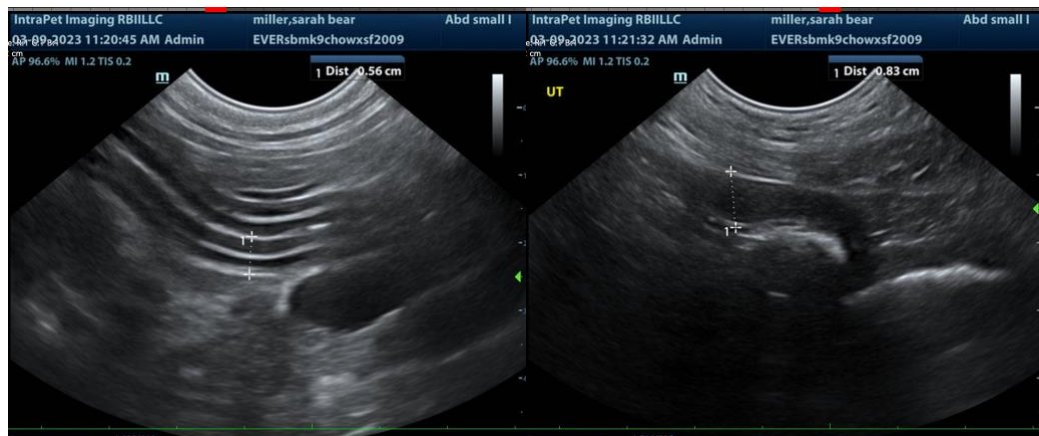
INTERPRETATION OF THE FINDINGS & FURTHER RECOMMENDATIONS

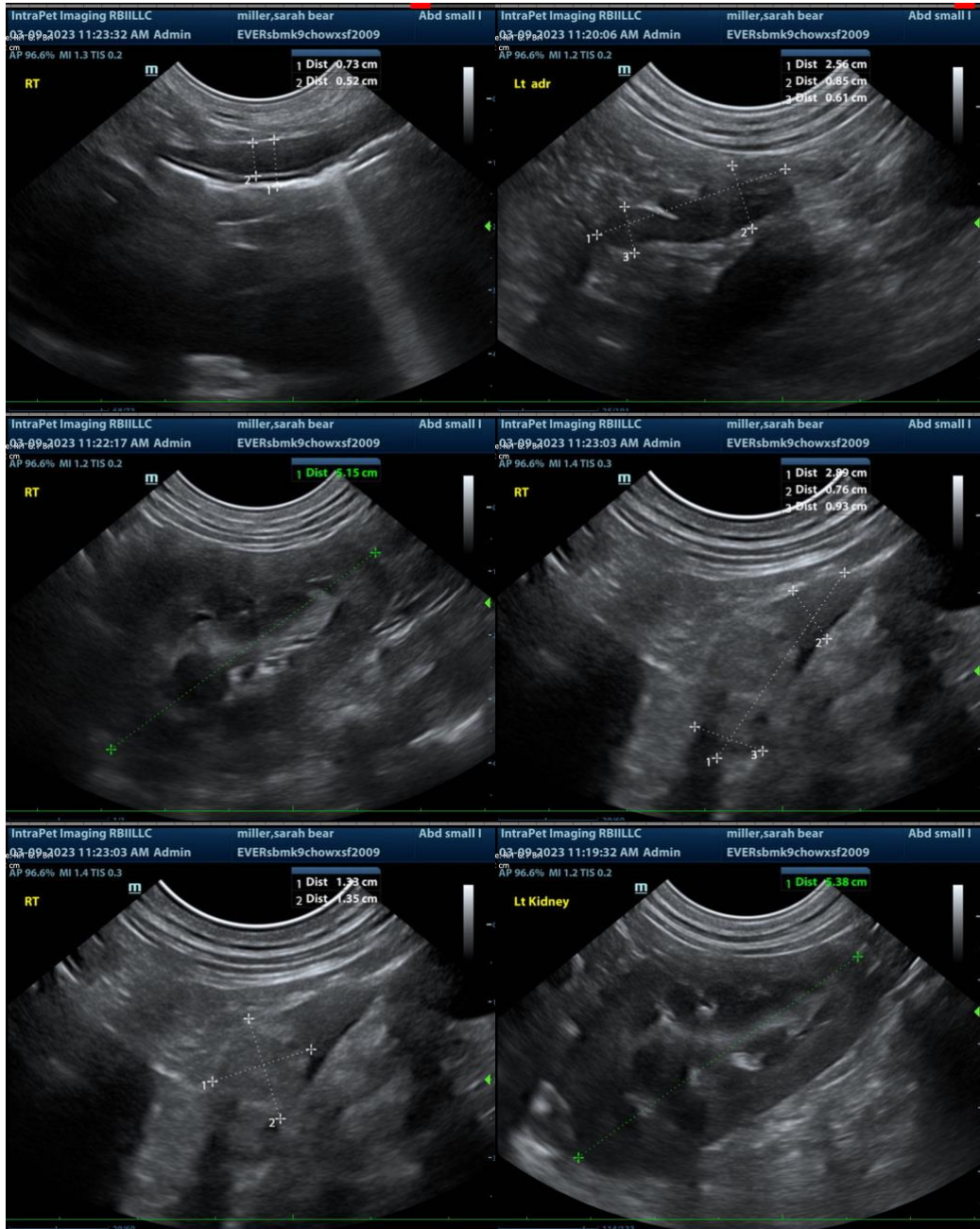
This patient's adrenal nodule could suggest hyperadrenocorticism, either adrenal or pituitary dependent, which could be contributing to the PU/PD, however, hyperadrenocorticism does not typically result in weight loss, and should not be further evaluated and/or treated in the face of concurrent illness, which is suspected in this patient given the gastrointestinal changes and weight loss. Therefore, recommendations are to address the suspected gastrointestinal disease first, and then pending response and future clinical signs, etc., pursue hyperadrenocorticism (if necessary) in the future.

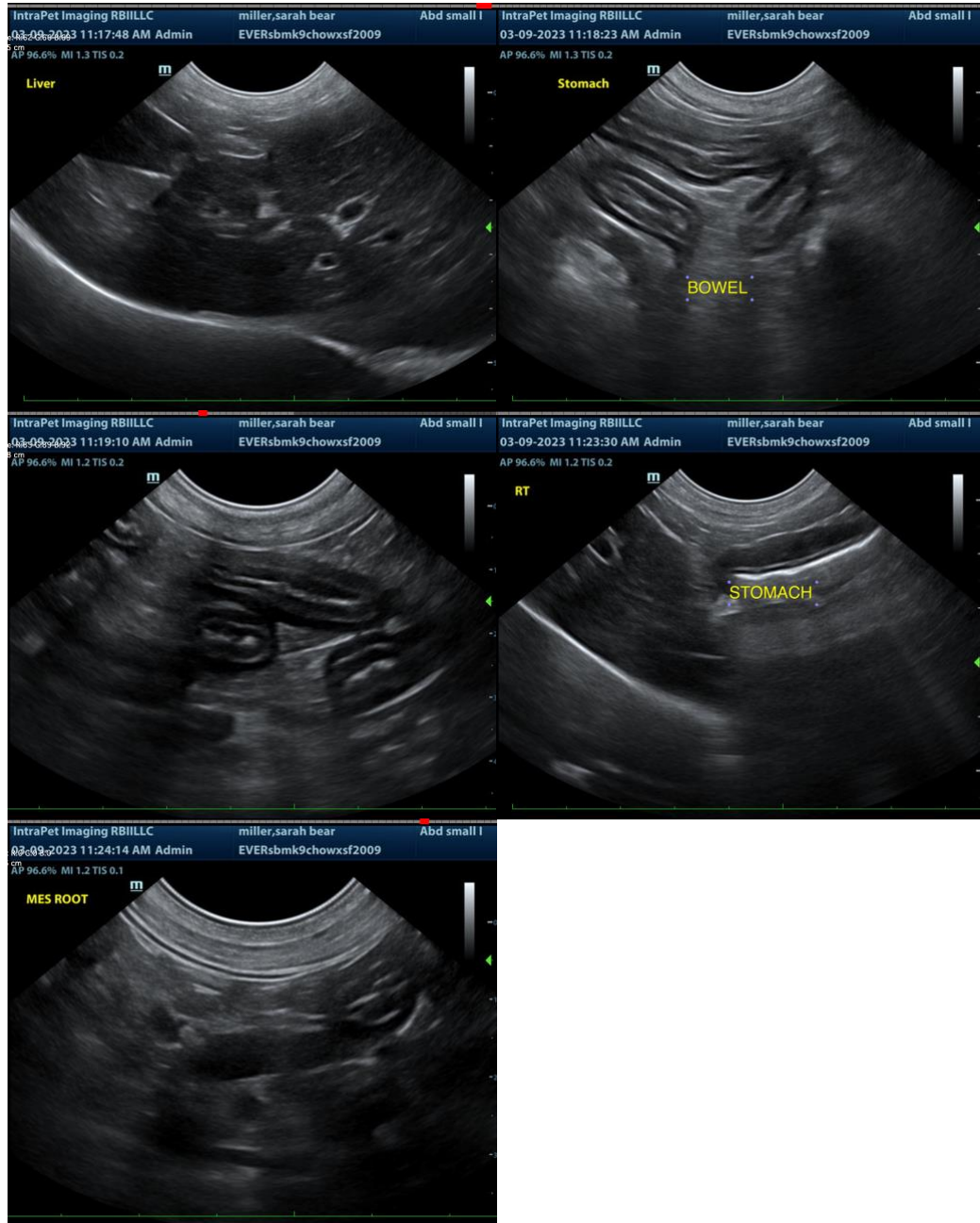
For now, a gastrointestinal malabsorption panel (including cobalamin, folate, TLI and PLI) to Texas A&M GI Laboratory is recommended for further evaluation of GI and pancreatic function.

Ideally, biopsies of the GI tract are recommended to definitively diagnose, and therefore manage the suspected infiltrative bowel disease.

In the meantime, empirical deworming with a 5-day course of Panacur is recommended, as is (if tolerated) a transition in diet, beginning with a hydrolyzed protein diet, understanding that some patients respond to one brand or version of a hydrolyzed diet better than another brand, so several trials may be required. Additional considerations could include cobalamin supplementation, unless cobalamin level is evaluated and supplementation is not warranted.







The information and recommendations provided are based on the images presented by the referring veterinarian. No evaluation can be communicated regarding pathology that was not visible in the image/video clips provided.

Thank you for this referral. If the clinical or image interpretation does not parallel your findings or if I can be of any further assistance please contact me.

Beth Johnson, DVM DACVIM
Beth.Johnson@SonoPath.com