

**DATE PRESENTING CLINICAL SIGNS**

3/7/23

Abdominal ultrasound is recommended, including appropriate evaluation of the layering, thickness and echogenicity of the gastrointestinal tract wall, if a cause for the vomiting is not determined, or if an appropriate and timely response to medical management for the vomiting is not achieved.

PATIENT

Jerry Chase

Current Medications: None listed.

Lab Results: See attached.

Radiographs: See attached report.

SPECIES

Feline

Date of Previous IntraPet Ultrasound: No previous.

Sedation: Not required to complete full diagnostic ultrasound.

Stat Report: Not requested.

BREED

DSH

Imaging Performed By: Stephanie Warga RDCS, RVT.

ULTRASONOGRAPHIC EXAMINATION OF THE ABDOMEN**SEX**

Neutered Male

Urinary System

Urinary bladder is adequately distended. It has a normal uniform wall thickness. Contents include primarily anechoic fluid with occasional echogenic non-shadowing debris, most consistent with incidental suspended lipid in a cat, possibly combined with exfoliated cells, mucous and/or small blood clots. Both sterile inflammation as well as urinary tract infection can also present with echogenic debris. No masses or cystoliths are observed. The trigone and visible pelvic urethra are normal in thickness with a smooth mucosal surface.

AGE

5/1/10

WEIGHT

13.13 Pounds

Kidneys are normal in size with increased cortical echogenicity. Normal smooth peripheral margination and shape are maintained. There is a normal 1:3 cortex to medulla ratio with appropriate corticomedullary distinction. There is no evidence of mineral or infarcts observed. Infiltrative disease (infectious, neoplastic, etc.) or nephritis cannot be ruled out but is considered less likely. The left kidney measures 3.67 cm. The right kidney measures 4.2 cm. Scant pyelectasia is noted in the right kidney measuring 0.18 cm in the transverse view.

INTERPRETED BYBeth Johnson, DVM
DACVIM**Adrenal Glands**

The right adrenal gland is normal in size (0.40 cm), shape and contour. Corticomedullary structure is unremarkable. Visible surrounding vasculature appears normal.

HOSPITAL NAME

Cat Hospital at Towson

The area of the left adrenal gland is examined without evident pathology.

REFERRING VET

Dr. Slaughter

Spleen

The spleen is subjectively normal in size with a normal smooth capsular contour. Parenchyma is appropriately finely textured and homogenous with normal echogenicity relative to surrounding tissue (hyperechoic to liver). No focal nodules or masses are observed. Splenic vasculature appears normal.

INVOICE

45732

Liver

The liver is subjectively normal in size with normal smooth curvilinear peripheral contour. Parenchyma is appropriately hypoechoic to the spleen in echogenicity and appropriately mildly coarse and homogenous in echotexture. No focal lesions are observed. Visible vasculature and biliary tree appear normal without distension or congestion.

The gallbladder is non-distended in size. The wall is smooth without visible thickening. Luminal contents are primarily anechoic. There is no evidence of cystic or common bile duct dilation.

Gastrointestinal

The stomach wall is normal in thickness (canine < 0.5 cm and feline < 0.4 cm) and layering. The lumen of the stomach is empty with no evidence of obstruction, foreign material or infiltrative disease. Pyloric outflow tract appears patent.

The visible small intestine demonstrates areas of mildly thick muscularis layer relative to mucosa (disruption of the normal 1:3 muscularis:mucosa ratio). Small intestinal submucosa is slightly irregular, thick and hyperechoic, without evident loss of layering appreciated. The lumen is empty with no evidence of obstruction or foreign material. Changes are most notable near the ileocecolic junction.

The visible colon is normal in wall thickness (< 0.2 cm) and layering. Contents are consistent with normal formed feces and gas.

Pancreas

The observed pancreas appears appropriately isoechoic to surrounding omental fat. The capsule is mildly irregular in shape. Parenchyma is mildly heterogenous and coarse. There is no visible pancreatic duct dilation. There is no evidence of active peripancreatic inflammation.

Free Abdomen

There is no evidence of free peritoneal effusion noted in these images.

The mesenteric lymph nodes are prominent in size with swollen capsular contour. Normal elongated shape (length to width ratio) is maintained. There is no loss of parenchymal detail.

Additionally, a round hypoechoic lymph node measuring 0.70 cm x 0.80 cm is noted in the caudal abdomen near the colon.

PRIMARY FINDINGS

- **Mild inflammatory bowel disease (IBD) pattern** – Thick muscularis has been reported with infiltrative bowel disease including both benign inflammatory disease as well as infiltrative neoplasia such as lymphoma. No aggressive lymphadenopathy, loss of layering, etc. is noted to make lymphoma more probable, but lymphoma cannot be definitively ruled out without tissue sampling.
- **Reactive mesenteric and colonic lymph nodes** – infiltrative neoplastic disease cannot be ruled out but is considered less likely.

SECONDARY FINDINGS

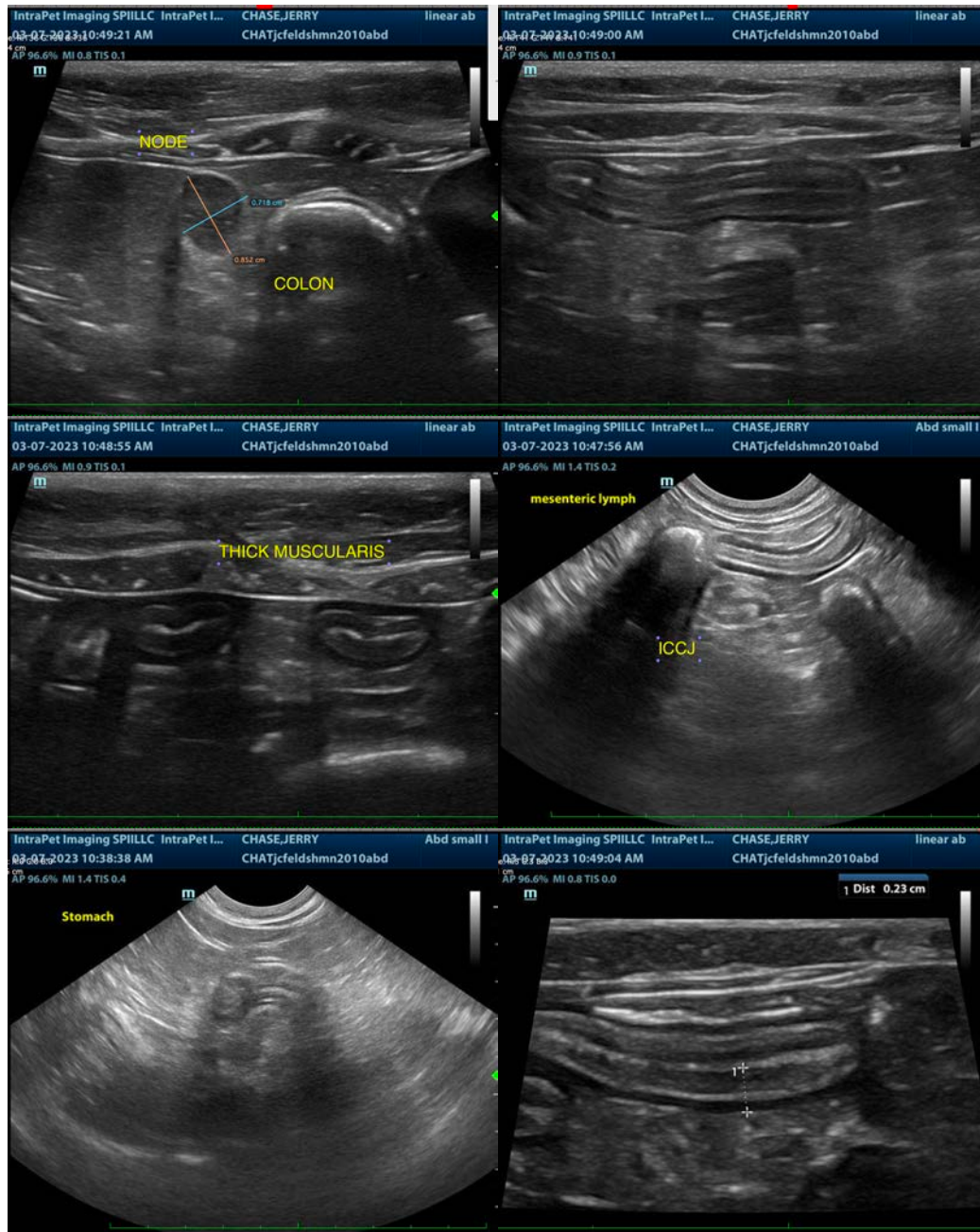
- **Pancreatic age-related remodeling** – Mild irregularities are consistent with benign age-related change. Low-grade smoldering chronic pancreatitis cannot be ruled out and should be suspected in the face of appropriate clinical signs.
- Urinary bladder debris and very mild pyelectasia in the right kidney

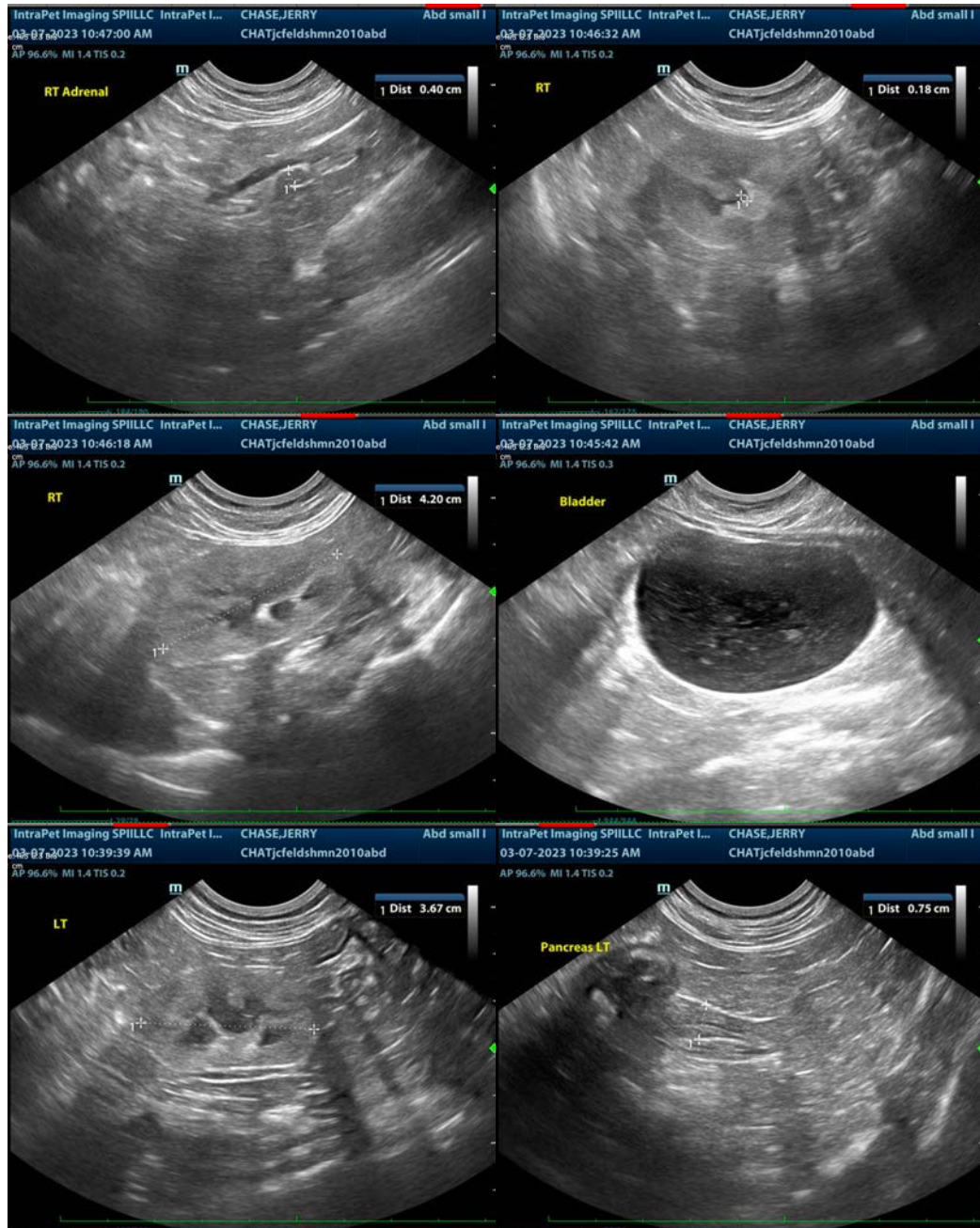
INTERPRETATION OF THE FINDINGS & FURTHER RECOMMENDATIONS

A gastrointestinal malabsorption panel (including cobalamin, folate, TLI and PLI) to Texas A&M GI Laboratory is recommended for further evaluation of GI and pancreatic function.

Ideally, biopsies of the GI tract, being sure to include ileum if possible, are recommended to definitively diagnose and therefore manage the infiltrative bowel disease.

If biopsies cannot be obtained, empirical therapies could include diet change, empirical deworming with a 5 day course of Panacur, cobalamin supplementation (unless cobalamin level is evaluated and supplementation is not warranted) and prednisolone (if not contraindicated based on patient contraindications, co-morbidities, etc.). Other supportive therapeutic considerations could include fiber supplementation, especially with large bowel diarrhea and/or a probiotic.





The information and recommendations provided are based on the images presented by the referring veterinarian/sonographer. No evaluation can be communicated regarding pathology that was not visible in the image/video clips provided.

Thank you for this referral. If the clinical or image interpretation does not parallel your findings or if I can be of any further assistance please contact me.

Beth Johnson, DVM, DACVIM
Beth.Johnson@sonopath.com