

**DATE PRESENTING CLINICAL SIGNS**

3/7/23 Concern for emerging kidney disease, annual senior blood work showed mild azotemia, no clinical signs at home. PE: unremarkable

PATIENT

Bailey Adams Current Medications: None.
Lab Results: Renal Chem 2/4/23: SDMA 19, Creat 1.3, BUN 28. 2/27/23 SDMA 23, Creat 1.6, BUN 32. UA free catch- yellow and clear, USG 1.019, pH 6, protein negative.
Date of Previous IntraPet Ultrasound: No previous.

SPECIES

Canine Sedation: Torbugesic IV.
Stat Report: Not requested.
Imaging Performed By: Stephanie Warga RDCS, RVT.

BREED

Chihuahua

LIMITED ULTRASONOGRAPHIC EXAMINATION**Urinary System**

Urinary bladder is only mildly distended, resulting in a mildly thick, irregular appearing wall, but can't be interpreted as pathologic or not in a non-distended bladder. Contents include primarily anechoic fluid with occasional echogenic non-shadowing debris, most consistent with exfoliated cells, mucous and/or small blood clots. Both sterile inflammation as well as urinary tract infection can also present with echogenic debris. No masses or cystoliths are observed. The trigone and visible pelvic urethra are normal in thickness with a smooth mucosal surface.

SEX

Neutered Male

AGE

10/9/08

WEIGHT

11.9 Pounds

Prostate is mildly enlarged. Parenchyma is diffusely homogenous and mildly hypoechoic to surrounding tissue. Normal distinct margins and symmetrical bilobed shape are maintained. This finding is likely normal patient variant, especially if patient was neutered as an adult; however, if patient was neutered as a puppy, prostatitis or, less likely, infiltrative neoplasia cannot be ruled out. This finding should be interpreted in combination with clinical signs, urinalysis results, etc. and either further investigated or monitored, as indicated.

INTERPRETED BY

Beth Johnson, DVM
DACVIM

Kidneys are overall normal in size and shape with smooth peripheral margination. A normal 1:3 cortex to medulla ratio is maintained. The medulla and cortices are uniform in texture with some mild increased cortical echogenicity and mild loss of corticomedullary distinction, expected in this age patient. There is no evidence of infarcts observed. The left kidney measures 3.45 cm. The right kidney measures 3.19 cm. Mild pyelectasia noted bilaterally, 0.28 cm in the transverse view on the left and 0.36 cm in the transverse view on the right. Non-obstructive linear multifocal hyperechoic diverticular foci with acoustic shadowing are noted in both kidneys.

HOSPITAL NAME

Perry Hall AH

REFERRING VET

Dr. Baer

ULTRASONOGRAPHIC FINDINGS**INVOICE**

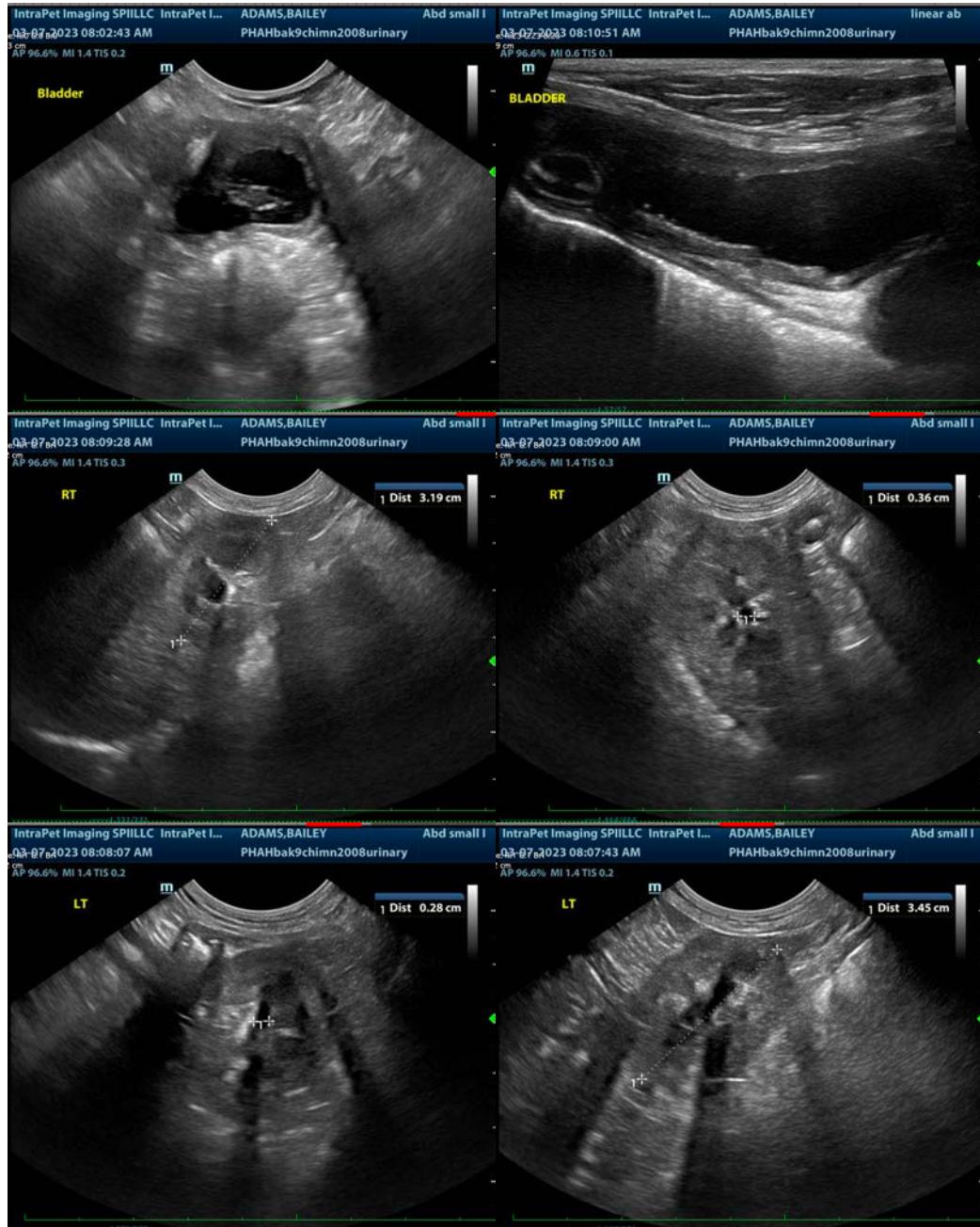
45733

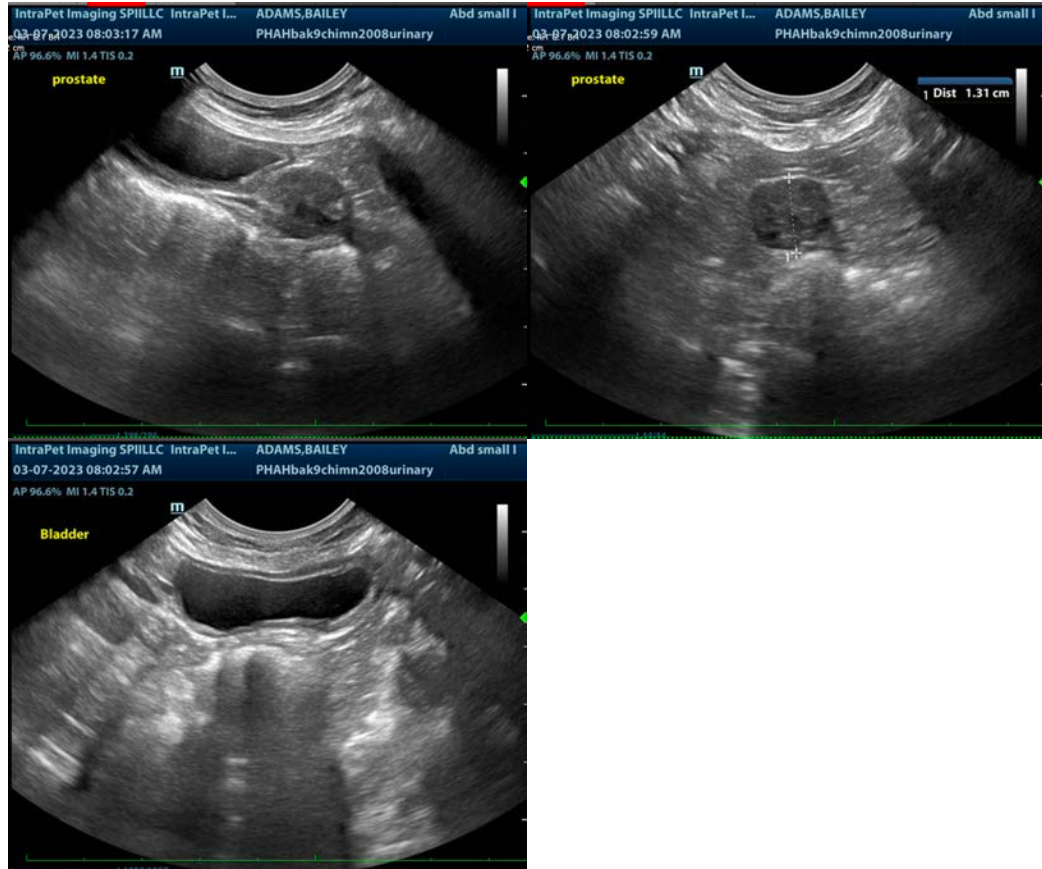
- Bilateral age-related kidney changes with mild bilateral pyelectasia and non-obstructive dystrophic mineralization – Differentials for pyelectasia include pyelonephritis, diuresis, congenital malformation or ureteral or lower urinary tract obstruction.
- Mild prostatomegaly as described above
- Urinary bladder debris

INTERPRETATION OF THE FINDINGS & FURTHER RECOMMENDATIONS

The findings described above are mild and likely primarily age related. The pyelectasia is likely secondary to PU/PD from early or emerging kidney disease. However, given the concurrent urinary bladder debris, pyelonephritis can't be ruled out. Recommendations include a urine culture to rule out an occult urinary tract

infection. Additionally, testing for Leptospirosis is recommended. A blood pressure is recommended if not recently evaluated. Following that, and pending results, empirical antibiotics could be tried, as sometimes pyelonephritis does not result in a positive culture when urine is obtained from the urinary bladder. Beyond that, if tolerated, transition to a kidney friendly diet could be considered, followed ultimately by monitoring for progression and management of changes if/when/and as they occur.





The information and recommendations provided are based on the images presented by the referring veterinarian/sonographer. No evaluation can be communicated regarding pathology that was not visible in the image/video clips provided.

Thank you for this referral. If the clinical or image interpretation does not parallel your findings or if I can be of any further assistance please contact me.

Beth Johnson, DVM, DACVIM
Beth.Johnson@sonopath.com