

**DATE PRESENTING CLINICAL SIGNS**

3/6/23

PATIENT

Nahla Lowery

SPECIES

Canine

BREED

Puggle

SEX

Spayed Female

AGE

12/23/12

WEIGHT

20.2 Pounds

INTERPRETED BYBeth Johnson, DVM
DACVIM**HOSPITAL NAME**Animal Emergency
Hospital**REFERRING VET**

Dr. Martinoli

INVOICE

21489

History: Referred for continued care for suspected pyelonephritis. Saw rDVM this morning for Vomiting and diarrhea, not eating, for 1 day. Temp was 104.4, bloodwork showed 27K WBC, clumped platelets, tBili 1.7, BUN 42, Creat 2.6. Hematuria also present. ATO Nahla has drank large amount for as long as she can remember. Has been on RC SO diet with K+ Citrate (1 scoop BID) due to her history of bladder stones; has had 2 cystotomies. Last one was Jan. 2022; had bloodwork before that procedure and owner believes it was normal at that time. Owner also thinks she had an abdominal ultrasound last year. Unsure of Lepto vaccine status. (Told her we can call for records on Monday morning.)

Current Medications: Buprenorphine, Cerenia, Ondansetron, Baytril, Unasyn.

Lab Results: Normal BP, fair urine output, worsening azotemia in spite of IV fluid diuresis. urine culture pending.

Date of Previous IntraPet Ultrasound: No previous.

Sedation: Not required to complete full diagnostic ultrasound.

Stat Report: Not requested.

Imaging Performed By: Andi Parkinson, BS, RDMS.

ULTRASONOGRAPHIC EXAMINATION OF THE ABDOMEN**Urinary System**

Urinary bladder is only mildly distended (empty). Visible contents are anechoic. Urinary bladder wall is unable to be fully assessed for pathology without further distension. No visible masses or cystoliths are observed. The trigone and visible pelvic urethra are normal thickness with a smooth mucosal surface. If there are urinary signs and/or concern for urinary bladder pathology, reassessment after complete filling is recommended. A foley urinary catheter is in place.

The kidneys are bilaterally uniformly enlarged/swollen (the left kidney measures 5.19 cm, the right kidney measures 6.65 cm) with an overall hyperechoic echogenicity and slight loss of corticomedullary definition. Normal smooth peripheral margination is maintained. The left renal pelvis is mildly dilated with anechoic fluid and hyperechoic thickened pelvic fat. The right kidney is markedly dilated with anechoic fluid and hyperechoic thickened pelvic fat, measuring 2.0 cm in the transverse view. Additionally, the right ureter is dilated to the level of a visible obstructive ureterolith, measuring 0.38 cm in size. No overt neoplasia is observed. The perinephric area is enhanced by hyperechoic fat and mesentery. Small nonobstructive nephroliths are noted in the left kidney.

Adrenal Glands

Left adrenal gland is normal in size (1.84 cm long x 0.67 cm at caudal pole, the cranial pole is unable to be fully visualized), shape and overall architecture, echogenicity and echotexture. Visible surrounding vasculature appears normal.

Right adrenal gland is normal in size (2.02 cm long x 0.6 cm at cranial pole and 0.73 cm at caudal pole), shape and overall architecture, echogenicity and echotexture. Visible surrounding vasculature appears normal.

Spleen

Spleen is subjectively normal in size with a normal smooth capsular contour. Parenchyma is appropriately finely textured and homogenous with normal echogenicity relative to surrounding tissue (hyperechoic to liver). No focal nodules or masses are observed. Splenic vasculature appears normal.

Liver

Liver is subjectively normal in size with normal smooth curvilinear peripheral contour. Parenchyma is appropriately hypoechoic to the spleen in echogenicity and appropriately mildly coarse and homogenous in echotexture. No focal lesions are observed. Visible vasculature and biliary tree appear normal without distension or congestion.

Gallbladder is moderately distended with anechoic bile as well as mild suspended and gravity dependent echogenic debris. The wall is smooth without visible thickening. There is no evidence of cystic or CBD dilation. There is no evidence of effusion or inflammation.

Gastrointestinal

The visible stomach wall is normal in thickness and layering. The lumen of the stomach is markedly fluid distended. There is no evidence of obstruction, foreign material or infiltrative disease. The pyloric outflow tract appears patent.

The visible small intestines are normal in wall thickness and layering. Small intestinal motility appears adequate (1-3 contractions per min). The lumen of the small intestine is empty with no evidence of obstruction, foreign material or infiltrative disease.

The visible colon is normal in wall thickness and layering. Contents are consistent with normal formed feces and gas.

Pancreas

The observed pancreas is prominent (enlarged) in size, hypoechoic to surrounding tissue and irregular in shape with a swollen undulating contour. Enhanced hyperechoic ill-defined surrounding fat is noted.

Free Abdomen

There is no apparent lymphadenopathy. A scant amount of perinephric free fluid, as well as enhanced hyperechoic mesenteric fat surrounding both kidneys and the pancreas.

ULTRASONOGRAPHIC FINDINGS

Primary Findings

- Pyelonephritis is suspected in combination with, or potentially as the result of an obstructive distal right ureterolith contributing to the marked pyelectasia/early hydronephrosis in the right kidney.
- Concurrent acute pancreatitis is suspected, potentially contributing to gastric stasis or delayed gastric outflow

Secondary Findings

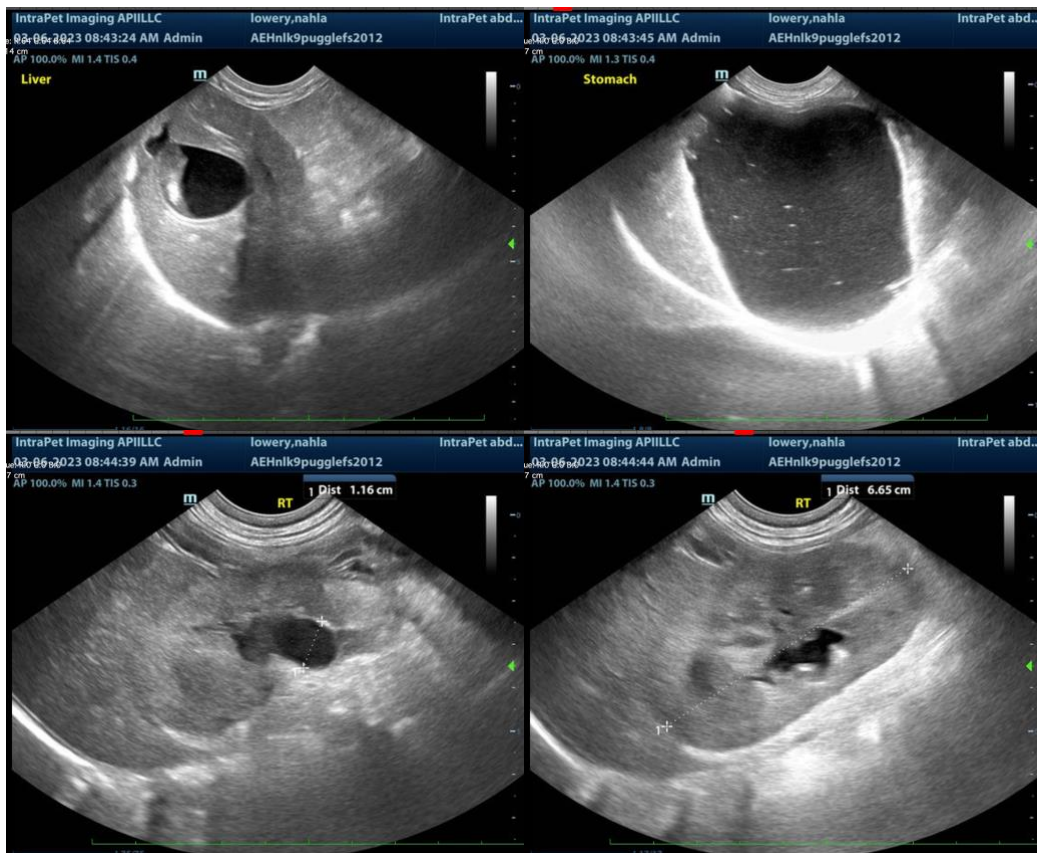
- Mild gallbladder debris - Cholecystic debris is of unknown clinical significance. It can be seen with biliary stasis from fasting or illness. Cholecystic debris is not necessarily related to hepatobiliary disease. Echogenic bile is most commonly an incidental finding in dogs and should be interpreted in combination with clinical signs such as nausea, inappetence, cranial abdominal discomfort and/or laboratory changes such as increased ALP and/or increased Tbili.

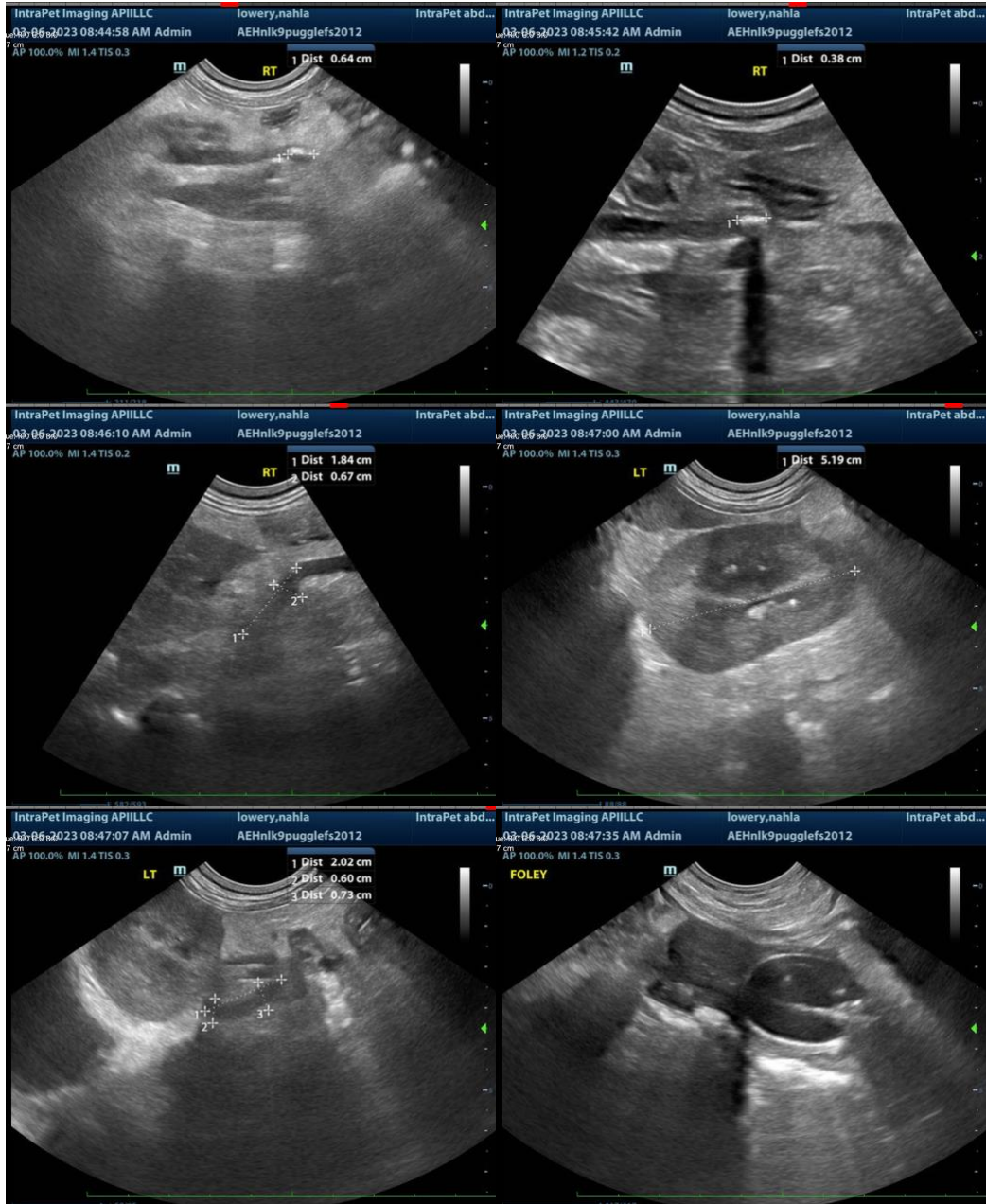
INTERPRETATION OF THE FINDINGS & FURTHER RECOMMENDATIONS

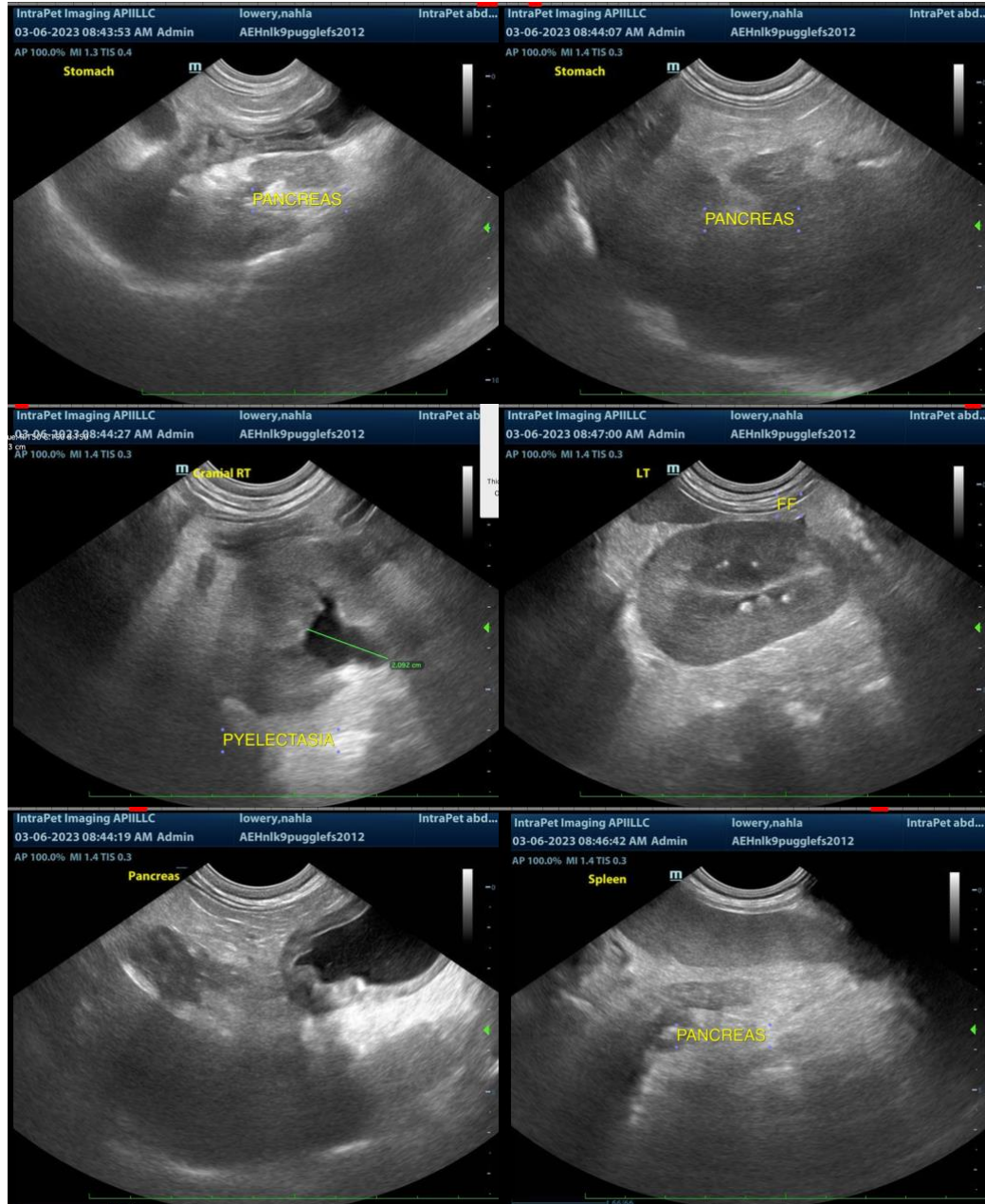
As is reportedly already pending, a urine culture is recommended. If not recently evaluated, testing for Leptospirosis is recommended, as is a quantitative PLI.

In the meantime, continued supportive/symptomatic medical management of suspected pyelonephritis, as well as pancreatitis, is recommended in the form of antiemetics, gastroprotectants, appetite stimulants or nutritional support (as needed), pain management, broad spectrum antibiotics and fluid therapy.

This patient's azotemia is reportedly progressing despite fluid therapy, so being sure to rule out inadequate fluid support (given polyuria), as opposed to true progression of azotemia, is recommended, and this can be accomplished by monitoring patient weights. If patient is gaining weight, then adequate fluid amount is likely present, however, if patient is losing weight, the progression and azotemia may be inadequate fluid support to keep up with polyuria (if polyuria is present). If the fluid therapy is determined to be adequate, then progression of the azotemia is likely secondary to the obstructive urolith, in which case more aggressive intervention may ultimately be required, up to and including surgical intervention, placement of a SUB, etc.







The information and recommendations provided are based on the images presented by the referring veterinarian. No evaluation can be communicated regarding pathology that was not visible in the image/video clips provided.

Thank you for this referral. If the clinical or image interpretation does not parallel your findings or if I can be of any further assistance please contact me.

Beth Johnson, DVM DACVIM

Beth.Johnson@SonoPath.com