

**DATE PRESENTING CLINICAL SIGNS**

3/6/23

**PATIENT**

Mookie Morton

History: P diagnosed with GI lymphoma in August 2022 at specialty hospital and currently in remission? Is also a long-term diabetic currently well regulated. P presented on 3/3/23 for hyporexia, lethargy, and constipation. P received an enema and supportive care for constipation. O called on 03/06/2023 with update - no bowel movement since enema and still ADR and hyporexic. Recheck US recommended to assess GI lymphoma.

**SPECIES**

Feline

Current Medications: 5mg Fluoxetine SID (since August 2022 - possible cause of hyporexia? Decreased to EOD starting on 03/03/23), 2u Lantus insulin BID, Convenia injection give on 02/24/2023 for small tail wound

**BREED**

DSH

Lab Results: 03/03/2023 unremarkable

Date of Previous IntraPet Ultrasound: No previous.

Sedation: Not required to complete full diagnostic ultrasound.  
Stat Report: Not requested.

**SEX**

Spayed Female

Imaging Performed By: Stephanie Warga RDCS, RVT.

**ULTRASONOGRAPHIC EXAMINATION OF THE ABDOMEN****AGE**

4/7/07

**Urinary System**

Urinary bladder is adequately distended. It has a normal uniform wall thickness. Contents include primarily anechoic fluid with a very large amount of echogenic non-shadowing debris, which could be in part incidental suspended lipid in a cat, but likely combined with exfoliated cells, mucus and/or small blood clots, etc.

**WEIGHT**

10.95 Pounds

Both sterile inflammation as well as urinary tract infection can also present with echogenic debris. No masses or cystoliths are observed. The trigone and visible pelvic urethra are normal in thickness with a smooth mucosal surface.

**INTERPRETED BY**Eric Lindquist, DMV  
DABVP, Cert. IVUSS

Kidneys are significantly enlarged in size with increased cortical echogenicity and disruption of normal corticomedullary architecture caused by multifocal heterogenous (primarily hypoechoic) nodules. A hypoechoic subcapsular rim "halo" is present. The pericapsular area is enhanced by hyperechoic fat and mesentery. No mineral is observed. This change is more appreciated in the right kidney than the left. The right kidney measures 5.0 cm. The left kidney measures 4.38 cm. Mild bilateral pyelectasia is noted, measuring 0.22 cm in the transverse view of the left kidney, and 0.25 cm in the transverse view of the right kidney.

**HOSPITAL NAME**

Everhart VH

**Adrenal Glands**

Left adrenal gland is normal in size (0.39 cm), shape and overall architecture, echogenicity and echotexture. Visible surrounding vasculature appears normal.

**REFERRING VET**

Dr. Notarangelo

Right adrenal gland is normal in size (0.42 cm), shape and overall architecture, echogenicity and echotexture. Visible surrounding vasculature appears normal.

**INVOICE**

21500

**Spleen**

Spleen is subjectively normal in size with a normal smooth capsular contour. Parenchyma is appropriately finely textured and homogenous with normal echogenicity relative to surrounding tissue (hyperechoic to liver). No focal nodules or masses are observed. Splenic vasculature appears normal.

**Liver**

Liver is subjectively normal in size with normal smooth curvilinear peripheral contour. Parenchyma is appropriately hypoechoic to the spleen in echogenicity and appropriately mildly coarse and homogenous in echotexture. No focal lesions are observed. Visible vasculature and biliary tree appear normal without distension or congestion.

Gallbladder is non-distended in size. The wall is smooth without visible thickening. Luminal contents are primarily anechoic. There is no evidence of cystic or common bile duct dilation.

### ***Gastrointestinal***

The visible stomach wall is normal in thickness and layering. The lumen of the stomach is empty with no evidence of obstruction, foreign material or infiltrative disease. Pyloric outflow tract appears patent.

The visible small intestine demonstrates areas of thick muscularis layer relative to mucosa (disruption of the normal 1:3 muscularis:mucosa ratio). Small intestinal submucosa is slightly irregular, thick and hyperechoic, without evident loss of layering appreciated. The lumen of the small intestine is empty with no evidence of obstruction or foreign material.

The visible colon is normal in wall thickness and layering. Contents are consistent with normal formed feces and gas. At the level of the ileocecolic junction, a hypoechoic vascular intramural mass is present, measuring 1.1 cm in diameter.

### ***Pancreas***

The observed pancreas appears appropriately isoechoic to surrounding omental fat. The capsule is mildly irregular in shape. Parenchyma is mildly heterogenous and coarse. There is no visible pancreatic duct dilation. There is no evidence of active peripancreatic inflammation.

### ***Free Abdomen***

There is no evidence of peritoneal effusion. There is no apparent lymphadenopathy.

## **ULTRASONOGRAPHIC FINDINGS**

- Gastrointestinal lymphoma (suspect) pattern – Thick muscularis has been reported with infiltrative bowel disease including both benign inflammatory disease as well as infiltrative neoplasia such as lymphoma. Given this patient's history, combined with the concurrent pathology noted, infiltrative neoplasia is considered more likely.
- The intramural mass at the ileocecolic junction is most concerning for lymphoma, given this patient's history. Other neoplasia, adenocarcinoma, etc., can't be ruled out without tissue sampling. A benign process is considered much less likely.
- Renal lymphoma – This appearance is highly suggestive of renal lymphoma. Other malignant neoplasia, severe nephritis and feline infectious peritonitis can at times mimic this presentation, but it's less common.
- Pancreatic age-related remodeling – Mild irregularities are consistent with benign age-related change. Low-grade smoldering chronic pancreatitis cannot be ruled out and should be suspected in the face of appropriate clinical signs.
- Large amount of urinary bladder debris

## **INTERPRETATION OF THE FINDINGS & FURTHER RECOMMENDATIONS**

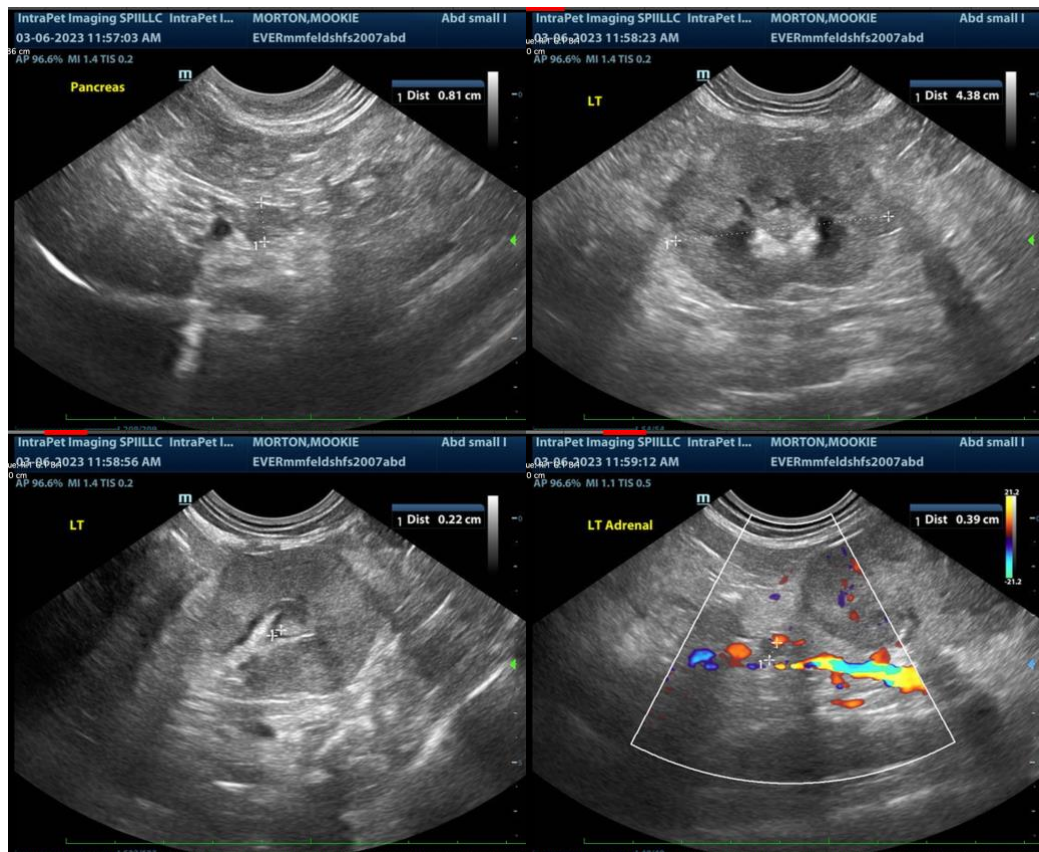
If possible, fine needle aspirate of the ileocecolic mass, as well as fine needle aspirates of the kidneys,

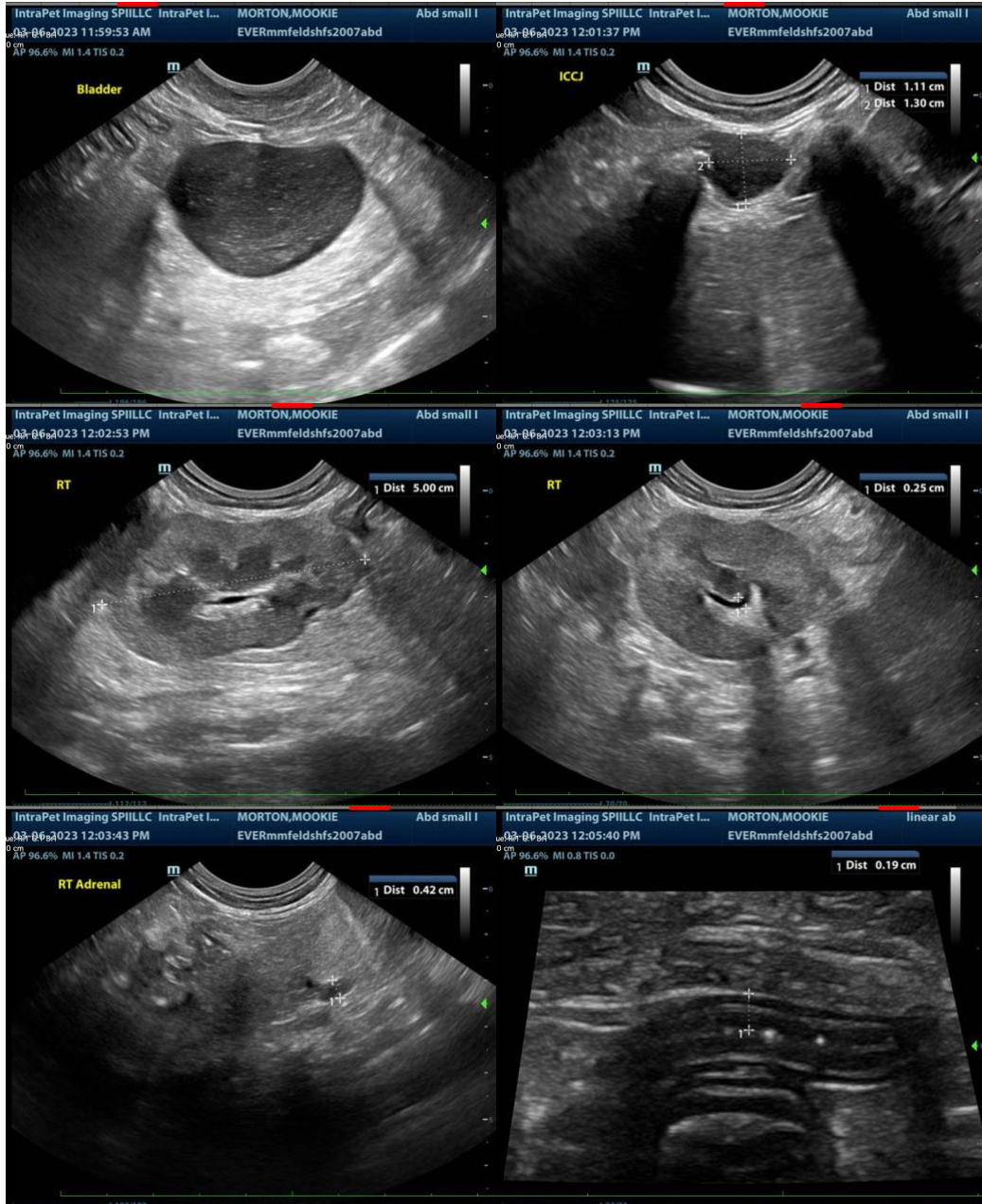
could be considered, if patients coagulation status is appropriate.

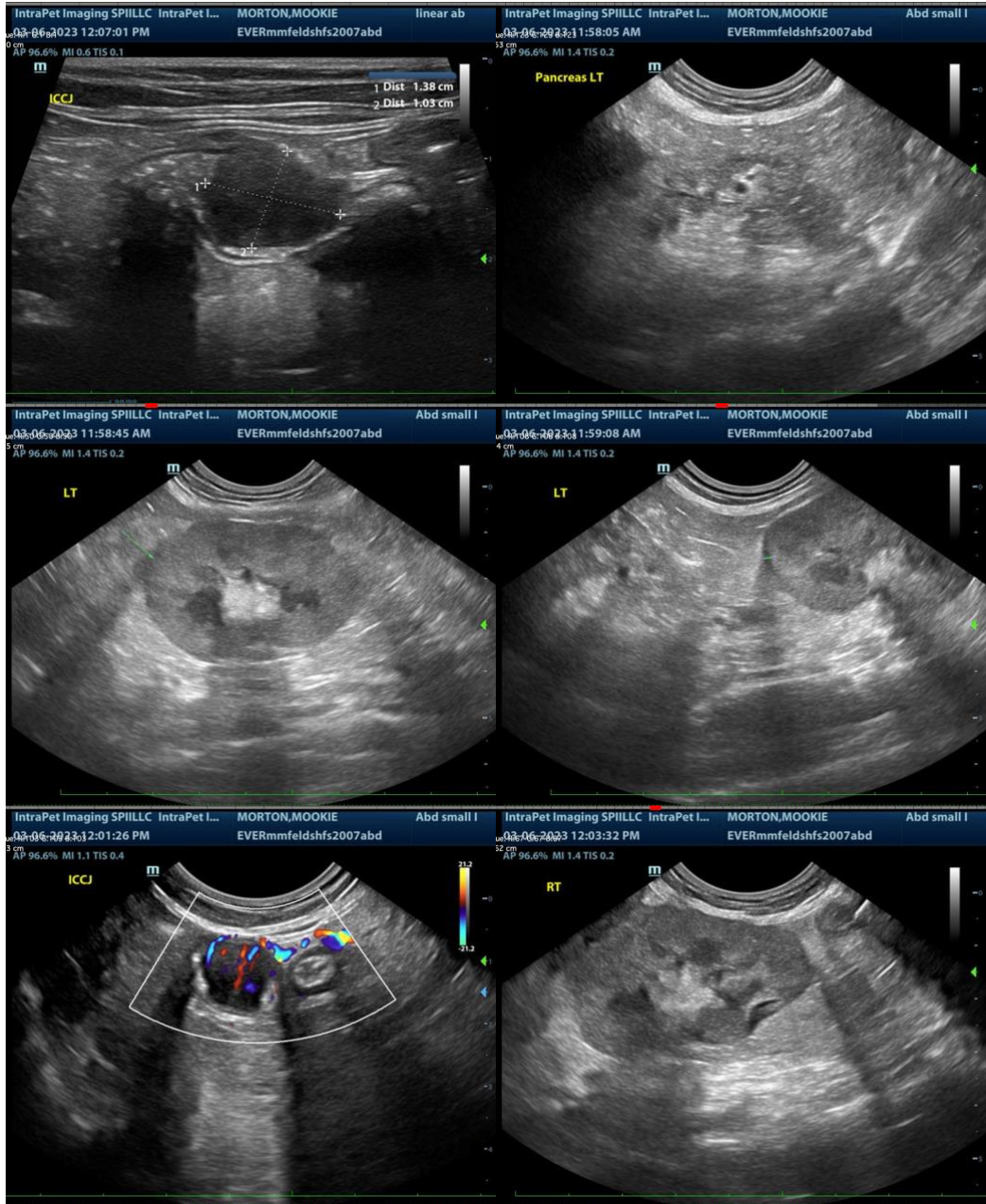
Additionally, urinalysis and, if indicated based on urinalysis results, urine culture is recommended. If protein is present in an otherwise quiet sediment, protein quantification with a urine protein to creatinine ration is recommended.

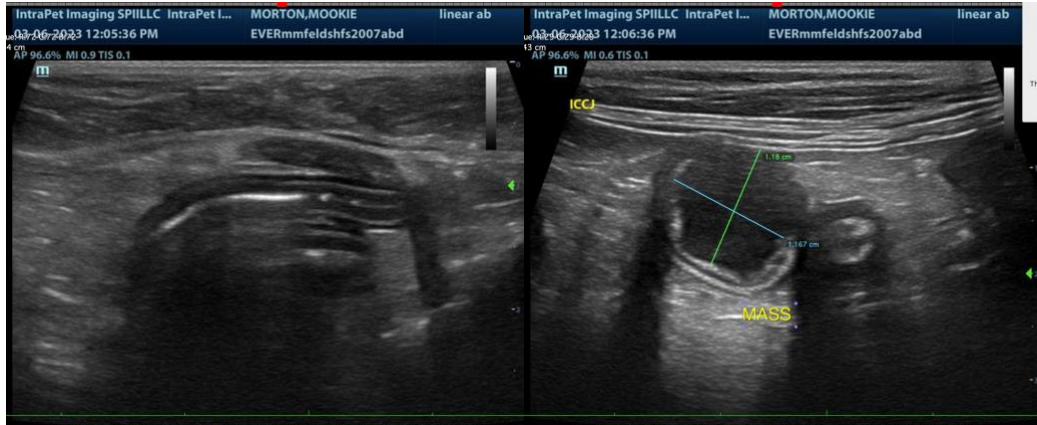
Additionally, a gastrointestinal malabsorption panel (including cobalamin, folate, TLI and PLI) to Texas A&M GI Laboratory is recommended for further evaluation of GI and pancreatic function.

If, however, given this patients previous diagnosis, a more conservative approach is elected, the previous treatment protocol for the gastrointestinal lymphoma, that reportedly went into remission, could be restarted empirically, if further diagnostics are not an option and/or are declined.









**The information and recommendations provided are based on the images presented by the referring veterinarian. No evaluation can be communicated regarding pathology that was not visible in the image/video clips provided.**

Thank you for this referral. If the clinical or image interpretation does not parallel your findings or if I can be of any further assistance please contact me.

**Beth Johnson, DVM DACVIM**  
Beth.Johnson@SonoPath.com