



PATIENT

Daisy Bullins

SPECIES

Canine

BREED

Dachshund

SEX

Spayed Female

AGE

14 Years 9 Months

WEIGHT

11.4 lbs

INTERPRETED BY

Beth Johnson, DVM
 DACVIM

IMAGING PERFORMED BY

Kathleen Byrnes

HOSPITAL NAME

Animal Clinic Madison
 Mayodan

REFERRING VET

Dr. McKinlay

INVOICE

73427

DATE

3/5/26

PRESENTING CLINICAL SIGNS

P initially presented in February for a fever, elevated ALT and dark tarry stools. . Treated with Clavamox. Recheck ALT was normal. Dark tarry stools persist. rDVM rec US to evaluate

ULTRASONOGRAPHIC EXAMINATION OF THE ABDOMEN

Urinary System

The urinary bladder is adequately distended with anechoic contents. No masses, inflammatory changes, echogenic sediment or cystoliths are observed. The urinary bladder, trigone and visible pelvic urethra are normal in thickness with a smooth mucosal surface.

Kidneys are overall normal in size and shape with smooth peripheral margination. A normal 1:3 cortex to medulla ratio is maintained. The medulla and cortices are uniform in texture with some mild increased cortical echogenicity and mild loss of corticomedullary distinction, expected in this age patient. There is no evidence of pyelectasia, mineral or infarcts observed. Left kidney measured 3.57 cm. Right kidney measured 3.7 cm.

Adrenal Glands

The right adrenal gland is normal in size (0.45 cm at cranial pole and 0.58 cm at caudal pole), shape and overall architecture, echogenicity and echotexture. Visible surrounding vasculature appears normal.

The left adrenal gland is normal in size (0.57 cm at cranial pole and 0.56 cm at caudal pole), shape and overall architecture, echogenicity and echotexture. Visible surrounding vasculature appears normal.

Spleen

The spleen is subjectively normal in size with a normal smooth capsular contour. Parenchyma is appropriately finely textured and homogenous with normal echogenicity relative to surrounding tissue (hyperechoic to liver). No focal nodules or masses are observed. Splenic vasculature appears normal.

Liver

The liver is subjectively normal in size with normal smooth curvilinear peripheral contour. Parenchyma is appropriately hypoechoic to the spleen in echogenicity and appropriately mildly coarse and homogenous in echotexture. No focal lesions are observed. Visible vasculature and biliary tree appear normal without distension or congestion.

The gallbladder is non-distended in size. The wall is smooth without visible thickening. Luminal contents are primarily anechoic. There is no evidence of cystic or common bile duct dilation.

Gastrointestinal

The visible stomach wall is normal in thickness and layering, except for some very subjective mildly thick areas within the pylorus measuring between 0.44 cm and 0.79 cm thick. There is no loss of layering noted. The lumen of the stomach is empty with no evidence of obstruction, foreign material or infiltrative disease. Pyloric outflow tract appears patent.

The visible small intestine demonstrates areas of mildly thick muscularis layer relative to mucosa (disruption of the normal 1:3 muscularis:mucosa ratio). Small intestinal submucosa is slightly irregular, thick and hyperechoic, without evident loss of layering appreciated. The lumen of the small intestine is empty with no evidence of obstruction or foreign material.



PATIENT

Daisy Bullins

SPECIES

Canine

BREED

Dachshund

SEX

Spayed Female

AGE

14 Years 9 Months

WEIGHT

11.4 lbs

INTERPRETED BY

Beth Johnson, DVM
DACVIM

IMAGING PERFORMED BY

Kathleen Byrnes

HOSPITAL NAME

Animal Clinic Madison
Mayodan

REFERRING VET

Dr. McKinlay

INVOICE

73427

DATE

3/5/26

The visible colon is normal in wall thickness (< 0.2 cm) and layering. Contents are consistent with normal formed feces and gas.

Pancreas

The pancreas that is observed appears appropriately isoechoic to surrounding omental fat. Visible capsule is smooth and normal in contour. Visible pancreatic parenchyma is homogenous and unremarkable. There is no visible pancreatic duct dilation. There is no evidence of active peripancreatic inflammation.

Free Abdomen

There is no visible free peritoneal effusion noted in these images.

There is no apparent pathologic lymphadenopathy noted in these images.

PRIMARY FINDINGS

- Mild/emerging inflammatory bowel disease (IBD) pattern – Thick muscularis has been reported with infiltrative bowel disease including both benign inflammatory disease as well as infiltrative neoplasia such as lymphoma. No loss of layering or distinct characteristics of malignancy are present. Therefore, differentials cannot be further ranked without tissue sampling.
- The same process affecting the pylorus is possible.

SECONDARY FINDINGS

- Age related kidney changes.

INTERPRETATION OF THE FINDINGS & FURTHER RECOMMENDATIONS

If not recently evaluated, a general metabolic health screen (CBC, chemistry panel with electrolytes and urinalysis) is recommended.

Assessment of patient's coagulation status is also recommended. A routine fecal/giardia exam is recommended if not recently evaluated.

A gastrointestinal malabsorption panel (including cobalamin, folate, TLI and PLI) to Texas A&M GI Laboratory is recommended for further evaluation of GI and pancreatic function.

A baseline cortisol is recommended. If baseline cortisol is less than 2, a full ACTH stimulation test is recommended to rule out hypoadrenocorticism.

If a diagnosis is not obtained, a fecal enteropathogen PCR panel to Texas A&M GI Laboratory could be considered for further evaluation of possible infectious disease. Contact lab for recommendations on how long to discontinue antibiotics (if indicated) prior to obtaining a stool sample for submission.

Other than supportive/symptomatic medical management of clinical signs, further treatment recommendations are largely dependent on results of the above.

Ultimately, if a diagnosis is not made and clinical signs persist, upper GI gastroscopy/endoscopy for further visual evaluation of the stomach/pylorus and proximal small bowel as well as biopsies may be necessary for definitive diagnosis and therefore to further guide medical management.



PATIENT

Daisy Bullins

SPECIES

Canine

BREED

Dachshund

SEX

Spayed Female

AGE

14 Years 9 Months

WEIGHT

11.4 lbs

INTERPRETED BY

Beth Johnson, DVM
 DACVIM

IMAGING PERFORMED BY

Kathleen Byrnes

HOSPITAL NAME

Animal Clinic Madison
 Mayodan

REFERRING VET

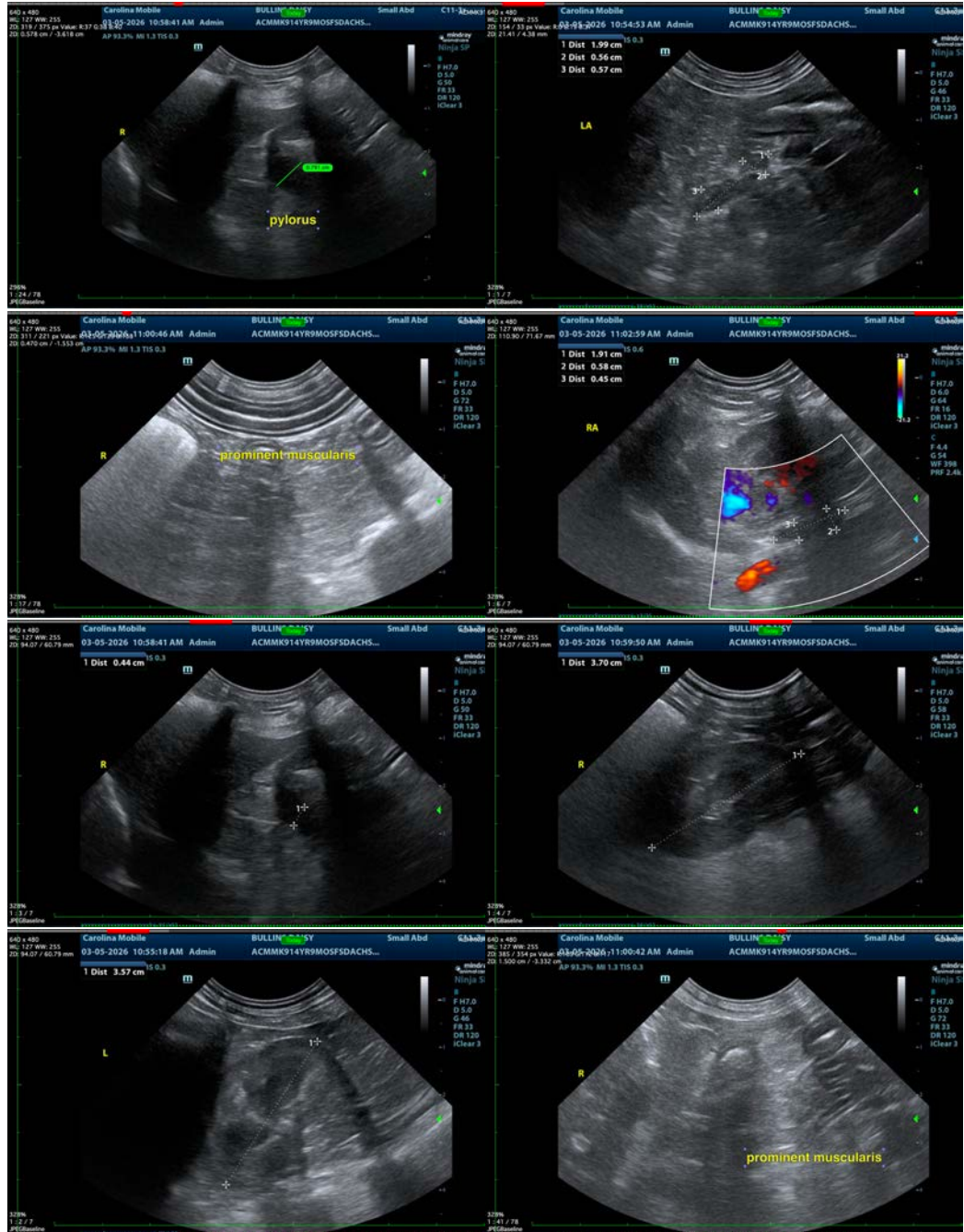
Dr. McKinlay

INVOICE

73427

DATE

3/5/26





PATIENT

Daisy Bullins

SPECIES

Canine

BREED

Dachshund

SEX

Spayed Female

AGE

14 Years 9 Months

WEIGHT

11.4 lbs

INTERPRETED BY

Beth Johnson, DVM
DACVIM

**IMAGING
PERFORMED BY**

Kathleen Byrnes

HOSPITAL NAME

Animal Clinic Madison
Mayodan

REFERRING VET

Dr. McKinlay

INVOICE

73427

DATE

3/5/26

The information and recommendations provided are based on the images presented by the referring veterinarian/sonographer. No evaluation can be communicated regarding pathology that was not visible in the image/video clips provided.

Thank you for this referral. If the clinical or image interpretation does not parallel your findings or if I can be of any further assistance please contact me.

Beth Johnson, DVM, DACVIM
info@sonopath.com