

PATIENT

Ocean Tanionos

SPECIES

Canine

BREED

Labrador Retriever x

SEX

Neutered Male

AGE

9 Years

WEIGHT

37.2 lbs

INTERPRETED BY

Beth Johnson, DVM
DACVIM

IMAGING PERFORMED BY

Pamela Harrigan,
RDCS, Certified Vet
Sonographer

HOSPITAL NAME

Falmouth Animal
Hospital

REFERRING VET

Alyssa Sakmar, DVM

INVOICE

73412

DATE

3/4/26

PRESENTING CLINICAL SIGNS

Recheck AUS. History benign hepatopathy, history benign splenic myelolipomas on prior AUS (1/8/25 Beth Johnson, DVM, DACVIM, SonoPath). Presently Ocean has no clinical signs, but does have persistent increasing hepatic enzymes despite Denamarin. ALT 406, AST 76.

ULTRASONOGRAPHIC EXAMINATION OF THE ABDOMEN

Urinary System

The urinary bladder is adequately distended with anechoic contents. No masses, inflammatory changes, echogenic sediment or cystoliths are observed. The urinary bladder, trigone and visible pelvic urethra are normal in thickness with a smooth mucosal surface.

Prostate is normal in size, echotexture and echogenicity for a neutered male.

The right kidney is normal in size (4.4 cm), shape and echogenicity. It has smooth peripheral margination. There is a normal 1:3 cortex to medulla ratio with appropriate corticomedullary distinction. There is no evidence of pyelectasia, mineral or infarcts observed.

The left kidney is normal in size (4.96 cm), shape and echogenicity. It has smooth peripheral margination. There is a normal 1:3 cortex to medulla ratio with appropriate corticomedullary distinction. There is no evidence of pyelectasia, mineral or infarcts observed.

Adrenal Glands

The right adrenal gland is normal in size (0.48 cm at cranial pole and 0.37 cm at caudal pole), shape and overall architecture, echogenicity and echotexture. Visible surrounding vasculature appears normal.

The left adrenal gland is normal in size (0.42 cm at cranial pole and 0.47 cm at caudal pole), shape and overall architecture, echogenicity and echotexture. Visible surrounding vasculature appears normal.

Spleen

Spleen is subjectively normal in size with a normal smooth capsular contour. Parenchyma is appropriately finely textured and homogenous with normal echogenicity relative to surrounding tissue (hyperechoic to liver). Multifocal well-demarcated hyperechoic homogenous nodules are noted. Splenic vasculature appears normal.

Liver

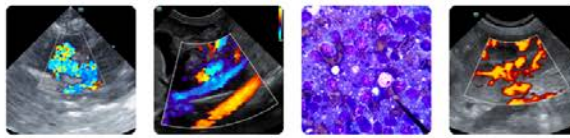
Liver is subjectively enlarged with mildly irregular margins. Parenchyma is mildly heterogeneous characterized by multiple poorly defined hypoechoic nodules within otherwise hyperechoic liver parenchyma. Visible vasculature and biliary tree appear normal without distension or congestion

The gallbladder is non-distended in size. The wall is smooth without visible thickening. Luminal contents are primarily anechoic. There is no evidence of cystic or common bile duct dilation.

Gastrointestinal

The visible stomach wall is normal in thickness and layering. The lumen of the stomach is empty with no evidence of obstruction, foreign material or infiltrative disease. Pyloric outflow tract appears patent.

The visible small intestine demonstrates areas of moderately thick muscularis layer relative to mucosa (disruption of the normal 1:3 muscularis:mucosa ratio). Small intestinal submucosa is slightly irregular,



PATIENT

Ocean Tanionos

SPECIES

Canine

BREED

Labrador Retriever x

SEX

Neutered Male

AGE

9 Years

WEIGHT

37.2 lbs

INTERPRETED BY

Beth Johnson, DVM
DACVIM

**IMAGING
PERFORMED BY**

Pamela Harrigan,
RDCS, Certified Vet
Sonographer

HOSPITAL NAME

Falmouth Animal
Hospital

REFERRING VET

Alyssa Sakmar, DVM

INVOICE

73412

DATE

3/4/26

thick and hyperechoic, without evident loss of layering appreciated. The lumen of the small intestine is empty with no evidence of obstruction or foreign material.

The visible colon is normal in wall thickness (< 0.2 cm) and layering. Contents are consistent with normal formed feces and gas.

Pancreas

The observed pancreas appears appropriately isoechoic to surrounding omental fat. The capsule is mildly irregular in shape. Parenchyma is mildly heterogenous and coarse. There is no visible pancreatic duct dilation. There is no evidence of active peripancreatic inflammation.

Free Abdomen

There is no visible free peritoneal effusion noted in these images.

Medial iliac lymph nodes are prominent in size with swollen capsular contour. Normal elongated shape (length to width ratio) is maintained. There is no loss of parenchymal detail.

PRIMARY FINDINGS

- Mild to moderate inflammatory bowel disease (IBD) pattern – Thick muscularis has been reported with infiltrative bowel disease including both benign inflammatory disease as well as infiltrative neoplasia such as lymphoma. No loss of layering or distinct characteristics of malignancy are present. Therefore, differentials cannot be further ranked without tissue sampling.
- Pancreatic age-related remodeling/Chronic pancreatitis – Mild irregularities are consistent with benign age-related change. Low-grade smoldering chronic pancreatitis cannot be ruled out and should be suspected in the face of appropriate clinical signs.
- Reactive medial iliac lymph nodes – infiltrative neoplastic disease cannot be ruled out but is considered less likely.
- Otherwise, an obvious cause for the subtle liver changes is not identified in these images. Microscopic disease such as Leptospirosis, bacterial cholangiohepatitis, chronic active hepatitis, copper-associated hepatotoxicity, other hepatotoxicity, other reactive hepatopathy, infiltrative neoplasia (considered unlikely), etc. cannot be definitively ruled out.

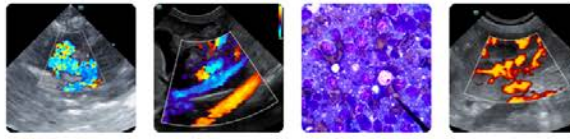
SECONDARY FINDINGS

- Hyperechoic splenic nodules – most consistent with benign myelolipomas. Other differentials such as fibrosis or calcification caused by old hematomas or infarcts, chronic inflammation, granulomatous disease or metastatic disease cannot be ruled out, but are considered less likely.

INTERPRETATION OF THE FINDINGS & FURTHER RECOMMENDATIONS

The liver changes in this study are static/unchanged from the previous exam. Recommendations are similarly unchanged and dependent on what has previously been done, those results, etc.

What is new in this study are the mild to moderate bowel changes described above, which should be interpreted in combination with clinical history of gastrointestinal signs, including potentially unintentional weight loss. This finding is of unknown if any relation to the ALT but could warrant further



PATIENT

Ocean Tanionos

SPECIES

Canine

BREED

Labrador Retriever x

SEX

Neutered Male

AGE

9 Years

WEIGHT

37.2 lbs

INTERPRETED BY

Beth Johnson, DVM
DACVIM

IMAGING PERFORMED BY

Pamela Harrigan,
RDCS, Certified Vet
Sonographer

HOSPITAL NAME

Falmouth Animal
Hospital

REFERRING VET

Alyssa Sakmar, DVM

INVOICE

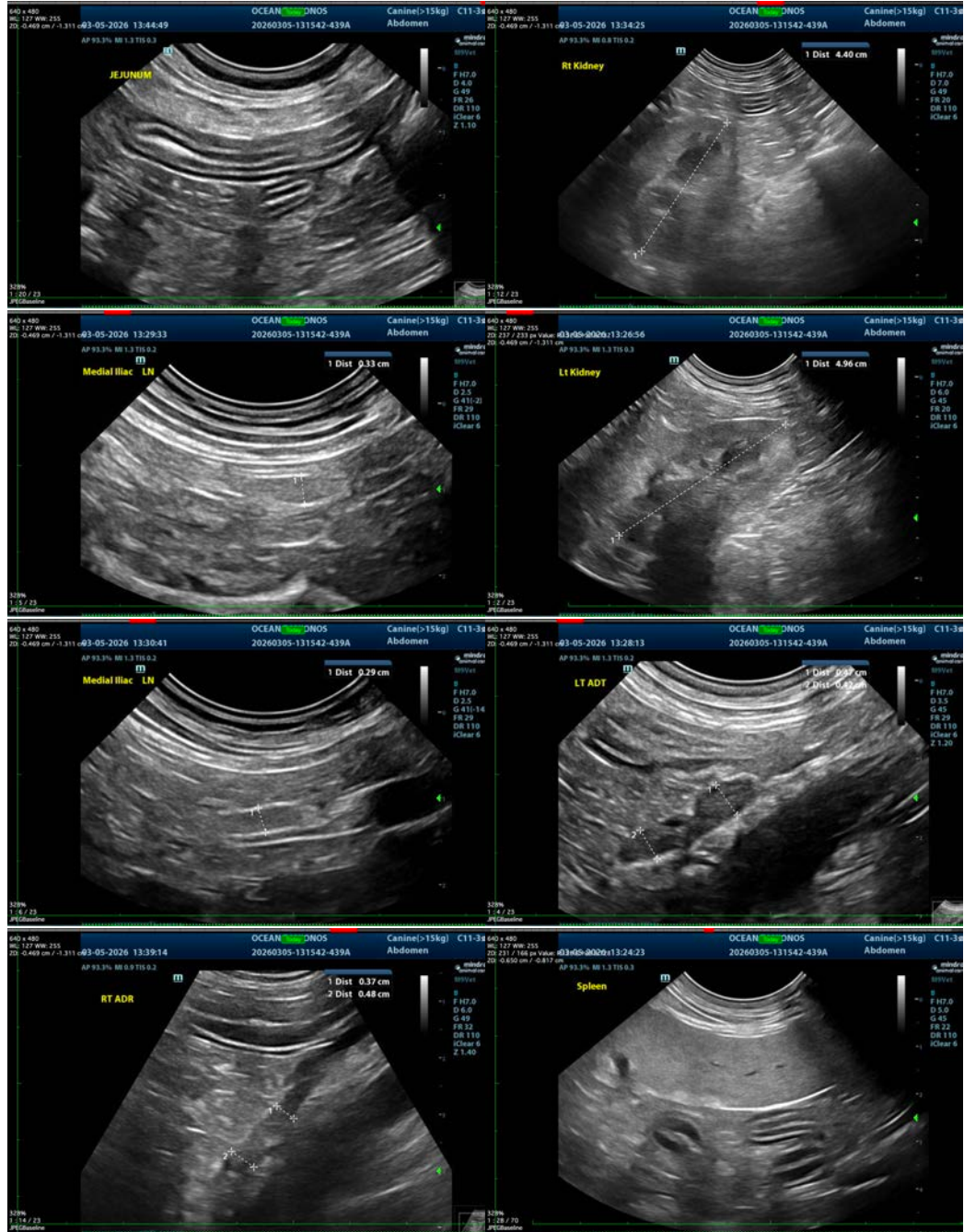
73412

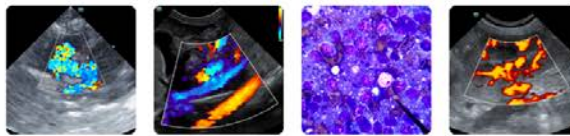
DATE

3/4/26

investigation, beginning with a routine/giardia exam if not recently evaluated.

A gastrointestinal malabsorption panel (including cobalamin, folate, TLI and PLI) to Texas A&M GI Laboratory is recommended for further evaluation of GI and pancreatic function.





PATIENT

Ocean Tanionos

SPECIES

Canine

BREED

Labrador Retriever x

SEX

Neutered Male

AGE

9 Years

WEIGHT

37.2 lbs

INTERPRETED BY

Beth Johnson, DVM
DACVIM

IMAGING PERFORMED BY

Pamela Harrigan,
RDCS, Certified Vet
Sonographer

HOSPITAL NAME

Falmouth Animal
Hospital

REFERRING VET

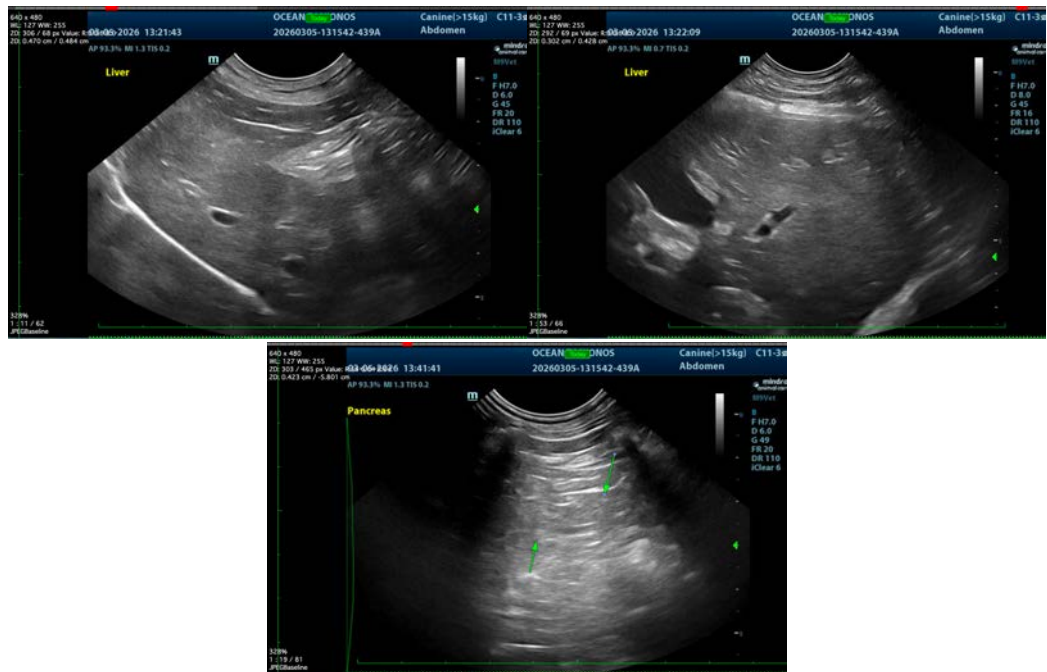Alyssa Sakmar, DVM

INVOICE

73412

DATE

3/4/26



The information and recommendations provided are based on the images presented by the referring veterinarian/sonographer. No evaluation can be communicated regarding pathology that was not visible in the image/video clips provided.

Thank you for this referral. If the clinical or image interpretation does not parallel your findings or if I can be of any further assistance please contact me.

Beth Johnson, DVM, DACVIM
info@sonopath.com