



PATIENT

Mincha George

SPECIES

Feline

BREED

Bengal

SEX

Spayed Female

AGE

5 Years

WEIGHT

9 lbs

INTERPRETED BY

Beth Johnson, DVM
DACVIM

IMAGING PERFORMED BY

Julia Bakker, DVM

HOSPITAL NAME

Orange Blossom
Veterinary Imaging

REFERRING VET

Richard Hall, DVM

INVOICE

73380

DATE

3/4/26

PRESENTING CLINICAL SIGNS

Repetitive history of inappropriate urination on counter - free catch urinalysis at these times suspicious of UTI with wbc, rbc, and bacteria present. AUS today to screen urinary system and collect US guided cysto. Recent cbc/chem within normal limits, no azotemia present.

ULTRASONOGRAPHIC EXAMINATION OF THE ABDOMEN

Urinary System

Urinary bladder is adequately distended. It has a normal uniform wall thickness. Contents include primarily anechoic fluid with occasional echogenic non-shadowing debris, most consistent with incidental suspended lipid in a cat, possibly combined with exfoliated cells, mucous and/or small blood clots. Both sterile inflammation as well as urinary tract infection can also present with echogenic debris. No masses or definitive cystoliths are observed. The trigone and visible pelvic urethra are normal in thickness with a smooth mucosal surface.

The right kidney is normal in size (3.95 cm), shape and echogenicity. It has smooth peripheral margination. There is a normal 1:3 cortex to medulla ratio with appropriate corticomedullary distinction. There is no evidence of pyelectasia, mineral or infarcts observed.

The left kidney is normal in size (3.62 cm), shape and echogenicity. It has smooth peripheral margination. There is a normal 1:3 cortex to medulla ratio with appropriate corticomedullary distinction. There is no evidence of pyelectasia, mineral or infarcts observed.

Adrenal Glands

The right adrenal gland is normal in size (0.53 cm at cranial pole and 0.61 cm at caudal pole), shape and overall architecture, echogenicity and echotexture. Visible surrounding vasculature appears normal.

The left adrenal gland is normal in size (0.33 cm at cranial pole and 0.16 cm at caudal pole), shape and overall architecture, echogenicity and echotexture. Visible surrounding vasculature appears normal.

Spleen

The spleen is subjectively normal in size with a normal smooth capsular contour. Parenchyma is appropriately finely textured and homogenous with normal echogenicity relative to surrounding tissue (hyperechoic to liver). No focal nodules or masses are observed. Splenic vasculature appears normal.

Liver

The liver is subjectively normal in size with normal smooth curvilinear peripheral contour. Parenchyma is appropriately hypoechoic to the spleen in echogenicity and appropriately mildly coarse and homogenous in echotexture. No focal lesions are observed. Visible vasculature and biliary tree appear normal without distension or congestion.

The gallbladder is non-distended in size. The wall is smooth without visible thickening. Luminal contents are primarily anechoic. The cystic and common bile duct, while not visibly pathologically distended, are diffusely tortuous in appearance. This is likely a normal patient variant but should be interpreted in combination with laboratory changes, clinical signs, etc.



PATIENT

Mincha George

SPECIES

Feline

BREED

Bengal

SEX

Spayed Female

AGE

5 Years

WEIGHT

9 lbs

INTERPRETED BY

Beth Johnson, DVM
DACVIM

IMAGING PERFORMED BY

Julia Bakker, DVM

HOSPITAL NAME

Orange Blossom
Veterinary Imaging

REFERRING VET

Richard Hall, DVM

INVOICE

73380

DATE

3/4/26

Gastrointestinal

The visible stomach wall is normal in thickness and layering. The lumen of the stomach is empty with no evidence of obstruction, foreign material or infiltrative disease. Pyloric outflow tract appears patent.

The visible small intestines are normal in wall thickness and layering. Small intestinal motility appears adequate (1-3 contractions per min). The lumen of the small intestine is empty with no evidence of obstruction, foreign material or infiltrative disease.

The visible colon is normal in wall thickness (< 0.2 cm) and layering. Contents are consistent with normal formed feces and gas.

Pancreas

The pancreas that is observed appears appropriately isoechoic to surrounding omental fat. Visible capsule is smooth and normal in contour. Visible pancreatic parenchyma is homogenous and unremarkable. There is no visible pancreatic duct dilation. There is no evidence of active peripancreatic inflammation.

Free Abdomen

There is no visible free peritoneal effusion noted in these images.

There is no apparent pathologic lymphadenopathy noted in these images.

ULTRASONOGRAPHIC FINDINGS

- Very mild amount of echogenic urinary bladder debris.
- Otherwise, this is a largely unremarkable/structurally normal abdomen.

INTERPRETATION OF THE FINDINGS & FURTHER RECOMMENDATIONS

As is reportedly already planned, a urine culture is recommended.

Pending results of above, in the face of negative urine culture(s) and no cystoliths, masses, etc., these urinary signs could be, at least in part, consistent with sterile cystitis or feline lower urinary tract disease (FLUTD).

Recommendations include maximizing water consumption (water fountains, canned food, etc) as well as reducing stress (recommendations can be found at Indoor Cat Initiative out of The Ohio State University CVM). Transition to a urinary health diet such as Royal Canin Urinary SO (or similar) could also be considered.



PATIENT

Mincha George

SPECIES

Feline

BREED

Bengal

SEX

Spayed Female

AGE

5 Years

WEIGHT

9 lbs

INTERPRETED BY

Beth Johnson, DVM
DACVIM

IMAGING PERFORMED BY

Julia Bakker, DVM

HOSPITAL NAME

Orange Blossom
Veterinary Imaging

REFERRING VET

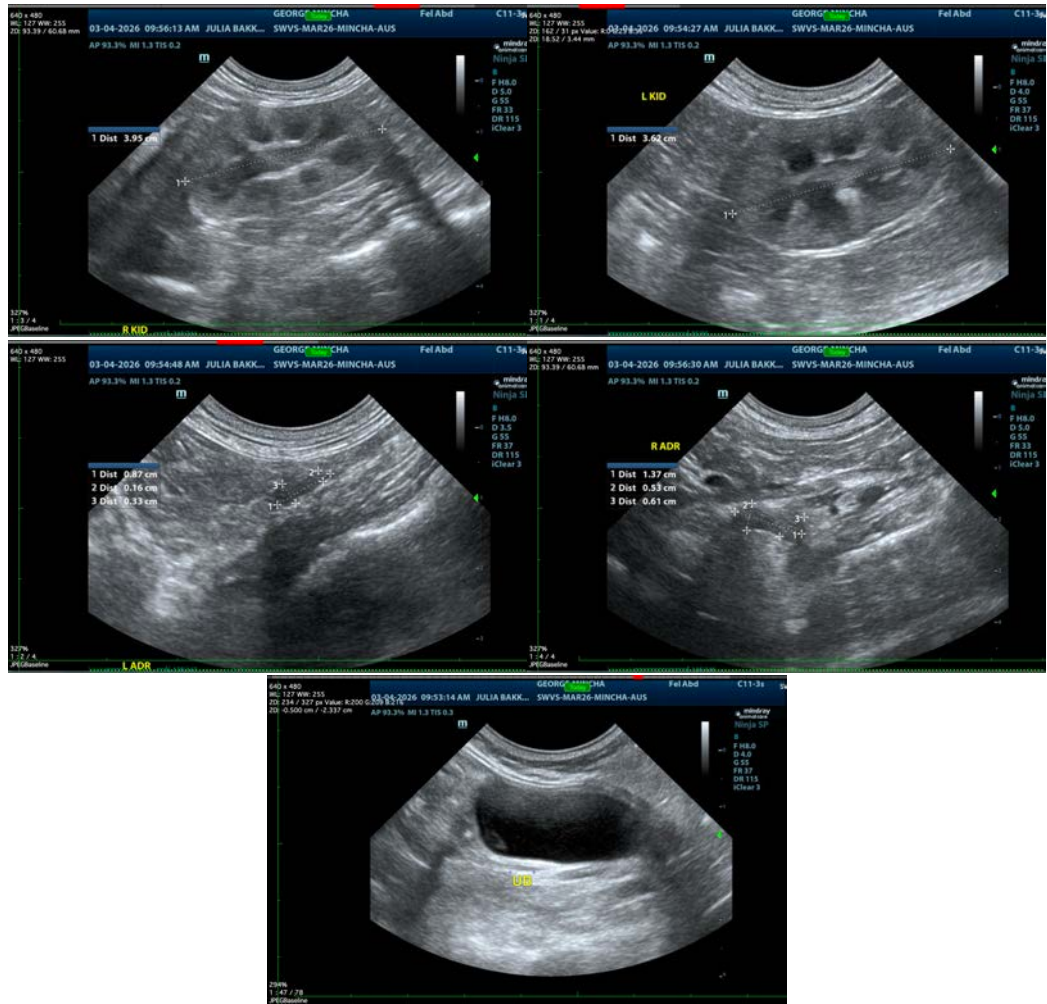
Richard Hall, DVM

INVOICE

73380

DATE

3/4/26



The information and recommendations provided are based on the images presented by the referring veterinarian/sonographer. No evaluation can be communicated regarding pathology that was not visible in the image/video clips provided.

Thank you for this referral. If the clinical or image interpretation does not parallel your findings or if I can be of any further assistance please contact me.

Beth Johnson, DVM, DACVIM
info@sonopath.com