



**PATIENT**

Anson Purrfect  
Companions Rescue

**SPECIES**

Feline

**BREED**

DSH

**SEX**

Neutered Male

**AGE**

~7 Years

**WEIGHT**

3.4 kg

**INTERPRETED BY**

Beth Johnson, DVM  
DACVIM

**IMAGING PERFORMED BY**

Crystal Hill

**HOSPITAL NAME**

Queensway Veterinary  
Hospital

**REFERRING VET**

Dr. Mindy

**INVOICE**

73396

**DATE**

3/4/26

**PRESENTING CLINICAL SIGNS**

Needs sedation due to temperament for exam - minimal information and no previous history. Presented for ongoing vomiting. Has been on Doxycycline. Was sedated today for US.

**ULTRASONOGRAPHIC EXAMINATION OF THE ABDOMEN**

**Urinary System**

Urinary bladder is only mildly distended (empty). Visible contents are anechoic. Urinary bladder wall is unable to be fully assessed for pathology without further distension. No visible masses or definitive cystoliths are observed. The trigone and visible pelvic urethra are normal thickness with a smooth mucosal surface. In the face of urinary signs and/or suspected urinary bladder pathology, reassessment after complete filling is recommended.

The right kidney is normal is size (3.54 cm), shape and echogenicity. It has smooth peripheral margination. There is a normal 1:3 cortex to medulla ratio with appropriate corticomedullary distinction. There is no evidence of pyelectasia, mineral or infarcts observed.

The left kidney is normal is size (3.21 cm), shape and echogenicity. It has smooth peripheral margination. There is a normal 1:3 cortex to medulla ratio with appropriate corticomedullary distinction. There is no evidence of pyelectasia, mineral or infarcts observed.

**Adrenal Glands**

The right adrenal gland is normal in size (0.43 cm), shape and overall architecture, echogenicity and echotexture. Visible surrounding vasculature appears normal.

The left adrenal gland is normal in size (0.31 cm), shape and overall architecture, echogenicity and echotexture. Visible surrounding vasculature appears normal.

**Spleen**

The spleen is subjectively normal in size with a normal smooth capsular contour. Parenchyma is appropriately finely textured and homogenous with normal echogenicity relative to surrounding tissue (hyperechoic to liver). No focal nodules or masses are observed. Splenic vasculature appears normal.

**Liver**

Liver is subjectively enlarged with mildly irregular margins. Parenchyma is mildly heterogenous characterized by multiple poorly defined hypoechoic nodules within otherwise hyperechoic liver parenchyma. Visible vasculature and biliary tree appear normal without distension or congestion.

The gallbladder is non-distended in size. The wall is smooth without visible thickening. Luminal contents are primarily anechoic. The cystic and common bile duct are diffusely tortuous in appearance and appear mildly dilated clear to what is visible adjacent to the duodenal papilla.

**Gastrointestinal**

The visible stomach wall is normal in thickness and layering. The lumen of the stomach is empty with no evidence of obstruction, foreign material or infiltrative disease. Pyloric outflow tract appears patent.



**PATIENT**

Anson Purrfect  
 Companions Rescue

**SPECIES**

Feline

**BREED**

DSH

**SEX**

Neutered Male

**AGE**

~7 Years

**WEIGHT**

3.4 kg

**INTERPRETED BY**

Beth Johnson, DVM  
 DACVIM

**IMAGING PERFORMED BY**

Crystal Hill

**HOSPITAL NAME**

Queensway Veterinary  
 Hospital

**REFERRING VET**

Dr. Mindy

**INVOICE**

73396

**DATE**

3/4/26

The visible small intestine demonstrates areas of markedly thick muscularis layer relative to mucosa (disruption of the normal 1:3 muscularis:mucosa ratio). Small intestinal submucosa is slightly irregular, thick and hyperechoic, without evident loss of layering appreciated. The lumen of the small intestine is empty with no evidence of obstruction or foreign material.

The visible colon is normal in wall thickness (< 0.2 cm) and layering. Contents are consistent with normal formed feces and gas.

***Pancreas***

Pancreas is prominent (enlarged) in size, hypoechoic to surrounding tissue and has a mildly irregular undulating contour. Parenchyma is coarse with mixed echogenic remodeling noted. No pancreatic duct dilation is noted.

***Free Abdomen***

There is no visible free peritoneal effusion noted in these images.

Mesenteric lymph nodes are prominent in size with swollen capsular contour. Normal elongated shape (length to width ratio) is maintained. There is no loss of parenchymal detail.

**ULTRASONOGRAPHIC FINDINGS**

- Marked/significant inflammatory bowel disease (IBD) pattern – Thick muscularis has been reported with infiltrative bowel disease including both benign inflammatory disease as well as infiltrative neoplasia such as lymphoma. No loss of layering or distinct characteristics of malignancy are present. Therefore, differentials cannot be further ranked without tissue sampling.
- Concurrent chronic low-grade smoldering pancreatitis +/- cholangitis/“Triaditis” can’t be ruled out and should be suspected in the face of appropriate clinical signs, laboratory changes, etc.
- Moderately reactive mesenteric lymph nodes – infiltrative neoplastic disease cannot be ruled out but is considered less likely.

**INTERPRETATION OF THE FINDINGS & FURTHER RECOMMENDATIONS**

If not recently evaluated, a general metabolic health screen (CBC, chemistry panel with electrolytes and urinalysis) is recommended.

A gastrointestinal malabsorption panel (including cobalamin, folate, TLI and PLI) to Texas A&M GI Laboratory is recommended for further evaluation of GI and pancreatic function.

Ideally, biopsies of the GI tract, being sure to include ileum if possible, are recommended to definitively diagnose and therefore manage the infiltrative bowel disease.

If biopsies cannot be obtained, empirical therapies could include a probiotic (if diarrhea is present, such as visbiome or proviable), empirical deworming with a 5-day course of Panacur and, if tolerated, a transition in diet, based on trial-and-error response, beginning with a hydrolyzed protein diet. Some patients respond to one brand/version of a hydrolyzed protein diet better than another brand, so several trials may be required.



**PATIENT**

Anson Purrfect  
Companions Rescue

**SPECIES**

Feline

**BREED**

DSH

**SEX**

Neutered Male

**AGE**

~7 Years

**WEIGHT**

3.4 kg

**INTERPRETED BY**

Beth Johnson, DVM  
DACVIM

**IMAGING PERFORMED BY**

Crystal Hill

**HOSPITAL NAME**

Queensway Veterinary  
Hospital

**REFERRING VET**

Dr. Mindy

**INVOICE**

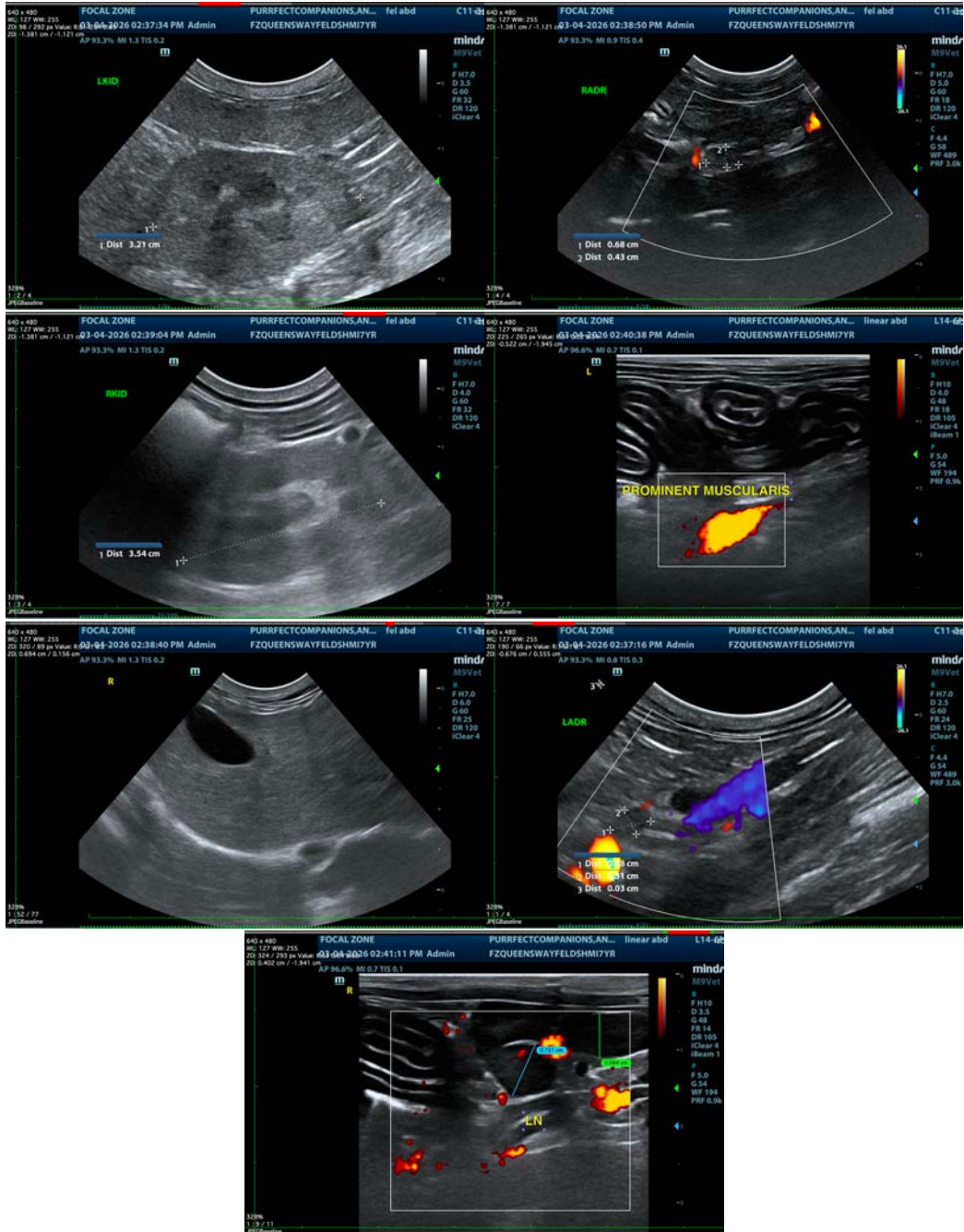
73396

**DATE**

3/4/26

Additional considerations could include cobalamin supplementation (unless cobalamin level is evaluated and supplementation is not warranted) and prednisolone (if not contraindicated based on patient contraindications, co-morbidities, etc.).

Additionally, I'm uncertain as to why patient is receiving Doxycycline, but if the timing is appropriate, that too could result in nausea or ongoing vomiting, and if possible, discontinuation or transition to an alternative therapy could be considered.





**PATIENT**

Anson Purrfect  
Companions Rescue

**SPECIES**

Feline

**BREED**

DSH

**SEX**

Neutered Male

**AGE**

~7 Years

**WEIGHT**

3.4 kg

**INTERPRETED BY**

Beth Johnson, DVM  
DACVIM

**IMAGING  
PERFORMED BY**

Crystal Hill

**HOSPITAL NAME**

Queensway Veterinary  
Hospital

**REFERRING VET**

Dr. Mindy

**INVOICE**

73396

**DATE**

3/4/26

**The information and recommendations provided are based on the images presented by the referring veterinarian/sonographer. No evaluation can be communicated regarding pathology that was not visible in the image/video clips provided.**

Thank you for this referral. If the clinical or image interpretation does not parallel your findings or if I can be of any further assistance please contact me.

**Beth Johnson, DVM, DACVIM**  
[info@sonopath.com](mailto:info@sonopath.com)