



PATIENT

Daisy Minnick

SPECIES

Canine

BREED

Terrier x

SEX

Spayed Female

AGE

11.11 Years

WEIGHT

67.4 lbs

INTERPRETED BY

Beth Johnson, DVM
DACVIM

IMAGING PERFORMED BY

Dr. Kristen Carpenter

HOSPITAL NAME

Pennridge Animal
Hospital

REFERRING VET

Dr. Kristen Carpenter

INVOICE

74101

DATE

3/31/26

PRESENTING CLINICAL SIGNS

Hx: Patient was sedated with Butorphanol. Hx of chronic progressive ALP elevation and new ALT elevation. Hx of weight gain, PU/PD/PP, panting. Hx of atopy, osteoarthritis, and recurrent UTI. Here for AUS to investigate for cause of clinical signs/liver enzyme elevation and to image adrenals/consider LDDST as next step. Chronic meds: Apoquel 16 mg PO SID, Dasuquin, Salmon oil, Cytopoint PRN. No topical or oral steroids since 2023. No NSAID use for > 1 year.

Abnormal PE/Chem/CBC/UA Results: Bloodwork 3/9/26: HCT 64% (37-61%), platelets normal. Chem: NSF except ALT 291 (10-125), ALP > 2000 (23-212) UA 3/31/26: USG 1.029, 1+ protein, WBC > 50/HPF, TNTC rods.

ULTRASONOGRAPHIC EXAMINATION OF THE ABDOMEN

Urinary System

Urinary bladder is adequately distended. It has a normal uniform wall thickness. Contents include primarily anechoic fluid with a large amount of echogenic non-shadowing debris, most consistent with exfoliated cells, mucous and/or small blood clots. Both sterile inflammation as well as urinary tract infection can present with echogenic debris. No masses or cystoliths are observed. The trigone and visible pelvic urethra are normal in thickness with a smooth mucosal surface.

The right kidney is normal is size (7.03 cm), shape and echogenicity. It has smooth peripheral margination. There is a normal 1:3 cortex to medulla ratio with appropriate corticomedullary distinction. There is no evidence of pyelectasia, mineral or infarcts observed. A hyperechoic band parallel to the corticomedullary border is present.

The left kidney is normal is size (6.45 cm), shape and echogenicity. It has smooth peripheral margination. There is a normal 1:3 cortex to medulla ratio with appropriate corticomedullary distinction. There is no evidence of pyelectasia, mineral or infarcts observed. A hyperechoic band parallel to the corticomedullary border is present.

Adrenal Glands

The right adrenal gland is normal in size (0.65 cm at cranial pole and 0.64 cm at caudal pole), shape and overall architecture, echogenicity and echotexture. Visible surrounding vasculature appears normal.

The left adrenal gland is normal in size (0.69 cm at cranial pole and 0.68 cm at caudal pole), shape and overall architecture, echogenicity and echotexture. Visible surrounding vasculature appears normal.

Spleen

The spleen is subjectively normal in size with a normal smooth capsular contour. Parenchyma is appropriately finely textured and homogenous with normal echogenicity relative to surrounding tissue (hyperechoic to liver). No focal nodules or masses are observed. Splenic vasculature appears normal.

Liver

Liver is subjectively enlarged with mildly irregular margins. Parenchyma is moderately heterogenous characterized by multiple poorly defined hypoechoic nodules within otherwise hyperechoic liver parenchyma. Visible vasculature and biliary tree appear normal without distension or congestion



PATIENT

Daisy Minnick

Gallbladder is moderately distended with anechoic bile as well as suspended and gravity dependent echogenic debris. The wall is smooth without visible thickening. There is no evidence of cystic or CBD dilation. There is no evidence of effusion or inflammation.

SPECIES

Canine

Gastrointestinal

The visible stomach wall is normal in thickness and layering. The lumen of the stomach is empty with no evidence of obstruction, foreign material or infiltrative disease. Pyloric outflow tract appears patent.

BREED

Terrier x

The visible small intestine demonstrates areas of mildly thick muscularis layer relative to mucosa (disruption of the normal 1:3 muscularis:mucosa ratio). Small intestinal submucosa is slightly irregular, thick and hyperechoic, without evident loss of layering appreciated. The lumen of the small intestine is empty with no evidence of obstruction or foreign material.

SEX

Spayed Female

The visible colon is normal in wall thickness (< 0.2 cm) and layering. Contents are consistent with normal formed feces and gas.

AGE

11.11 Years

Pancreas

The pancreas that is observed appears appropriately isoechoic to surrounding omental fat. Visible capsule is smooth and normal in contour. Visible pancreatic parenchyma is homogenous and unremarkable. There is no visible pancreatic duct dilation. There is no evidence of active peripancreatic inflammation.

WEIGHT

67.4 lbs

Free Abdomen

There is no visible free peritoneal effusion noted in these images.

INTERPRETED BY

Beth Johnson, DVM
DACVIM

Medial iliac lymph nodes are prominent in size with swollen capsular contour. Normal elongated shape (length to width ratio) is maintained. There is no loss of parenchymal detail.

IMAGING PERFORMED BY

Dr. Kristen Carpenter

ULTRASONOGRAPHIC FINDINGS

- Moderately heterogenous liver – These changes are most consistent with benign processes such as nodular hyperplasia, steroid (vacuolar) hepatopathy, extramedullary hematopoiesis or possibly chronic inflammatory disease and less commonly infiltrative round cell or metastatic neoplasia.
- Moderate gallbladder debris - Cholecystic debris is of unknown clinical significance. It can be seen with biliary stasis from fasting or illness. Cholecystic debris is not necessarily related to hepatobiliary disease. Echogenic bile is most commonly an incidental finding in dogs and should be interpreted in combination with clinical signs such as nausea, inappetence, cranial abdominal discomfort and/or laboratory changes such as increased ALP and/or increased Tbili.
- Mild/emerging inflammatory bowel disease (IBD) pattern – Thick muscularis has been reported with infiltrative bowel disease including both benign inflammatory disease as well as infiltrative neoplasia such as lymphoma. No loss of layering or distinct characteristics of malignancy are present. Therefore, differentials cannot be further ranked without tissue sampling.
- Mild reactive medial iliac lymph nodes – infiltrative neoplastic disease cannot be ruled out but is considered less likely.

HOSPITAL NAME

Pennridge Animal
Hospital

REFERRING VET

Dr. Kristen Carpenter

INVOICE

74101

DATE

3/31/26



PATIENT

Daisy Minnick

SPECIES

Canine

BREED

Terrier x

SEX

Spayed Female

AGE

11.11 Years

WEIGHT

67.4 lbs

INTERPRETED BY

Beth Johnson, DVM
DACVIM

IMAGING PERFORMED BY

Dr. Kristen Carpenter

HOSPITAL NAME

Pennridge Animal Hospital

REFERRING VET

Dr. Kristen Carpenter

INVOICE

74101

DATE

3/31/26

- Very large amount of echogenic urinary bladder debris.
- Moderate bilateral medullary rim sign - This finding is of unknown clinical significance and can be a normal variant, often idiopathic. Medullary rim sign can be present with renal disease including lymphoma, hypercalcemic nephropathy, Leptospirosis, tubular disease, other and should be interpreted in combination with other more specific indications of kidney disease such as isosthenuria, proteinuria, azotemia, etc. This is a common incidental finding in patients with diabetes mellitus.

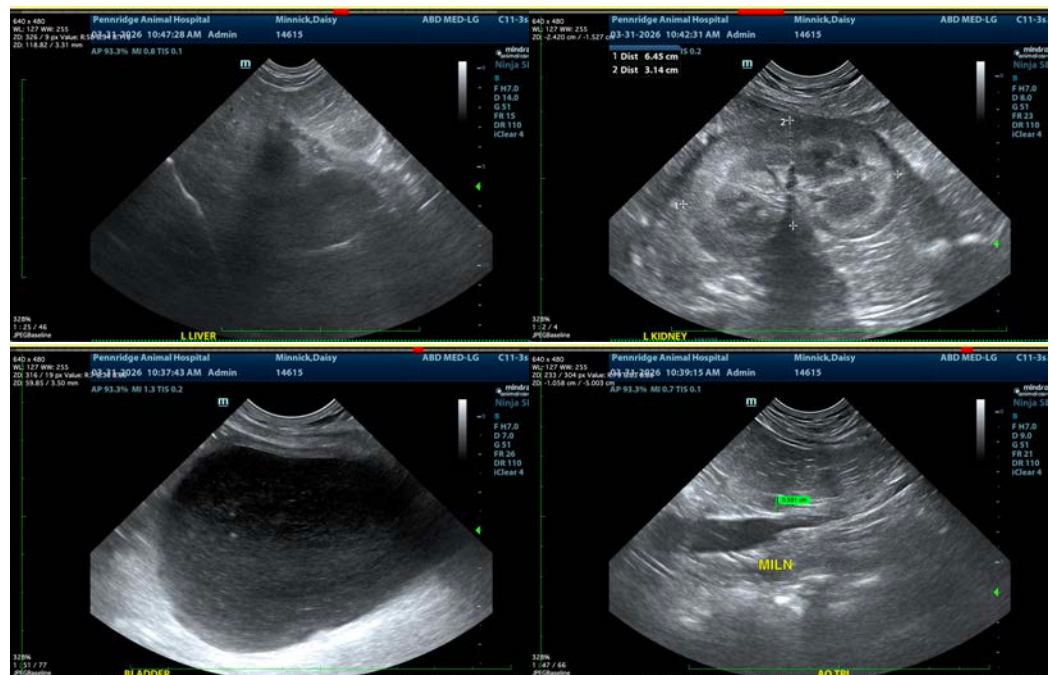
INTERPRETATION OF THE FINDINGS & FURTHER RECOMMENDATIONS

If not already evaluated, a urine culture followed by treatment of a suspected urinary tract infection based on culture and sensitivity results is recommended. Given the reported chronicity of urinary tract infections, a follow up culture a week to 10 days after finishing antibiotics is advised to be sure that the infection has fully cleared.

A blood pressure is recommended if not recently evaluated.

Given patient's clinical history, if another cause for the clinical signs is not diagnosed, normal appearing adrenal glands does not rule out hyperadrenocorticism as a possible differential, and hormone testing could be considered, beginning with a low-dose Dexamethasone suppression test. In the meantime, further evaluation/workup of the subtle bowel changes should be considered if any gastrointestinal clinical history warrants further investigation.

Finally, while the appearance of the liver trends largely toward benign, fine needle aspirates could be considered if patient's coagulation status is appropriate.





PATIENT

Daisy Minnick

SPECIES

Canine

BREED

Terrier x

SEX

Spayed Female

AGE

11.11 Years

WEIGHT

67.4 lbs

INTERPRETED BY

Beth Johnson, DVM
DACVIM

IMAGING PERFORMED BY

Dr. Kristen Carpenter

HOSPITAL NAME

Pennridge Animal Hospital

REFERRING VET

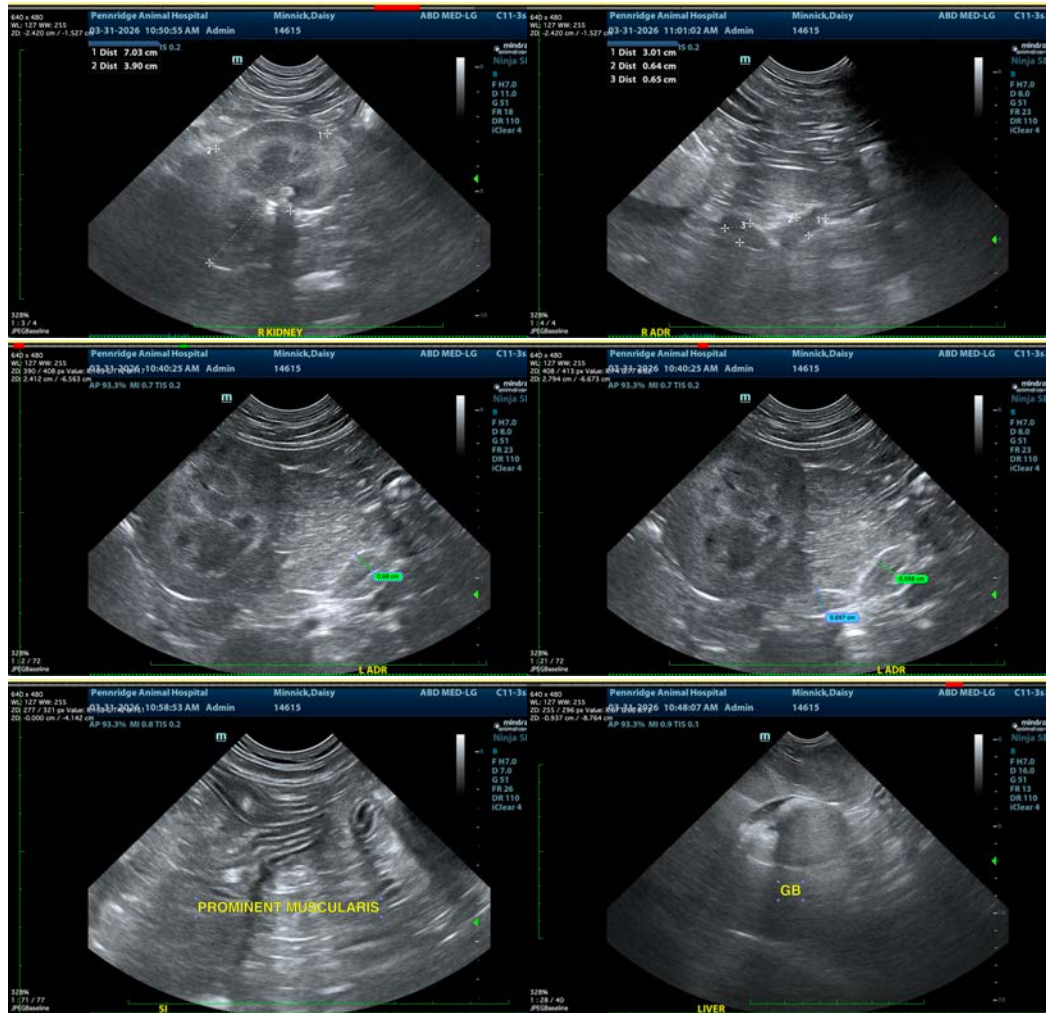
Dr. Kristen Carpenter

INVOICE

74101

DATE

3/31/26



The information and recommendations provided are based on the images presented by the referring veterinarian/sonographer. No evaluation can be communicated regarding pathology that was not visible in the image/video clips provided.

Thank you for this referral. If the clinical or image interpretation does not parallel your findings or if I can be of any further assistance please contact me.

Beth Johnson, DVM, DACVIM
info@sonopath.com