

**DATE PRESENTING CLINICAL SIGNS**

3/31/22 In for WVX. Labs showed elevated Alk Phos, GGT, Amylase, Lipase and BUN.

**PATIENT** Current Medications: Heartgard. Owner to give Gabapentin 100mg- 2 PO 1hr prior to arrival, Trazodone 100mg- ½ PO 1hr prior to arrival.

Oliver Rierson Lab Results: See attached.

Date of Previous IntraPet Ultrasound: No previous.

**SPECIES** Sedation: Not required to complete full diagnostic ultrasound.

Stat Report: Not requested.

Canine

**ULTRASONOGRAPHIC EXAMINATION OF THE ABDOMEN**

**BREED** *Urinary System*

Boston Terrier

The urinary bladder is moderately distended with anechoic contents. No masses, inflammatory changes, echogenic sediment or cystoliths are observed. The urinary bladder, trigone and visible pelvic urethra are normal in thickness with a smooth mucosal surface.

**SEX**

Neutered Male

The right kidney is normal in size (5.25 cm) and shape with smooth peripheral margination. A normal 1:3 cortex to medulla ratio is maintained. The medulla and cortices are uniform in texture with some mild increased echogenicity and mild loss of corticomedullary distinction. There is no evidence of pyelectasia, mineral or infarcts observed. Cortical cysts noted.

**AGE**

8/18/09

The left kidney is normal in size (5.52 cm) and shape with smooth peripheral margination. A normal 1:3 cortex to medulla ratio is maintained. The medulla and cortices are uniform in texture with some mild increased echogenicity and mild loss of corticomedullary distinction. There is no evidence of pyelectasia, mineral or infarcts observed. Cortical cysts noted. The largest cyst measures approximately 2.0 cm.

**WEIGHT**

22.6 Pounds

**INTERPRETED BY**

Prostate (neutered) is normal in size, echotexture and echogenicity for a neutered male.

Beth Johnson, DVM  
DACVIM

**Adrenal Glands**

The left adrenal gland is pump (2.12 cm long x 0.74 cm at the cranial pole and 0.52 cm at the caudal pole). Normal shape and contour are maintained. Corticomedullary structure is unremarkable. Visible surrounding vasculature appears normal.

**IMAGING PERFORMED BY**

Stephanie Pearce  
RDACS, RVT

The right adrenal gland is plump (2.09 cm long x 0.64 cm at the cranial pole and 0.71 cm at the caudal pole). Normal shape and contour are maintained. Corticomedullary structure is unremarkable. Visible surrounding vasculature appears normal.

**HOSPITAL NAME**

Festival Vet Clinic

**Spleen**

The spleen is subjectively normal in size with a normal smooth capsular contour. Parenchyma is appropriately finely textured and homogenous with normal echogenicity relative to surrounding tissue (hyperechoic to liver). No focal nodules or masses are observed. Splenic vasculature appears normal.

**REFERRING VET**

Dr. Ullman

**Liver**

Liver is subjectively enlarged. Margins are smooth but round. It has a normal homogenous echotexture. Parenchyma is diffusely hyperechoic characterized by less prominent than normal portal vein walls and increased echogenicity relative to the spleen. A 3.5 cm x 2.5 cm mixed, primarily hypoechoic mass is noted in the left liver. Visible vasculature and biliary tree appear normal without distension or congestion.

**INVOICE**

36643

GB is moderately distended with anechoic bile and gravity dependent echogenic sediment. The wall is smooth without visible thickening. There is no evidence of cystic or CBD dilation. There is no evidence of effusion or inflammation.

### ***Gastrointestinal***

The stomach wall is normal in thickness (canine < 0.5 cm and feline < 0.4 cm) and layering. The lumen of the stomach is mildly distended with very echogenic reverberation artifact from intraluminal gas. There is no evidence of obstruction, foreign material or infiltrative disease; however, complete visualization of far wall is partially inhibited by gas. Pyloric outflow tract appears patent.

The visible small intestines are normal in wall thickness and layering (canine duodenum < 0.5 cm and feline duodenum < 0.4 cm; other < 0.3 cm). Small intestinal motility appears adequate (1-3 contractions per min). The lumen of the small intestine is empty with no evidence of obstruction, foreign material or infiltrative disease. Multifocal hyperechoic mucosal speckling is noted throughout the duodenum.

The visible colon is normal in wall thickness (< 0.2 cm) and layering. Contents are consistent with normal formed feces and gas.

### ***Pancreas***

The pancreas, primarily the right limb, is prominent in size and mildly irregular in shape with a diffusely coarse echotexture and heterogeneous to hyperechoic echogenicity.

### ***Free Abdomen***

There is no evidence of peritoneal effusion. There is no apparent lymphadenopathy.

## **PRIMARY FINDINGS**

- Bilateral adrenomegaly – consistent with adrenal hyperplasia secondary to pituitary depending hyperadrenocorticism vs normal variant.
- Hyperechoic hepatomegaly– most consistent with benign steroid (endocrine) hepatopathy or reactive or idiopathic hepatopathy. Infiltrative neoplasia such as round cell neoplasia is also possible, but considered less likely.
- Mixed echogenic liver mass – Differentials include well differentiated infiltrative neoplasia such as hepatocellular carcinoma versus nodular regeneration (considered less likely but can't be ruled out).

## **SECONDARY FINDINGS**

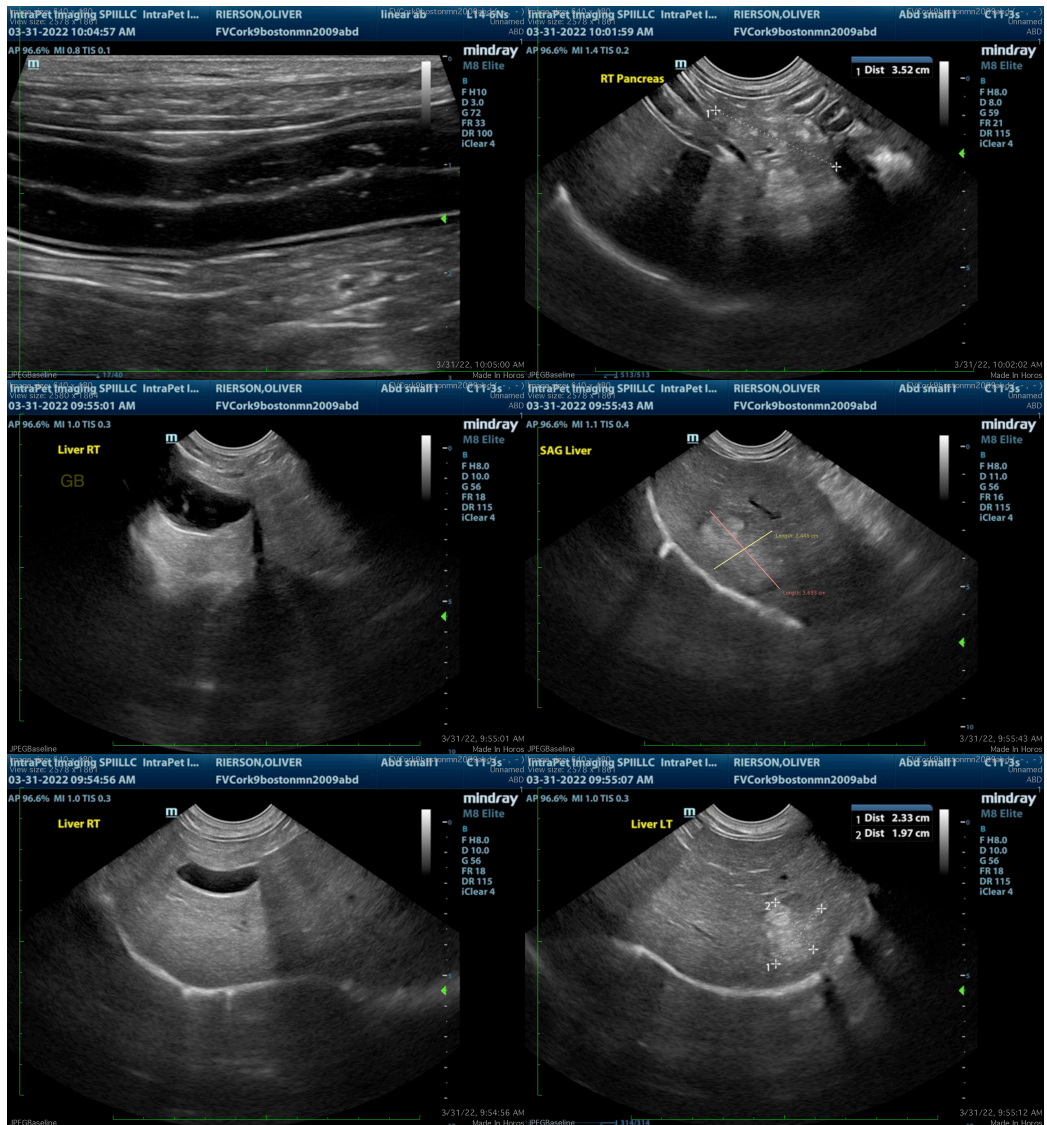
- Gallbladder debris - Cholecystic debris is of unknown clinical significance. It can be seen with biliary stasis from fasting or illness. Cholecystic debris is not necessarily related to hepatobiliary disease. Echogenic bile is most commonly an incidental finding in dogs and should be interpreted in combination with clinical signs such as nausea, inappetence, cranial abdominal discomfort and/or laboratory changes such as increased ALP and/or increased Tbili.
- Age related kidney change – This finding is expected/consistent with age-related mild degenerative disease and should be interpreted clinically in combination with laboratory changes.
- Bilateral renal cortical cysts
- Chronic pancreatitis
- Incidental mucosal speckling of the small bowel – This can be present with inflammatory bowel disease, but is not specific for the type or severity of disease and is considered an incidental finding with the lack of gastrointestinal signs such as diarrhea and/or weight loss.

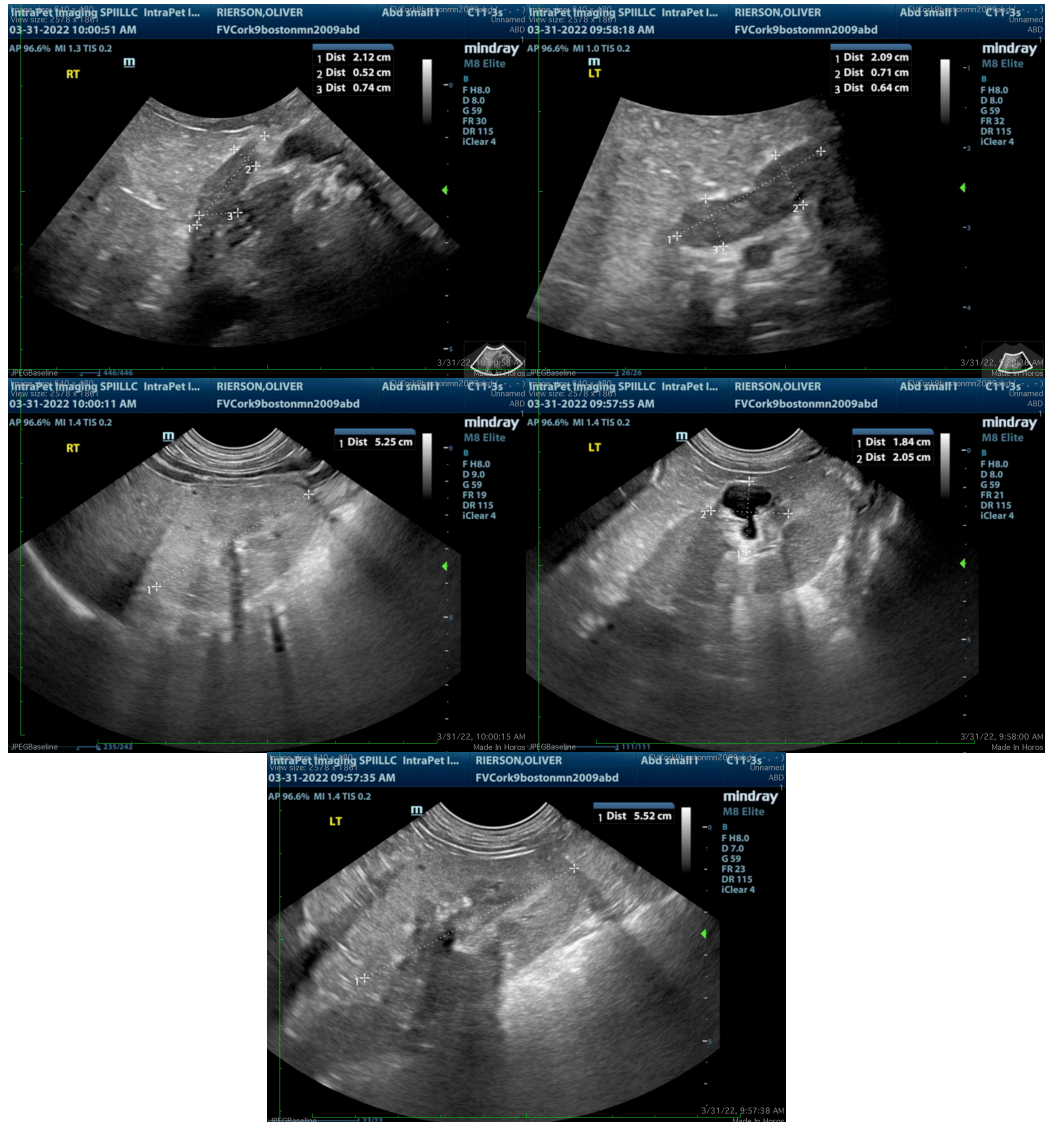
## INTERPRETATION OF THE FINDINGS & FURTHER RECOMMENDATIONS

The liver mass is considered a likely incidental finding and not the reason for this patient's cholestatic bloodwork, given the focal nature of the lesion. However, a fine needle aspirate of the mass is recommended if patient's coagulation status is appropriate. 3-view thoracic radiographs are also recommended for further evaluation of possible metastatic disease is not recently performed.

Given the bowel and pancreatic changes, a gastrointestinal malabsorption panel including TLI, PLI, folate and cobalamin to Texas A&M GI laboratory is recommended for further assessment of the GI tract and pancreas. If there are clinical signs of hyperadrenocorticism present such as polyuria, polydipsia, polyphagia, etc., testing for hyperadrenocorticism in the form of a low-dose Dexamethasone suppression test is considered reasonable, given the plump adrenal glands and the historically increased ALP.

In the meantime, empirical management could include broad-spectrum antibiotics, Ursodiol, and potentially a low-fat diet.





The information and recommendations provided are based on the images presented by the referring veterinarian/sonographer. No evaluation can be communicated regarding pathology that was not visible in the image/video clips provided.

Thank you for this referral. If the clinical or image interpretation does not parallel your findings or if I can be of any further assistance please contact me.

**Beth Johnson, DVM, DACVIM**  
Beth.Johnson@sonopath.com