



**PATIENT**

Gort Walkingshaw

**SPECIES**

Feline

**BREED**

DSH

**SEX**

Neutered Male

**AGE**

15 Years

**WEIGHT**

10.6 Pounds

**INTERPRETED BY**

Beth Johnson, DVM  
DACVIM

**IMAGING PERFORMED BY**

Jessica Bailes

**HOSPITAL NAME**

All Creatures Great &  
Small Corvallis

**REFERRING VET**

Dr. Justin Vaughn

**INVOICE**

36638

**DATE**

3/31/22

**PRESENTING CLINICAL SIGNS**

Hx of hyperthyroidism - clinically well regulated TT4 WNL @ 0.9 but progressive weight loss, poor appetite noted. No hx of vomiting or diarrhea.

Abnormal PE/Chem/CBC/UA Results: NSF on PE other than minor progressive weight loss. Bloodwork/UA: SC: Alb 4.9. Creat 2.2. All other wnl. CBC: wnl. UA: USG 1.045. IS. Thoracic rads ( 3 view): NSF - lungs clear/heart WNL.

**ULTRASONOGRAPHIC EXAMINATION OF THE ABDOMEN**

**Urinary System**

Urinary bladder is moderately distended. It has a normal uniform wall thickness (<0.2 cm). Contents include primarily anechoic fluid combined with suspended echogenic non-shadowing debris within the fluid. No masses or cystoliths are observed. The trigone and visible pelvic urethra are normal in thickness with a smooth mucosal surface.

The right kidney is normal in size (3.70 cm) and shape with smooth peripheral margination. A normal 1:3 cortex to medulla ratio is maintained. The medulla and cortices are uniform in texture with some mild increased echogenicity and mild loss of corticomedullary distinction. There is no evidence of pyelectasia, mineral or infarcts observed.

The left kidney is normal in size (3.72 cm) and shape with smooth peripheral margination. A normal 1:3 cortex to medulla ratio is maintained. The medulla and cortices are uniform in texture with some mild increased echogenicity and mild loss of corticomedullary distinction. There is no evidence of pyelectasia, mineral or infarcts observed.

**Adrenal Glands**

The right adrenal gland is normal in size (1.03 cm long x 0.26 cm at the cranial pole and 0.25 cm at the caudal pole), shape and contour. Corticomedullary structure is unremarkable. Visible surrounding vasculature appears normal.

The left adrenal gland is normal in size (1.09 cm long x 0.27 cm at the cranial pole and 0.32 cm at the caudal pole), shape and contour. Corticomedullary structure is unremarkable. Visible surrounding vasculature appears normal.

**Spleen**

The spleen is subjectively normal in size with a normal smooth capsular contour. Parenchyma is appropriately finely textured and homogenous with normal echogenicity relative to surrounding tissue (hyperechoic to liver). No focal nodules or masses are observed. Splenic vasculature appears normal.

**Liver**

Liver is subjectively enlarged. Margins are smooth but round. It has a normal homogenous echotexture. Parenchyma is diffusely hyperechoic characterized by less prominent than normal portal vein walls and increased echogenicity relative to the spleen. A small, focal hypoechoic nodule is noted deep in the liver. Visible vasculature and biliary tree appear normal without distension or congestion.

The gallbladder is non-distended in size. The wall is smooth without visible thickening. Luminal contents are primarily anechoic. There is no evidence of cystic or common bile duct dilation.

**Gastrointestinal**

The stomach wall is normal in thickness (canine < 0.5 cm and feline < 0.4 cm) and layering. The lumen of the stomach is mildly distended with very echogenic reverberation artifact from intraluminal gas. There



**PATIENT**

Gort Walkingshaw

is no evidence of obstruction, foreign material or infiltrative disease; however, complete visualization of far wall is partially inhibited by gas. Pyloric outflow tract appears patent.

**SPECIES**

Feline

The visible small intestines are normal in wall thickness. Normal layering is maintained except for a diffusely disproportionately thick muscularis layer relative to mucosa. Small intestinal motility appears adequate (1-3 contractions per min). The lumen of the small intestine is empty with no evidence of obstruction, foreign material or infiltrative disease.

**BREED**

DSH

The visible colon is normal in wall thickness (< 0.2 cm) and layering. Contents are consistent with normal formed feces and gas.

**SEX**

Neutered Male

**Pancreas**

The pancreatic parenchyma is appropriately isoechoic to surrounding tissue. Visible capsule is smooth and normal in contour. There is no visible pancreatic duct dilation. There is no evidence of active peripancreatic inflammation.

**AGE**

15 Years

**Free Abdomen**

There is no evidence of peritoneal effusion. There is no apparent lymphadenopathy.

**WEIGHT**

10.6 Pounds

**PRIMARY FINDINGS**

- Thick muscularis – This finding has been reported in cats with infiltrative bowel disease including both benign inflammatory disease as well as infiltrative neoplasia such as lymphoma.
- Hyperechoic hepatomegaly – consistent with benign hepatic lipidosis. Infiltrative disease such as amyloidosis or neoplasia, such as mast cell tumor or less likely, lymphoma, is also possible.

**INTERPRETED BY**

Beth Johnson, DVM  
DACVIM

**SECONDARY FINDINGS**

- Age related kidney change – This finding is expected/consistent with age-related mild degenerative disease and should be interpreted clinically in combination with laboratory changes.
- Urinary bladder sediment – Urine changes are most consistent with incidental suspended lipid in a cat, however, cellular debris or crystalluria cannot be ruled out and should be interpreted in combination with urinalysis results.

**IMAGING PERFORMED BY**

Jessica Bailes

**INTERPRETATION OF THE FINDINGS & FURTHER RECOMMENDATIONS**

All Creatures Great &  
Small Corvallis

The primary cause of this patient's weight loss, given the changes in this ultrasound, is likely infiltrative small bowel disease +/- concurrent hepatopathy caused by either infiltrative round cell neoplasia or inflammatory bowel disease. Diagnostic recommendations include a gastrointestinal malabsorption panel including TLI, PLI, folate and cobalamin to Texas A&M GI laboratory for further investigation of gastrointestinal function, as well as a fine needle aspirate of the liver if patient's coagulation status is appropriate.

**REFERRING VET**

Dr. Justin Vaughn

**INVOICE**

36638

Ideally, biopsies of the bowel, being sure to include ileum, if possible, would be obtained. However, if biopsies are not an option, empirical therapy with Prednisolone could be considered. Slightly lowering the dose of Methimazole could also be considered with the goal of less tightly managing the hyperthyroidism, which might result in an increased appetite and improvement in kidney health.

**DATE**

3/31/22



**PATIENT**

Gort Walkingshaw

**SPECIES**

Feline

**BREED**

DSH

**SEX**

Neutered Male

**AGE**

15 Years

**WEIGHT**

10.6 Pounds

**INTERPRETED BY**

Beth Johnson, DVM  
DACVIM

**IMAGING PERFORMED BY**

Jessica Bailes

**HOSPITAL NAME**

All Creatures Great & Small Corvallis

**REFERRING VET**

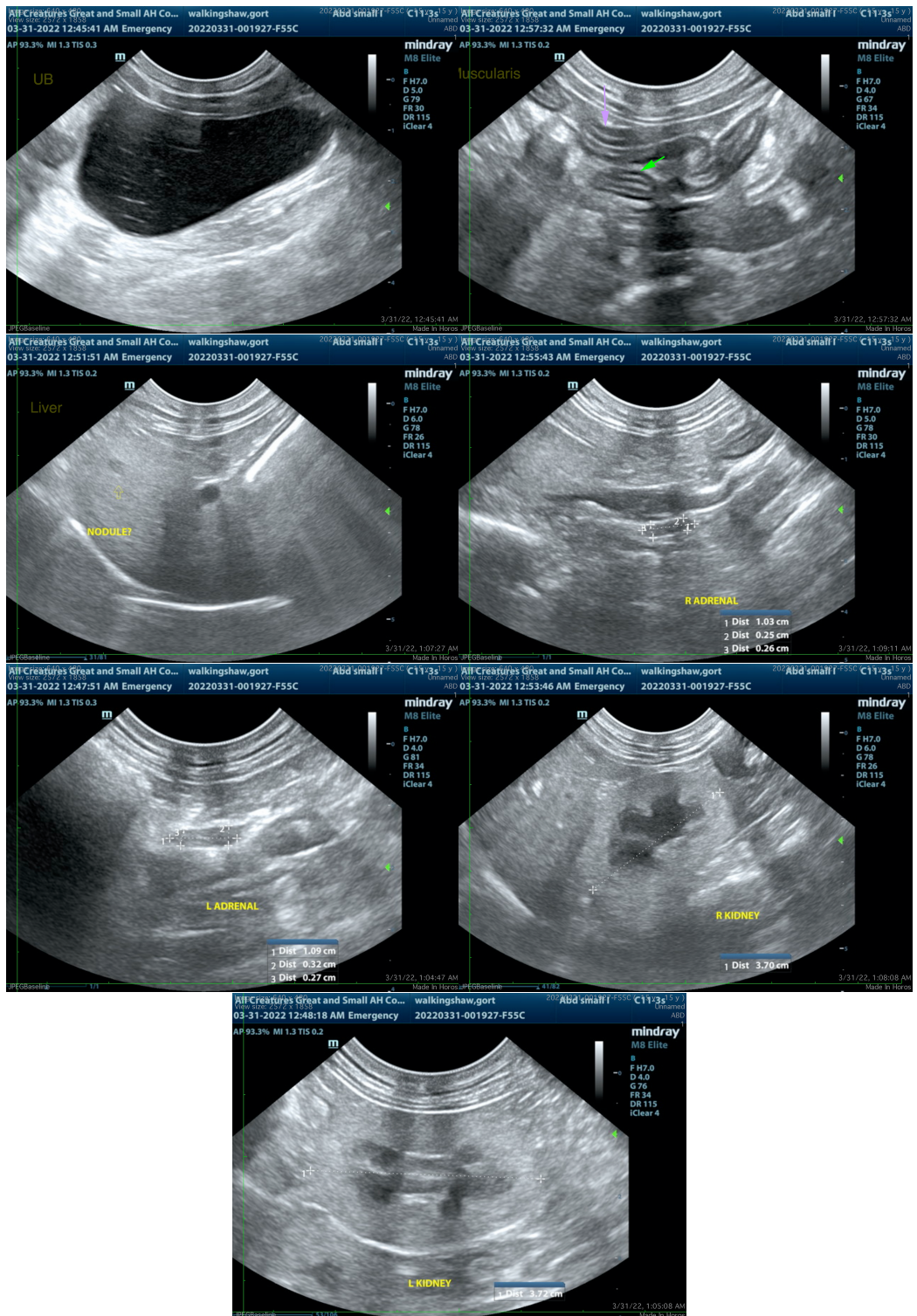
Dr. Justin Vaughn

**INVOICE**

36638

**DATE**

3/31/22





**PATIENT**

Gort Walkingshaw

The information and recommendations provided are based on the images presented by the referring veterinarian/sonographer. No evaluation can be communicated regarding pathology that was not visible in the image/video clips provided.

**SPECIES**

Feline

Thank you for this referral. If the clinical or image interpretation does not parallel your findings or if I can be of any further assistance please contact me.

**Beth Johnson, DVM, DACVIM**

Beth.Johnson@sonopath.com

**BREED**

DSH

**SEX**

Neutered Male

**AGE**

15 Years

**WEIGHT**

10.6 Pounds

**INTERPRETED BY**

Beth Johnson, DVM  
DACVIM

**IMAGING  
PERFORMED BY**

Jessica Bailes

**HOSPITAL NAME**

All Creatures Great &  
Small Corvallis

**REFERRING VET**

Dr. Justin Vaughn

**INVOICE**

36638

**DATE**

3/31/22